

Journal Pre-proof

Pulmonary glomus tumor presenting as a solitary mass in a young female

Binglin Lai MD



PII: S0300-2896(25)00188-7

DOI: <https://doi.org/doi:10.1016/j.arbres.2025.05.012>

Reference: ARBRES 3810

To appear in: *Archivos de Bronconeumología*

Received Date: 9 May 2025

Accepted Date: 14 May 2025

Please cite this article as: Lai B, Pulmonary glomus tumor presenting as a solitary mass in a young female, *Archivos de Bronconeumología* (2025), doi: <https://doi.org/10.1016/j.arbres.2025.05.012>

This is a PDF file of an article that has undergone enhancements after acceptance, such as the addition of a cover page and metadata, and formatting for readability, but it is not yet the definitive version of record. This version will undergo additional copyediting, typesetting and review before it is published in its final form, but we are providing this version to give early visibility of the article. Please note that, during the production process, errors may be discovered which could affect the content, and all legal disclaimers that apply to the journal pertain.

© 2025 Published by Elsevier España, S.L.U. on behalf of SEPAR.

Pulmonary glomus tumor presenting as a solitary mass in a young female

Binglin Lai, MD

Author Affiliation: Ganzhou Institute of Medical Imaging, Ganzhou Key Laboratory of Medical Imaging and Artificial Intelligence, Medical Imaging Center, Ganzhou People's Hospital, Ganzhou Hospital-Nanfeng Hospital, Southern Medical University

Correspondence: Binglin Lai, 16 Meiguan Avenue, Ganzhou, Jiangxi 341000, China. Email:

binglin723.lai@outlook.com

Words:202

A 46-year-old asymptomatic female was referred following incidental detection of a right upper lung mass during routine health screening. Chest CT demonstrated a well-demarcated homogeneous soft-tissue mass (3.6×4.8 cm) in the right upper lobe's anterior segment, devoid of lobulation or spiculation (Fig.1A-C). Laboratory parameters remained within normal limits. Thoracoscopic right upper lobectomy was successfully performed. Histopathological examination revealed characteristic nests of uniform round cells exhibiting clear cytoplasm and delicate chromatin, organized around thin-walled vascular channels within focal myxoid stroma (Fig.1D). Immunohistochemical analysis confirmed SMA(+), Vimentin(+), and CD34(+) vascular staining with Ki-67 proliferation index of 10%, supporting classification as a glomus tumor of uncertain malignant potential. The patient remained disease-free throughout 24-month postoperative surveillance. Pulmonary glomus tumors (PGTs), constituting 0.02% of primary pulmonary neoplasms, demonstrate perivascular glomus cell proliferation [1,2]. WHO classification

distinguishes benign, borderline, and malignant subtypes. Most lesions are incidentally identified through routine imaging, though nonspecific symptoms including hemoptysis may occur. Complete surgical excision remains definitive treatment, with extended surveillance recommended for borderline cases. This presentation underscores the diagnostic consideration of PGTs for well-defined pulmonary nodules in middle-aged females, particularly when accompanied by hemoptysis despite unremarkable tumor markers. Early surgical intervention, as demonstrated in this case, correlates with favorable long-term outcomes.

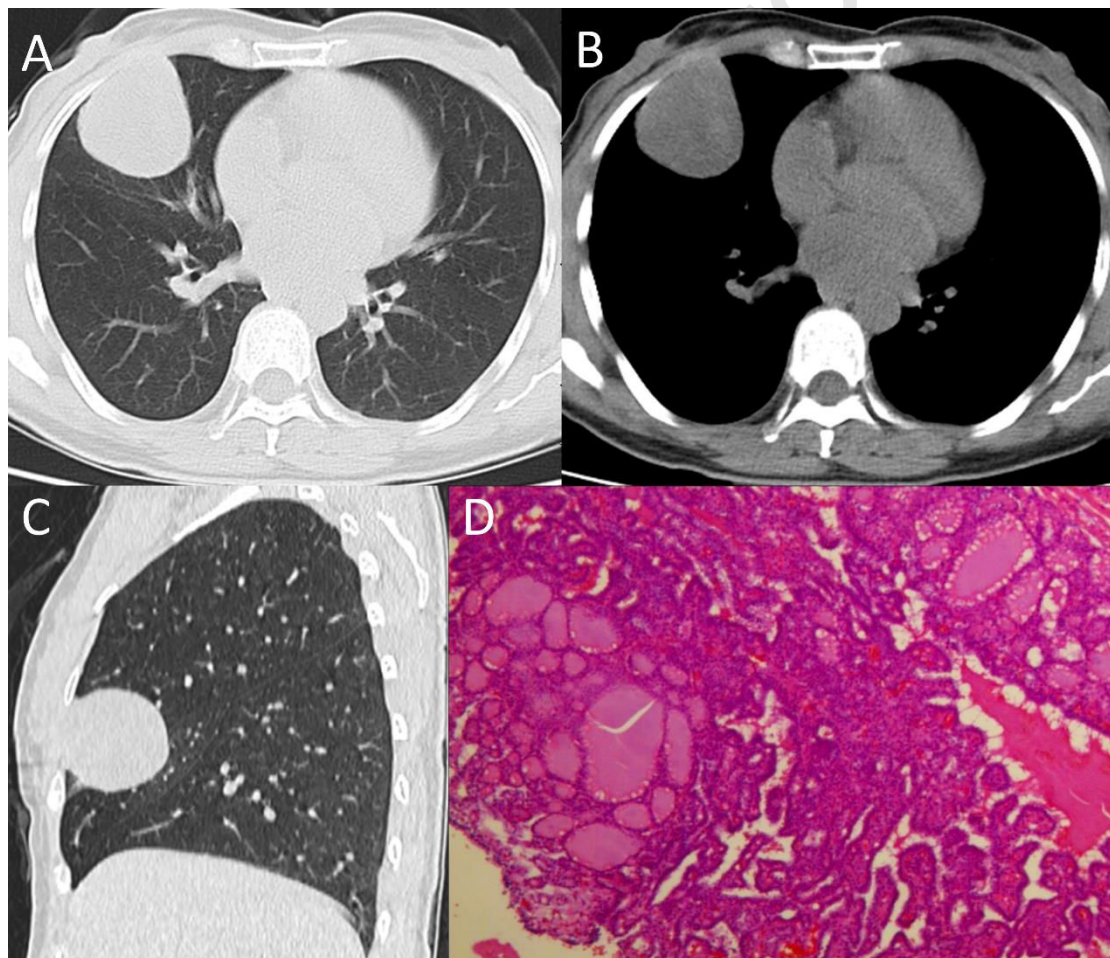


Figure 1. (A-C) chest CT revealed a well-circumscribed, homogeneous soft tissue mass (3.6×4.8 cm) in the anterior segment of the right upper lobe, lacking lobulation or spiculation. (D) The tumor cells were arranged in nests and sheets under microscopy, demonstrating uniform morphology with

clear cytoplasm and round nuclei containing finely granular chromatin. The stroma exhibited a delicate vascular network accompanied by focal myxoid degeneration. (HE×200)

Conflict of Interest Disclosures: The authors disclose no conflicts.

Fund: Jiangxi Provincial Administration of Traditional Chinese Medicine, Science and Technology Program [Project No. 2023B0479].

Author Contributions: B.L.L. contributed to the acquisition and analysis of data; B.L.L. contributed to drafting the text and preparing the figures.

Declaration: Never used any artificial intelligence tools or technologies to assist in generating the paper.

References

- [1] Dai SH, Tseng HY, Wu PS. A glomus tumor of the lung of uncertain malignant potential: a case report. *Int J Clin Exp Pathol*. 2019;12(3):1117.
- [2] Jin Y, Al Sawalhi S, Zhao D, et al. Behavior of primary tracheal glomus tumor, uncertain malignant potential subtype. *Gen Thorac Cardiovasc Surg*. 2019;67(11):991-995.

Fig.1

