

## Clinical Image

### Paracoccidioidomycosis: Endobronchial Involvement in a Rare Disease in Europe



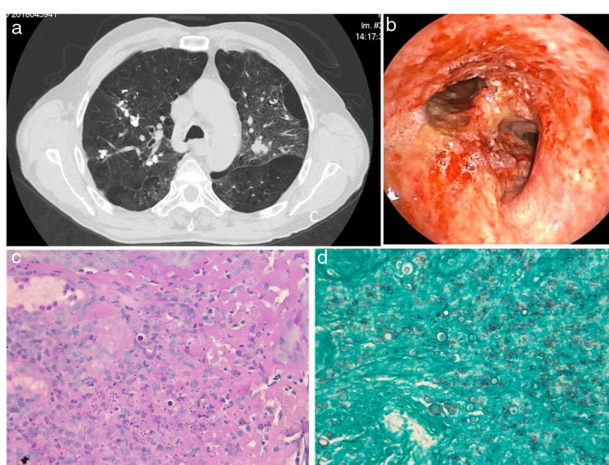
### Paracoccidioidomycosis: aspectos endobronquiales de una enfermedad rara en Europa

Cláudia Sousa<sup>a,\*</sup>, José Alves<sup>b</sup>, Michelle Cordeiro<sup>c</sup>

<sup>a</sup> Pulmonology Department, Hospital Central do Funchal, Portugal

<sup>b</sup> Clinical Pathology Department, Hospital Central do Funchal, Portugal

<sup>c</sup> Anatomical Pathology Department, Hospital Central do Funchal, Portuga



**Fig. 1.** Computed tomographic image of the patient thorax (a) and endobronchial aspects of disease at the distal third of patient's trachea (b); Histochemical detection of fungal forms in PAS coloration (c) and Grocott coloration (d).

We report the case of a 64 years old man, a former farmer in Venezuela, with heavy alcoholic and tobacco smoking habits with no immunosuppressive status.

As he presented hemoptoic sputum, a computed tomographic study was performed, showing multiple calcifications, fibro-cicatricial lesions scattered in both lungs, along with emphysema

and bronchiectasis. Bronchofibroscopy documented an exuberant inflammatory process, with nacreous plaques, hemorrhagic areas and ulceration of the lower third of tracheal mucosa and both bronchial trees. Histology of bronchial biopsies revealed a necrotizing granulomatous inflammatory process with polymorphonuclear cells and macrophages. Histochemical study revealed the presence of fungus in Grocott and PAS coloration stains (Fig. 1). No mycobacteria or neoplastic cells were detected.

A second bronchofibroscopy was executed to collect samples to mycological evaluation in a National Center, were PCR for detection of fungal DNA identified the fungus *Paracoccidioides brasiliensis*.

Paracoccidioidomycosis is endemic in South America, mainly Brazil (80%), Argentina, Colombia and Venezuela<sup>1,2</sup>. Although pulmonary involvement is frequent, endobronchial lesions solely rarely have been described<sup>2</sup> and in this case were initially misinterpreted as suggestive of neoplasm, what was excluded in histological studies. This patient presented clinical, imagiological and endoscopic improvement after treatment with itraconazole 200 mg for eighteen months.

## References

1. Marques SA. Paracoccidioidomycosis: epidemiological, clinical, diagnostic and treatment up-dating. An. Bras. Dermatol. 2013;88:700–11, <http://dx.doi.org/10.1590/abd1806-4841.20132463>.
2. Barreto MM, Marchiori E, Amorim VB, Zanetti G, Takayassu TC, Escuissato DL. Thoracic paracoccidioidomycosis: radiographic and CT findings. Radiographics. 2012;32:71–84, <http://dx.doi.org/10.1148/rg.321115052>.

\* Corresponding author.

E-mail address: [claudiasabinafsousa@gmail.com](mailto:claudiasabinafsousa@gmail.com) (C. Sousa).