



Clinical Image

**Pneumomediastinum and Massive Subcutaneous Emphysema Due to Lung Neoplasm<sup>☆</sup>**

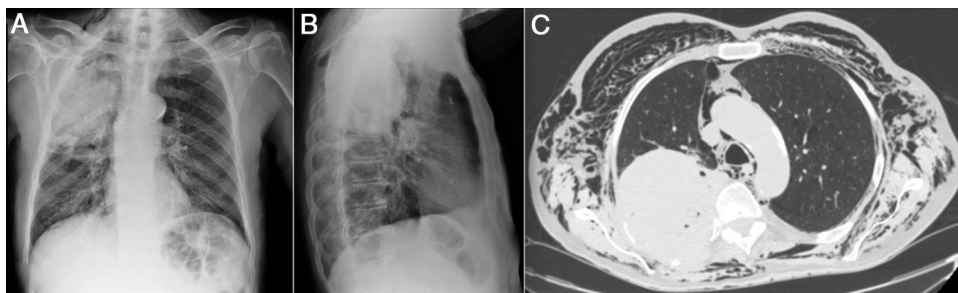
**Neumomediastino y enfisema subcutáneo masivo secundarios a neoplasia pulmonar**

Antonio Jesús Láinez-Ramos-Bossini,<sup>a,b,\*</sup> María del Carmen Pérez-García,<sup>a</sup> María Trinidad Rueda-Cáceres<sup>c</sup>

<sup>a</sup> Servicio de Radiodiagnóstico, Hospital Universitario Virgen de las Nieves, Granada, Spain

<sup>b</sup> Programa de doctorado en Medicina Clínica y Salud Pública, Universidad de Granada, Granada, Spain

<sup>c</sup> Servicio de Oncología Médica, Hospital Universitario Virgen de las Nieves, Granada, Spain



**Fig. 1.** (A and B) Plain chest X-ray in PA and lateral projections. Voluminous mass in right upper lobe, and minor cervical subcutaneous emphysema. (C) Chest CT (axial slice, mediastinum window). Resorption of posterior costal arches at the site of the mass, pneumomediastinum and massive subcutaneous emphysema.

We report the case of a 69-year-old man, former smoker, who attended the emergency department with constitutional symptoms and pain in the right shoulder. Chest radiograph (Fig. 1A and B) revealed a mass in the right upper lobe. His symptoms were controlled and he was referred to the respiratory medicine department, where positron emission tomography and chest computed tomography (CT) were performed, showing destruction of the ribs by the mass with incipient signs of subcutaneous emphysema. A few days after the biopsy (epidermoid carcinoma), he presented in our hospital with significant clinical deterioration. Examination revealed cervicofacial swelling, thoracocervical crackles, and hypophonesis in right fields, with tachypnea and arterial oxygen saturation of 93%. Urgent CT was performed (Fig. 1C), showing pneumomediastinum and massive subcutaneous emphysema. The patient was admitted to the oncology department, where 2 subcutaneous Penrose® drainage tubes were inserted, producing clinical and radiological improvement.

Pneumomediastinum with subcutaneous emphysema due to lung cancer is a rare entity attributed to tracheomediastinal fistula.<sup>1</sup> In our case, rib resorption had caused a subcutaneous bronchopleural fistula. Treatment of uncomplicated emphysema is conservative (oxygen therapy, analgesia, antibiotics), but in case of hemodynamic or respiratory involvement, skin incisions and drainage tubes can be used to release air.<sup>2</sup>

**References**

1. Kara J, Klimesova S, Pauk N. Neumomediastino y neumopericardio en un paciente con cáncer de pulmón espinocelular. Arch Bronconeumol. 2015;51:249–50, <http://dx.doi.org/10.1016/j.arbres.2014.04.014>.
2. Chotirmall SH, Morgan RK. Subcutaneous emphysema. BMJ Case Rep. 2014;2014, <http://dx.doi.org/10.1136/bcr-2013-201127>, pii:bcr2013201127.

<sup>☆</sup> Please cite this article as: Láinez-Ramos-Bossini AJ, Pérez-García MC, Rueda-Cáceres MT. Neumomediastino y enfisema subcutáneo masivo secundarios a neoplasia pulmonar. Arch Bronconeumol. 2020;56:4560.

\* Corresponding author.

E-mail address: [ajbossini@correo.ugr.es](mailto:ajbossini@correo.ugr.es) (A.J. Láinez-Ramos-Bossini).