

Clinical Image

Moon Sign Due to Hydatid Cyst in Chest-X-ray

Signo de la media luna debido a un quiste hidatídico en la radiografía de tórax

Yener Aydin*, Atilla Eroglu, Ali Bilal Ulas

Department of Thoracic Surgery, Ataturk University, Medical Faculty, Erzurum, Turkey



A 17 years old male presented with cough. Posteroanterior and laterally direct radiography showed cavitary lesion in the middle zone and “moon sign” in the lower zone of the right lung (Figs. 1 and 2). The patient underwent right thoracotomy. Cystotomy and capitonnage was performed to hydatid cyst.

Radiologically, there are many radiological signs associated with the hydatid cyst.^{1,2} Moon sign is seen when air enters between the pericyst and endocyst. This finding indicates that the hydatid cyst will rupture. Radiological findings have an important role in the diagnosis of pulmonary hydatid cyst.

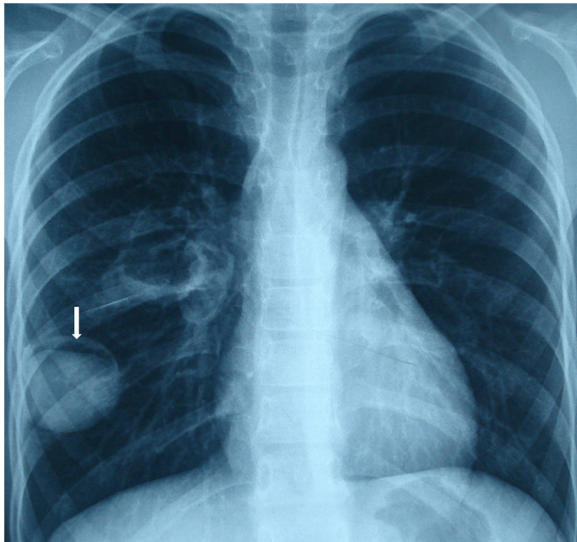


Fig. 1. Moon sign is seen on the posteroanterior chest X-ray (arrow).

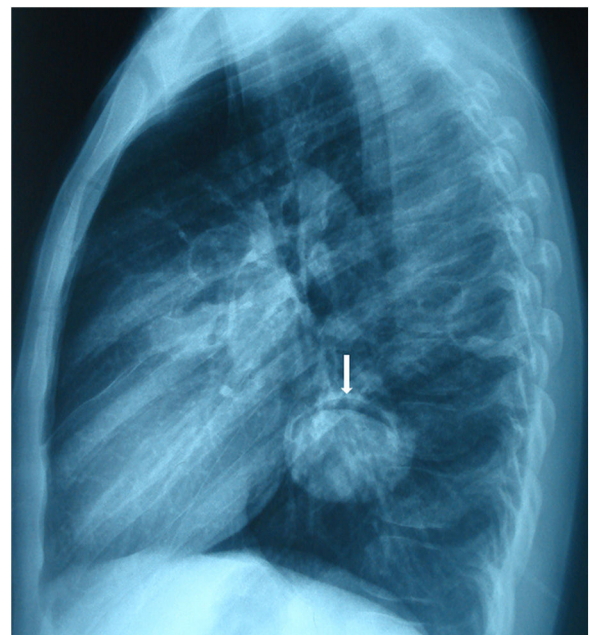


Fig. 2. Moon sign is seen on the lateral chest X-ray (arrow).

References

1. Aydin Y, Ogul H, Eroglu A. A rare radiological finding in pulmonary hydatid cyst: grape cluster appearance. Arch Bronconeumol. 2019 [Epub ahead of print].
2. Garg MK, Sharma M, Gulati A, Gorsu U, Aggarwal AN, Agarwal R, Khandelwal N. Imaging in pulmonary hydatid cysts. World J Radiol. 2016;8:581–7.

* Corresponding author.
E-mail address: dryeneraydin@hotmail.com (Y. Aydin).