

Clinical Image

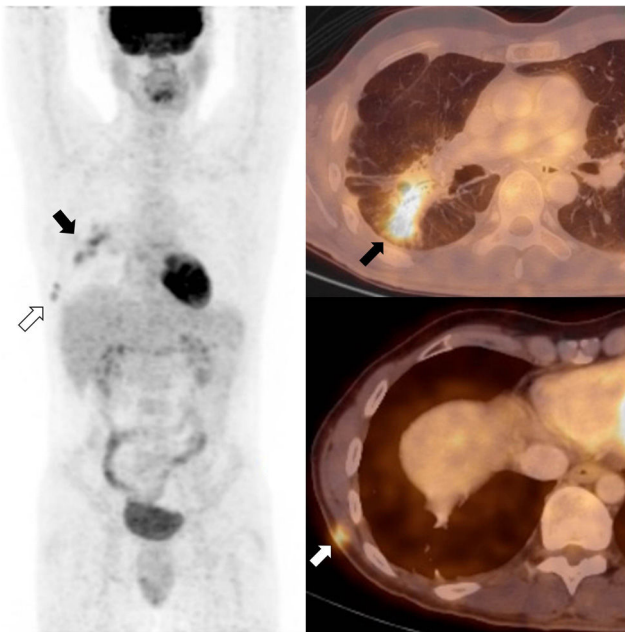
Scar Sarcoidosis 10 Years After Videothoracoscopy:  
Incidental Diagnosis at  $^{18}\text{F}$ FDG-PET-CT

Sarcoidosis en una cicatriz 10 años después de una videotoracoscopia:  
diagnostico incidental con  $^{18}\text{F}$ FDG-PET-CT

Ainhoa Viteri Jusué<sup>a,\*</sup>, Alfonso Montero de la Peña<sup>b</sup>

<sup>a</sup> Radiology Department. Hospital Universitario Araba

<sup>b</sup> Nuclear Medicine Department. Hospital Universitario Araba



**Figure 1.**  $^{18}\text{F}$ FDG-PET-CT showing confluent hypermetabolic nodules in the right lower lobe (black arrows) and two small hypermetabolic subcutaneous nodules in the right thoracic wall (white arrows).

A 49-year-old man with stage IV sarcoidosis presented with worsening respiratory symptoms and low-grade fever.

$^{18}\text{F}$ FDG-PET-CT (fig. 1) showed confluent hypermetabolic nodules in the right lower lobe (RLL) consistent with reactivation of pulmonary sarcoidosis (black arrows). Besides, two small

hypermetabolic subcutaneous nodules were revealed in the right thoracic wall. After carefully reviewing the medical record and the previous CT images, we arrived at the diagnosis of scar sarcoidosis at the scar of a video-assisted thoracoscopic biopsy of the RLL performed 10 years before, during the initial diagnostic work-up (white arrows). Treatment with infliximab was initiated and both the pulmonary and the cutaneous lesions resolved completely, thus confirming the diagnosis. Cutaneous sarcoidosis has many forms and affects 25% of patients with sarcoidosis. Scar sarcoidosis, an uncommon form of cutaneous sarcoidosis, represents less than 3% of the cases of skin involvement<sup>1</sup>. It consists in the development of sarcoid granulomas on previous scar tissue, and it should not be mistaken with keloids.

$^{18}\text{F}$ FDG-PET-CT is an emerging tool for the staging and response assessment of sarcoidosis<sup>2</sup>. In this case, the high sensibility of  $^{18}\text{F}$ FDG-PET was key to detect the granulomas, whereas the spatial and contrast resolution of the CT allowed the precise characterization of their location and nature.

#### References

1. Yanardağ H, Pamuk ON, Karayel T. Cutaneous involvement in sarcoidosis: analysis of the features in 170 patients. *Respir Med.* 2003;97:978–82. [http://dx.doi.org/10.1016/S0954-6111\(03\)00127-6](http://dx.doi.org/10.1016/S0954-6111(03)00127-6).
2. Treglia G, Annunziata S, Sobic-Saranovic D, Bertagna F, Caldarella C, Giovanella L. The role of  $^{18}\text{F}$ -FDG-PET and PET/CT in patients with sarcoidosis: an updated evidence-based review. *Acad Radiol.* 2014;21:675–84. <http://dx.doi.org/10.1016/j.acra.2014.01.008>.

\* Corresponding author.

E-mail address: [ainhoa.viterijusue@osakidetza.eus](mailto:ainhoa.viterijusue@osakidetza.eus) (A. Viteri Jusué).