

Clinical Image

Thoracolithiasis: A Rare Cause of Migratory Thoracic Mass[☆]

Pleuroлита: una rara causa de lesión torácica migratoria

Llúria Cornellas, Juan Carlos Soler-Perromat, Ivan Vollmer*

Servicio de Radiodiagnóstico, Centro de Diagnóstico por la Imagen Clínic, Hospital Clínic, Barcelona, Spain

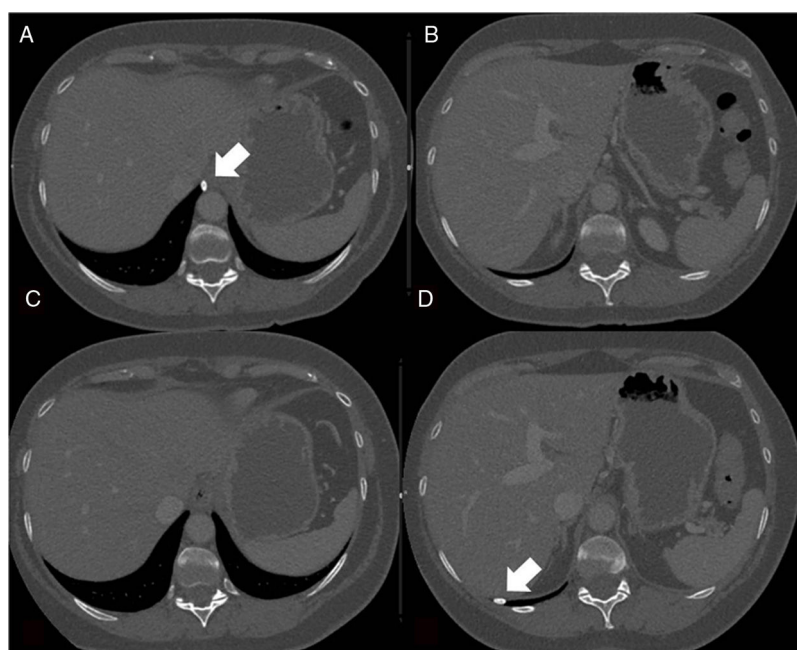


Fig. 1. (A and B) Chest CT bone window images showing the right calcified pleural nodule adjacent to the esophageal hiatus. (C and D) Chest CT bone window images obtained subsequently to images A and B, in which the calcified pleural nodule has migrated to the posterior costophrenic recess.

This was a 53-year-old female patient with a history of colon cancer diagnosed in 2016. A follow-up thoracoabdominal computed tomography (CT) revealed a calcified solid pleural nodule adjacent to the esophageal hiatus (Fig. 1A and B). A subsequent CT showed migration of the nodule within the pleural cavity to the posterior costophrenic recess, guiding a diagnosis of thoracolithiasis (Fig. 1C and D).

Thoracolithiasis is a rare entity with a prevalence of 0.086%.¹ It consists of thoracoliths, bodies that can be calcified or not, which move about freely inside the chest cavity, in the absence of a history of trauma, intervention, or pleuritis.² It is usually found incidentally

in asymptomatic patients older than 50 years of age, most often in the left hemithorax. Although they can be calcified, thoracoliths can be indistinguishable on CT from intrapulmonary nodules. They are difficult to aspirate percutaneously, so diagnosis is usually made when migration of the nodule is observed. There have been several theories about their origin, the most plausible being that they arise from the detachment of a focus of pericardial or pleural fat necrosis,³ which would explain their histological composition and typical location.²

References

1. Kinoshita F, Saida Y, Okajima Y, Honda S, Sato T, Hayashibe AHS. Thoracolithiasis 11 cases with a calcified intrapleural loose body. *J Thorac Imaging*. 2010;25:64–7.
2. Suwatanapongched T, Nitiwarangkul C. Thin-section CT findings of thoracolithiasis. *Jpn J Radiol*. 2017;35:350–7.
3. Kang N, Choi Y, Im Y, Choe J, Kim J, Han J, et al. A rare case of numerous thoracolithiasis with chest discomfort. *Respir Med Case Rep*. 2018;25:264–6.

[☆] Please cite this article as: Cornellas L, Soler-Perromat JC, Vollmer I. Pleuroлита: una rara causa de lesión torácica migratoria. *Arch Bronconeumol*. 2019;55:534.

* Corresponding author.

E-mail address: vollmer@clinic.cat (I. Vollmer).