

Clinical Image

Resection of Endobronchial Hamartoma Using the Ligasure[®] Technique[☆]

Extirpación de hamartoma endobronquial con Ligasure[®]

Ana Triviño,^{a,*} Laura Arroyo Pareja,^a Carolina España^b

^a Servicio de Cirugía Torácica, Hospital Universitario Puerta del Mar, Cádiz, Spain

^b Servicio de Neumología, Hospital Universitario Puerta del Mar, Cádiz, Spain

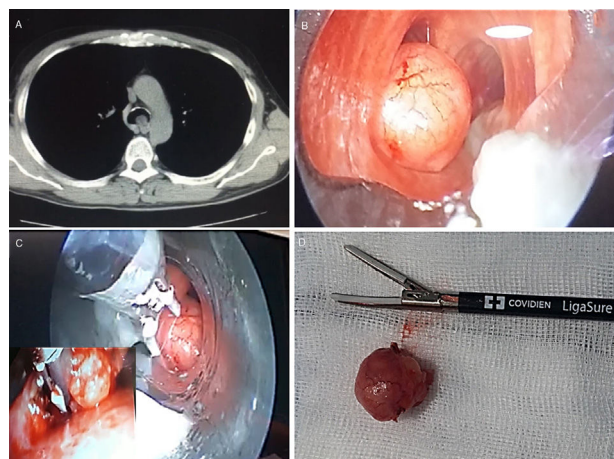


Fig. 1. (A) Chest CT, showing the tracheal obstruction of the lumen by the tumor. (B and C) Images during resection of the tumor by rigid bronchoscopy, using Ligasure[®]. (D) Image of the surgical specimen and the Ligasure[®] blades.

We report the case of a 48-year-old patient, undergoing an investigation of progressive dyspnea MRC grade II, during which an endoluminal polypoid lesion was revealed on X-ray. Fiberoptic bronchoscopy showed a hypervascularized pedunculated mass in the distal third of the trachea, next to the left main bronchus, obstructing 60%–70% of the lumen.

Given the characteristics of the tumor, we proceeded to resect it under rigid fiberoptic bronchoscopy control. Ligasure[®] was used for tumor resection. (Fig. 1). This is an advanced bipolar device that performs hemostasis by thermocoagulation, allowing us to resect and seal the pedicle under visual control, without diminishing FiO₂.

The patient was discharged 48 h after the procedure, without complications. When the diagnosis of hamartoma measuring 18 mm was confirmed, we decided to follow up the patient with fiberoptic bronchoscopy and radiological control. The patient was asymptomatic and disease-free after 6 months of treatment.

Tracheal hamartoma is a rare benign tumor. Thanks to advances in interventional pulmonology, the successful endoscopic treatment of benign endotracheal lesions is now possible,¹ although some authors defend surgical treatment.² Given the benign nature of the lesion and the bronchoscopic outcomes described in the literature, we opted for endoscopic resection and follow-up.

References

1. Wang J, Huang M, Qi X, Li M, Zhou L, Yin K. Resection of tracheal hamartoma by electrocautery and cryotherapy via bronchoscopy under laryngeal mask anaesthesia: report of 2 cases and review of the literature. *Zhongguo Fei Ai Za Zhi*. 2011;14:177–80 [article in Chinese].
2. Hon C, O'Hara CJ, Little VR. Endotracheal hamartoma case report: two contrasting clinical presentations of a rare entity. *Int J Surg Case Rep*. 2017;38:98–101.

[☆] Please cite this article as: Triviño A, Arroyo Pareja L, España C. Extirpación de hamartoma endobronquial con Ligasure[®]. *Arch Bronconeumol*. 2019;55:434.

* Corresponding author.

E-mail address: atrivi.17@hotmail.com (A. Triviño).