

Table 1
Awareness of and Preference for Pulmonology Before and After Rotation.

	Overall	Fourth Year	Fifth Year	Sixth Year	Significance
<i>n</i>	232	80	78	74	
Prior awareness	6.61 (1.40)	6.90 (1.32)	6.39 (1.44)	6.50 (1.41)	>.05
<i>n</i>	229	79	75	75	
Subsequent awareness	8.27 (1.13)	8.3 (1.2)	8.25 (1.2)	8.26 (1.06)	>.05
<i>n</i>	233	80	78	75	
Prior preference	5.18 (2.33)	5.87 (1.97)	5.02 (2.42)	4.62 (2.44)	.003
<i>n</i>	230	80	75	75	
Subsequent preference	5.86 (2.41)	6.30 (2.02)	5.82 (2.6)	5.45 (2.54)	>.05

believe that improving theoretical training, and in particular practical training, should be an objective for all SEPAR members involved in undergraduate training.

Unfortunately, few pulmonologists are involved in theoretical training; however, a great many are involved in practical training in the hospital setting, and this will give us the chance to improve not only clinical training, but also the perception of the specialty. According to students, there is much room for improvement in practical clinical training,⁷ so we must seize this as a golden opportunity to demonstrate to students the complete and complex nature of our specialty. We must continue to reflect on the improvements needed in practical training for degree-level students, not only to improve their skills, but also to show them the value of our specialty and thus improve our standing among other specialties.

References

- Palés-Argullós J. ¿Una Bolonia en cada facultad de medicina o una sola Bolonia? *Educ Med.* 2009;12 Suppl. 3:S7–11.
- Villena V, Álvarez-Sala JL. Horizontes en la neumología española: algunas reflexiones. *Arch Bronconeumol.* 2007;43:573–84.
- Álvarez-Sala Walther JL, Nieto Barbero MA, Rodríguez Trigo G. La formación clínica como piedra angular de los estudios de medicina. *Educ Med.* 2010;13 Suppl. 1:S28–31.
- Barrueco Ferrero M. Pulmonology teaching in medical schools and the future of the specialty. *Arch Bronconeumol.* 2016;52:501–2.
- Lobato RD, Villena V, Álvarez-Sala JL, García Seoane J, Rubio R, Fernández A, et al. La enseñanza de la práctica clínica en la Facultad de Medicina de la Universidad Complutense de Madrid. *Educ Med.* 2017;18 Suppl. 1:51–6.
- Lobato RD, Lagares A, Villena V, García Seoane J, Jiménez-Roldán L, Munarriz PM, et al. La selección de los graduados en Medicina para los puestos de residencia. Estudio comparativo de los métodos usados en diferentes países. *Neurocirugía.* 2015;26:3–12.
- Callizo A, Carrasco JP. The Medicine degree. A vision from students. *Educ Med.* 2015;16:100–3.

Miguel Barrueco Ferrero,^{a,b,*} Javier Pérez Rodríguez,^c
Enrique Barrueco-Otero,^d María Bartol Sánchez^b

^a Departamento de Medicina, Universidad de Salamanca, Salamanca, Spain

^b Servicio de Neumología, Hospital Universitario de Salamanca, Salamanca, Spain

^c Servicio Cirugía Plástica, Hospital Universitario La Paz, Madrid, Spain

^d Unidad Docente de Medicina Familiar y Comunitaria, Hospital de Barbastro, Huesca, Spain

* Corresponding author.

E-mail address: mibafe@telefonica.net (M. Barrueco Ferrero).

1579-2129/

Published by Elsevier España, S.L.U. on behalf of SEPAR.

Isolated Myopathy: An Unusual Manifestation of Inhaled Fluticasone Propionate and Ritonavir Interaction



Miopatía aislada: una manifestación inusual de interacción entre propionato de fluticasona inhalado y ritonavir

Dear Editor:

We report the case of a 58-year-old man with HIV infection, COPD and history of intravenous drug use, who was admitted to the hospital with bilateral lower extremity weakness and multiple falls over the past 3 months. He denied myalgias, paresthesias, fever or chills. The patient was compliant with his highly active antiretroviral therapy (HAART) that included lopinavir (500 mg twice daily), ritonavir (125 mg twice daily), efavirenz (600 mg once daily) and lamivudine (300 mg once daily). He was also taking inhaled fluticasone propionate-salmeterol (250/50 mcg, 2 puffs twice a day) and inhaled ipratropium for COPD.

Examination revealed a significant reduction in strength of bilateral hip flexion (2/5) and shoulder abduction (4/5) with relatively preserved distal motor strength. Deep tendon reflexes and sensory

exam were normal. Significant laboratory abnormalities included a slightly elevated serum aldolase 10.8 U/L (N: 1.5–7 U/L) but CPK was normal (33 U/L). HIV viral load was undetectable and CD4 count was 400. Thyroid function tests were normal. At this point, our differential diagnoses included inflammatory myopathies such as polymyositis and inclusion body myositis, HIV myopathy and antiretroviral induced myopathy. We also considered the possibility of myotonic dystrophy, muscular dystrophy, and myasthenia gravis.

Electromyography results were indeterminate; therefore, a biopsy was obtained from the left quadriceps muscle. It showed atrophic changes affecting type 2 fibers (Fig. 1). The biopsy showed no evidence of an inflammatory myopathy and there were no mitochondrial changes as those described in association with antiretroviral drugs. The histopathologic findings seen in our patient have been reported to be potentially consistent with myopathy secondary to disuse or glucocorticoids.^{2,3} Disuse atrophy was unlikely in our patient as he had been active until 3 months ago when the muscle weakness started. At this point, the possibility of glucocorticoid-induced myopathy was strongly considered. The only steroid that our patient had been exposed to was the inhaled steroid (fluticasone propionate). It was stopped and the patient showed marked improvement over the course of 4–6 weeks.

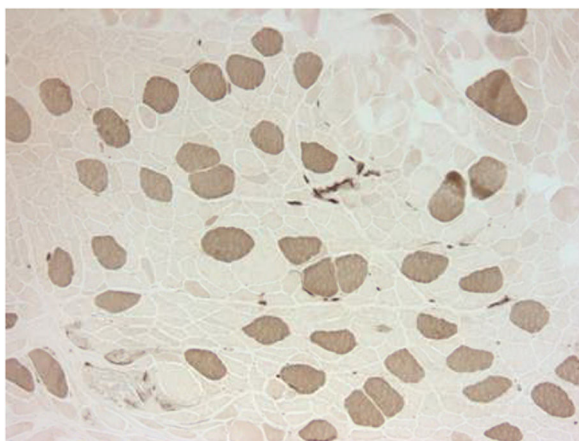


Fig. 1. ATP-ase reaction at pH=4.3 – type I fibers are dark, type II fibers are light. The type I fibers are uniform in size and relatively normal in size while the type II fibers are small and atrophic.

Looking back at our case, we realized that in the past our patient had been treated with Zidovudine/Lamivudine and Nelfinavir mesylate. 9 months earlier following HIV resistance testing, his HAART had been switched to Lopinavir/Ritonavir, Efavirenz and Lamivudine. Also, 5 months prior to presentation the patient had been switched from beclomethasone inhaler to fluticasone propionate-salmeterol. Above timeline shows that there was a 2-month overlapping period where both fluticasone and ritonavir were co-administered prior to the onset of symptoms. Considering this information and prior case reports, we suspected that ritonavir likely played a role in precipitating fluticasone propionate induced myopathy. After 2 months, our patient was started on inhaled beclomethasone in place of fluticasone propionate. Ritonavir was continued along with rest of the HAART. There has been no recurrence of symptoms.

Fluticasone propionate is a commonly prescribed inhaled glucocorticoid for the treatment of conditions such as asthma and COPD. Inhaled fluticasone propionate can be absorbed from the lungs and exert a dose-dependent suppression of cortisol.⁴ However, it has extensive first-pass metabolism in the liver.⁵ Most of the fluticasone propionate in the bloodstream is broken down into inactive 17-carboxylic acid derivatives by cytochrome P-450 3A4 (CYP3A4). Therefore, systemic toxicity from fluticasone propionate, in the absence of significant drug interactions is exceedingly rare. In our review of the literature, we found only one report (two cases) of fluticasone propionate induced myopathy and that too in the pediatric population.⁶ Fluticasone propionate's pharmacokinetics can dramatically change when inhibitors of CYP3A4 are co-administered. Ritonavir, a protease inhibitor used as a component of HAART is a potent CYP3A4 inhibitor.⁷ This CYP3A4 inhibition is not only responsible for the therapeutic effects of ritonavir but also leads to drug interactions and adverse effects. There have been around 40 case reports of iatrogenic Cushing's syndrome secondary to potentiation of fluticasone propionate's effects because of co-administered ritonavir.⁸ Fluticasone propionate induced osteoporosis has also been reported in the setting of ritonavir co-administration.⁹ In fact, ritonavir and fluticasone propionate co-administration increases fluticasone propionate's area under the curve and maximum concentration by 350-fold and 25-fold respectively.¹⁰ Similar interactions between other inhaled glucocorticoids and CYP3A4 inhibitors are much less likely because fluticasone propionate causes the most significant cortisol suppression.¹¹ Also, compared to other inhaled glucocorti-

coids, fluticasone propionate has higher receptor binding affinity, is highly lipophilic and has a larger volume of distribution.⁹

Unfortunately, HIV seropositive men are more likely to have bronchial hyperresponsiveness and suffer from effects of smoking.¹² Therefore, a significant number of these patients will likely end up needing inhaled glucocorticoids while being on protease inhibitors such as ritonavir. Clinicians can reduce the risk of these patients developing complications such as Cushing's, osteoporosis and myopathy, by avoiding inhaled fluticasone propionate. Beclomethasone dipropionate, budesonide, flunisolide etc. are much safer alternatives. On the hand, if HIV resistance testing allows, patients can be switched from a ritonavir-boosted protease inhibitor therapy to raltegravir based HAART.¹³

While Cushing's syndrome and osteoporosis resulting from this drug interaction have previously been reported, we believe our case is the first report of isolated myopathy secondary to fluticasone propionate-ritonavir interaction. Our patient did not have other overt signs of glucocorticoid toxicity such as buffalo hump, abdominal striae, diabetes, hypertension etc., this led to a delay in recognition of this complication. Perhaps earlier recognition of this complication could have spared our patient an invasive procedure (muscle biopsy).

Acknowledgements

The authors are grateful to their colleagues at the Medical College of Wisconsin and the Cook County Hospital for their continued support. This case was previously presented at the annual American Thoracic Society (ATS) conference (2017).¹

References

1. Ali MS, Ciftci FD, Kooragayalu S, Mba B, Kohli A, Ghori U, et al. An unusual complication of inhaled corticosteroids in an HIV infected patient. C48. COPD: case reports I. American Thoracic Society; 2017. A5707.
2. Khaleeli AA, Edwards RH, Gohil K, McPhail G, Rennie MJ, Round J, et al. Corticosteroid myopathy: a clinical and pathological study. *Clin Endocrinol (Oxf)*. 1983;18:155–66.
3. Snijders T, Wall BT, Dirks ML, Senden JMG, Hartgens F, Dolmans J, et al. Muscle disuse atrophy is not accompanied by changes in skeletal muscle satellite cell content. *Clin Sci*. 2014;126:557–66. <http://dx.doi.org/10.1042/CS20130295>.
4. Möllmann H, Wagner M, Meibohm B, Hochhaus G, Barth J, Stöckmann R, et al. Pharmacokinetic and pharmacodynamic evaluation of fluticasone propionate after inhaled administration. *Eur J Clin Pharmacol*. 1998;53:459–67.
5. Harding SM. The human pharmacology of fluticasone propionate. *Respir Med*. 1990;84 Suppl. A:9–25.
6. De Swert LF, Wouters C, de Zegher F. Myopathy in children receiving high-dose inhaled fluticasone. *N Engl J Med*. 2004;350:1157–9. <http://dx.doi.org/10.1056/NEJM200403113501122>.
7. Clevenbergh P, Corcostegui M, Gérard D, Hieronimus S, Mondain V, Chichmanian RM, et al. Iatrogenic Cushing's syndrome in an HIV-infected patient treated with inhaled corticosteroids (fluticasone propionate) and low dose ritonavir enhanced PI containing regimen. *J Infect*. 2002;44:194–5. <http://dx.doi.org/10.1053/jinf.2001.0928>.
8. Valin N, De Castro N, Garrait V, Bergeron A, Bouche C, Molina JM. Iatrogenic Cushing's syndrome in HIV-infected patients receiving ritonavir and inhaled fluticasone: description of 4 new cases and review of the literature. *J Int Assoc Physicians AIDS Care (Chic)*. 2009;8:113–21. <http://dx.doi.org/10.1177/1545109709332019>.
9. Epperla N, McKiernan F. Iatrogenic Cushing syndrome and adrenal insufficiency during concomitant therapy with ritonavir and fluticasone. *Springerplus*. 2015;4:455. <http://dx.doi.org/10.1186/s40064-015-1218-x>.
10. Boyd SD, Hadigan C, McManus M, Chairez C, Nieman Lk, Pau Ak, et al. Influence of low-dose ritonavir with and without darunavir on the pharmacokinetics and pharmacodynamics of inhaled beclomethasone. *J Acquir Immune Defic Syndr*. 2013;63:61–355. <http://dx.doi.org/10.1097/QAD.0b013e31829260d6>.
11. Brus R. Effects of high-dose inhaled corticosteroids on plasma cortisol concentrations in healthy adults. *Arch Intern Med*. 1999;159:1903–8.
12. Poirier CD, Inhaber N, Lalonde RG, Ernst P. Prevalence of bronchial hyperresponsiveness among HIV-infected men. *Am J Respir Crit Care Med*. 2001;164:542–5. <http://dx.doi.org/10.1164/ajrccm.164.4.2010019>.
13. Martínez E, Larrousse M, Llibre JM, Gutiérrez F, Saumoy M, Antela A, et al. Substitution of raltegravir for ritonavir-boosted protease inhibitors in HIV-infected patients: the SPIRAL study. *AIDS*. 2010;24:1697–707. <http://dx.doi.org/10.1097/QAD.0b013e3181e3608a.2833>.

Muhammad Sajawal Ali,^{a,*} Shravan Kooragayalu,^b
Benjamin I. Mba,^c Farah Ciftci Olsen^d

^d Department of Medicine, MacNeal Hospital, USA

^a Department of Pulmonary, Critical Care and Sleep Medicine,
Medical College of Wisconsin, Milwaukee, USA

^b Department of Pulmonary, Critical Care and Sleep Medicine, John H.
Stroger Jr. Hospital of Cook County, USA

^c Department Medicine, John H. Stroger Jr. Hospital of Cook County,
USA

* Corresponding author.

E-mail address: muali@mcw.edu (M.S. Ali).

1579-2129/

© 2018 SEPAR. Published by Elsevier España, S.L.U. All rights reserved.

Usefulness of Thoracic Ultrasound in the Diagnosis of Intercostal Pulmonary Hernias[☆]



Utilidad de la ecografía torácica en el diagnóstico de las hernias pulmonares intercostales

To the Editor,

Intercostal pulmonary hernias are relatively unusual, and the most frequent causes are trauma and thoracic surgery. Diagnosis is

almost always made by standard X-ray and chest CT scan. However, ambiguous cases can be diagnosed by chest ultrasound.

We report the case of a 65-year-old woman with a history of stage IB lung adenocarcinoma who had undergone left upper lobectomy by video-assisted thoracoscopy. The patient reported no pain, and local physical exploration of the surgical wound was normal. In the last follow-up chest CT scan, peripheral pulmonary opacity measuring approximately 24 mm in length was visualized, with minor extension to the intercostal space, which had increased

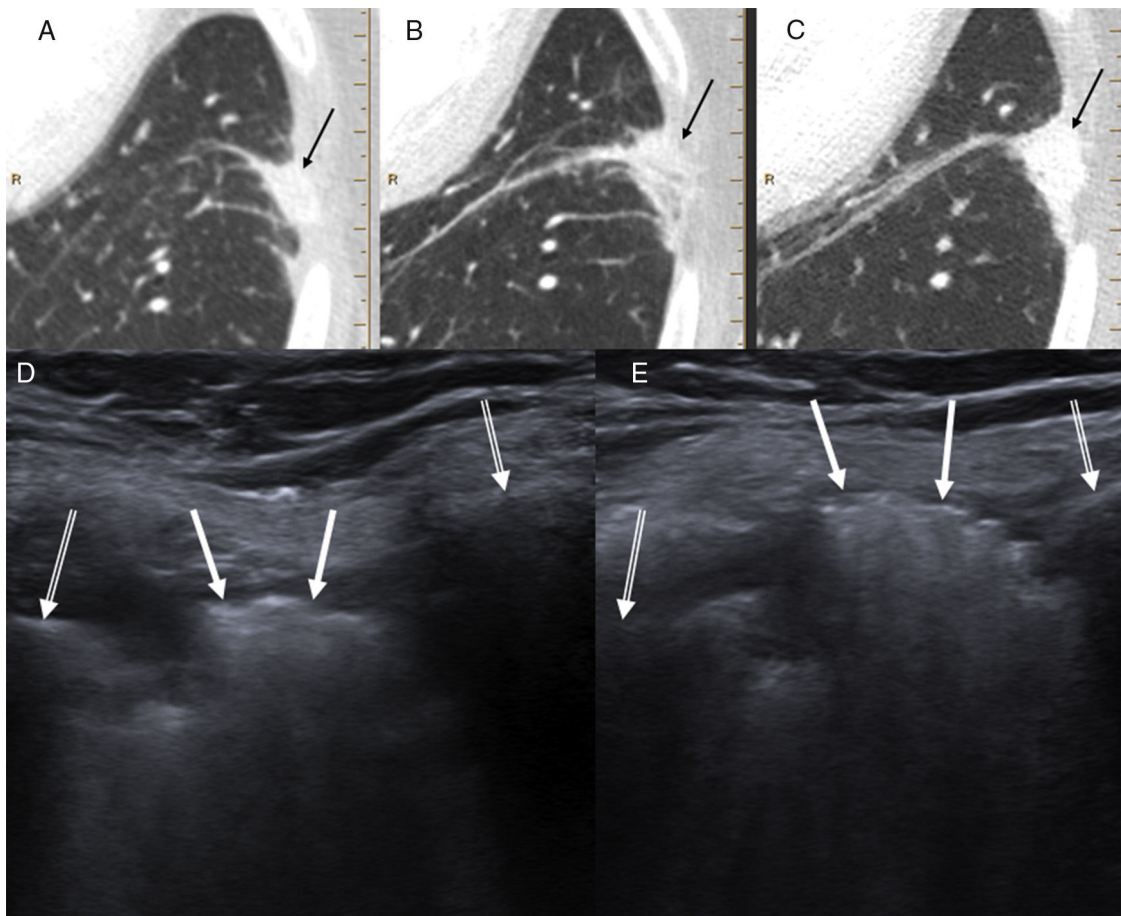


Fig. 1. (A–C) Series of follow-up CTs showing a left laterobasal peripheral pulmonary opacity with minor extension to the intercostal space gradually increasing in size and density (black arrows). (D) Chest ultrasound (Valsalva maneuver) showing a hyperechogenic lesion (white arrows) in the intercostal space between the lateral arches of the left seventh and eighth ribs (double white arrows), which mobilized during respiration. (E) Lesion protruding significantly toward the chest wall during the Valsalva maneuver. The patient was diagnosed with intercostal pulmonary hernia probably associated with thoracoscopy entry port for performing left upper lobectomy

[☆] Please cite this article as: Porres DV, Pallisa E, Sánchez AL, Persiva O. Utilidad de la ecografía torácica en el diagnóstico de las hernias pulmonares intercostales. Arch Bronconeumol. 2019;55:225–226.