

Original Article

Use of Magnetic Resonance Imaging for N-Staging in Patients with Non-Small Cell Lung Cancer. A Systematic Review

Tara Pereiro Brea^{a,*}, Alberto Ruano Raviña^{b,c}, José Martín Carreira Villamor^d, Antonio Golpe Gómez^a, Anxo Martínez de Alegría^d, Luís Valdés^{a,e}

^a University Hospital Complex, Pneumology Service, Santiago de Compostela, Spain

^b Medicine School. University of Santiago. Area of Preventive Medicine and Public Health, Santiago de Compostela, Spain

^c CIBER of Epidemiology and Public Health. CIBERESP, Madrid, Spain

^d University Hospital Complex, Radiology Service, Santiago de Compostela, Spain

^e Interdisciplinary Group of Research in Pneumology, Institute of Sanitary Investigations in Santiago (IDIS), Santiago de Compostela, Spain

ARTICLE INFO

Article history:

Received 28 October 2017

Accepted 12 March 2018

Keywords:

Diffusion-weighted imaging

STIR turbo spin-echo

Magnetic resonance imaging

Lung cancer

Lymph nodes

Systematic review

ABSTRACT

Introduction: The aim of this study is to assess the diagnostic value of the magnetic resonance imaging (MRI) in differentiating metastatic from non-metastatic lymph nodes in NSCLC patients compared with computed tomography (CT) and fluorodeoxyglucose (FDG) - positron emission tomography (PET) or both combined.

Methods: Twenty-three studies (19 studies and 4 meta-analysis) with sample size ranging between 22 and 250 patients were included in this analysis. MRI, regardless of the sequence obtained, were used for the evaluation of N-staging of NSCLC. Histopathology results and clinical or imaging follow-up were used as the reference standard. Studies were excluded if the sample size was less than 20 cases, if less than 10 lymph nodes assessment were presented or studies where standard reference was not used. Papers not reporting sufficient data were also excluded.

Results: As compared to CT and PET, MRI demonstrated a higher sensitivity, specificity and diagnostic accuracy in the diagnosis of metastatic or non-metastatic lymph nodes in N-staging in NSCLC patients. No study considered MRI inferior than conventional techniques (CT, PET or PET/CT). Other outstanding results of this review are fewer false positives with MRI in comparison with PET, their superiority over PET/CT to detect non-resectable lung cancer, to diagnosing infiltration of adjacent structures or brain metastasis and detecting small nodules.

Conclusion: MRI has shown at least similar or better results in diagnostic accuracy to differentiate metastatic from non-metastatic mediastinal lymph nodes. This suggests that MRI could play a significant role in mediastinal NSCLC staging.

© 2018 SEPAR. Published by Elsevier España, S.L.U. All rights reserved.

Uso de las imágenes por resonancia magnética para la estadificación ganglionar (N) del cáncer de pulmón de no microcítico. Revisión sistemática

RESUMEN

Introducción: El objetivo de este trabajo es evaluar el potencial diagnóstico de las imágenes por resonancia magnética (RM) para identificar nódulos linfáticos metastásicos frente aquellos no metastásicos en pacientes con cáncer de pulmón no microcítico (CPNM) en comparación con la tomografía computarizada (TC), la tomografía por emisión de positrones con ¹⁸F-fluorodesoxiglucosa (PET-FDG) o ambas técnicas combinadas.

Palabras clave:

Imagen ponderada por difusión

Secuencia STIR turbo espín-eco

Imagen por resonancia magnética

Nódulos linfáticos

Revisión sistemática

Abbreviations: ADC, apparent diffusion coefficient; CT, computed tomography; DW, diffusion weighted; EPI, echo planar imaging; FASE, fast advantage spin-echo; FDG, fluorodeoxyglucose; FN, false negative; FP, false positive; IASLC, International Association for the Study of Lung Cancer; LDCT, low-dose CT; LSR, lymph node saline ratio; MRI, magnetic resonance imaging; NPV, negative predictive value; NSCLC, non-small cell lung cancer; PET, positron emission tomography; SE, spin-echo; SI, signal intensity; STIR, short time inversion recovery; TN, true negative; TP, true positive.

* Corresponding author.

E-mail address: tpereirobrea@gmail.com (T.P. Brea).

Métodos: En el análisis se incluyeron 23 estudios (19 estudios y 4 metaanálisis) con tamaños de muestra entre 22 y 250 pacientes. Para la estadificación ganglionar (N) del CPNM se utilizaron imágenes de RM independientemente de la secuencia obtenida. Como estándar de referencia se usaron los resultados histopatológicos y el seguimiento clínico o por imagen. Se excluyeron aquellos estudios con tamaños muestrales menores de 20 casos, aquellos con menos de 10 nódulos linfáticos evaluados o estudios en los que no se usó un estándar de referencia. También se excluyeron los artículos que no presentaron suficientes datos.

Resultados: Se observó que la RM presentaba mayor sensibilidad, especificidad y precisión en la estadificación ganglionar (N) y el diagnóstico de nódulos linfáticos metastásicos o no metastásicos en pacientes con CPNM en comparación con la TC y el PET. Ningún estudio consideró a la RM inferior con respecto a otras técnicas convencionales (TC, PET y PET/TC). Otros resultados destacables de esta revisión son que con la RM se originaron menos falsos positivos en comparación con el PET, y su superioridad respecto al PET/TC en la detección de tumores de pulmón no operables, en el diagnóstico de infiltración en estructuras adyacentes o metástasis cerebrales, así como en la detección de nódulos de pequeño tamaño.

Conclusión: La RM dio lugar a mejores resultados o, al menos comparables, relacionados con la precisión diagnóstica para diferenciar nódulos linfáticos metastásicos de no metastásicos. Esto sugiere que la RM podría jugar un papel importante en la estadificación mediastinal en pacientes con CPNM.

© 2018 SEPAR. Publicado por Elsevier España, S.L.U. Todos los derechos reservados.

Introduction

Lung cancer is a major health problem worldwide and the most common cause of cancer death in developed countries.¹ In 2017 lung cancer is expected to be the second most frequent tumor in males and women and it will continue being the most frequent cause of cancer death.² Tobacco use is the largest preventable cause of cancer.³ Up to 10-15% of all lung cancers occur in never smokers⁴ and radon is the second risk factor of lung cancer in never-smokers.⁵

The TNM classification is the cancer staging system used to describe the anatomical scope of a tumor according to three components. Recently, the International Association for the Study of Lung Cancer (IASLC) has published the 8th edition.⁶ Nodal (N) status is important for prognosis and an adequate staging is essential for a subsequent optimal therapeutic approach.

Noninvasive techniques for mediastinal lymph node staging include computed tomography (CT), combined or not with fluorodeoxyglucose (FDG) - positron emission tomography (PET), PET/CT. Since 1980s, the possible role of magnetic resonance imaging (MRI) has been investigated.⁷ Traditionally, CT has been the main technique for N staging, but it is limited by a low sensitivity (55-65%) and specificity (65-75%) because it only uses size criteria (an axial short-axis diameter of 1 cm or greater) or abnormal shape or attenuation of the lymph node to suspect metastatic involvement.⁸

PET has been validated as a technique which is superior to CT when differentiating metastatic or non-metastatic lymph nodes as it provides metabolic information based on the glucose consumption from tumor cells. Its sensitivity and specificity are higher than CT but are still greater when both techniques are combined (PET/CT).⁹ However, PET has associated diagnostic limitations by confounding malignancy from inflammatory changes resulting in false positives and is limited by spatial resolution,⁹ as well as difficulties in detecting certain tumors whose lesions may be PET-negative (adenocarcinoma, carcinoid...), resulting in false negatives.¹⁰

Recent studies have reported that magnetic resonance imaging (MRI) could be useful for N-staging in non-small cell lung cancer (NSCLC) compared to conventional techniques (CT, PET, PET/CT)¹¹ by differentiating metastatic from non-metastatic nodes. Those studies have also shown that certain whole-body MRI sequences as short time inversion recovery (STIR) turbo spin-echo (SE) or diffusion weighted (DW) MRI are superior than conventional sequences (T1-weighted MR, T2-weighted MR) or echo planar imaging sequence (EPI-DWI).¹² Once MRI images are obtained,

a detailed study of them can be made from the qualitative or quantitative point of view. To determine the qualitative analysis, two radiologists are required to interpret the MR images and evaluate the probability that a lymph node contains metastasis using a five-point visual scoring system. Qualitative analysis depends on the consensus of the radiologists who have analyzed the images.^{12,13} Using the quantitative analysis all signal intensity (SI) of lymph nodes are normalized by comparing them with the signal intensity of the 0.9% saline phantom to produce the lymph node saline ratio (LSR).¹³ The rationale for detecting a positive nodule is that malignant tumors have more cellularity and less extracellular space than normal tissue, resulting in higher SI values. DW MRI bases the analysis of the images through water molecules movement in biological tissues (Brownian movement), taking into account that in malignant tumors and those regions affected by metastasis will have restricted water molecules movement than normal, resulting in a decreased apparent diffusion coefficient (ADC).¹⁴

The purpose of the present study is to perform a systematic review to assess the overall diagnostic value of MRI to discriminate between metastatic and non-metastatic lymph nodes in primary NSCLC patients in comparison with PET/CT.

Material and methods

Literature research

A literature research was performed in PubMed (Medline), EMBASE and Cochrane databases. To retrieve information the following search strategy was employed in PubMed using a combination of MeSH terms ("Magnetic Resonance Imaging" [Mesh] AND "Lung Neoplasms" [Mesh]); AND "Mediastinal staging" [Mesh] AND "Clinical staging" [Mesh] AND "Non-invasive" [Mesh] AND "NSCLC" [Mesh]. The following limits were used: language (English or Spanish), humans and publications dating from 01/01/2007 to 15/08/2017. The reference lists of identified articles were also manually searched to obtain additional papers. The reports found to be eligible on the basis of their title and, subsequently, from the abstract, were then selected to further determine suitability for inclusion in the present study.

Inclusion and exclusion criteria

Eligible studies were reviewed and included in this systematic review according to the following inclusion criteria: MRI was used for the evaluation of N staging of lung cancer. Sufficient

information regarding true-positive (TP), false-positive (FP), true-negative (TN) and false-negative (FN) values could be identified or calculated from data in the original articles. Studies were excluded if the sample size was less than 20 cases, if less than 10 lymph nodes assessment were presented or studies where standard reference was not used. The only accepted standard reference was histology, excluding those articles that were used as standard reference clinical or imaging follow-up. Histopathology results were determined by percutaneous fine needle aspiration (PCNA), endobronchial ultrasound-guided transbronchial needle aspiration (EBUS), mediastinoscopy or after surgical lymph nodes resection through thoracotomy.

Data extraction and Quality Assessment

Search results were checked by one reviewer and if there were doubts regarding the inclusion or exclusion of a certain paper, this was solved by consensus by all authors. We developed a quality scale to score the quality of the included studies. Similar scales have been used previously by other groups when performing other systematic reviews.^{15,16} We considered 6 items to assess the quality of included studies which are shown in Table 1. Each item opted a score between 0 and 1 to 3 points (the higher the score the higher the quality).

Results

The search resulted in 1,234 studies. Of these 123, were selected for full text reading, and 23 (19 prospective studies and 4 meta-analysis) were finally included. The most frequent exclusion criterion was the study of lung lesions (solitary pulmonary nodule and masses) that did not include lymph nodes. The flowchart of the search is shown in Figure 1. Sample size is ranged between 22 and 250 patients. After careful reading of the studies, we could observe that over the last 10 years different MRI sequences for the study of lymph nodes have been used. We have focused the results in those sequences which have provided the most relevant results (STIR turbo SE and DWI MRI). Only 5 studies used other MRI sequences.¹⁶⁻²⁰

Table 1
Quality score to assess the included studies.

Item assessed	Characteristic	Weight
Total sample size	20-50	0
	51-100	1
	≥101	2
Radiologists	1	0
	2	1
	3	2
Type of MR	1,5T	0
	3T	1
Image analysis	Qualitative	0
	Quantitative	1
	Both	2
Use of the standard reference	Not used	0
	Partially nodes confirmed	1
	All nodes confirmed	2
Simultaneity of image tests *	No	0
	Yes	1
TOTAL		10

* Defined as <30 d other than the waiting time for the pathology results after surgery.

Prospective and retrospective studies' results

The largest prospective study published on N-stage assessment in patients with NSCLC was published by OHNO et al.²¹ in 2011 including 250 patients with mediastinal and hilar lymph nodes studied by STIR FASE imaging, DW MR imaging and FDG PET/CT. In both quantitative and qualitative N-stage assessment, STIR turbo SE showed more sensibility and accuracy (82.8% and 86.8%, respectively, in quantitative assessment; 77.4% and 84.4%, respectively, in qualitative assessment) compared to DW MR imaging or FDG PET/CT. The same group carried out the study with the highest quality,²² which included 140 consecutive patients. The capabilities for TNM classification and the assessment of clinical stage and tumor resectability among whole-body MRI were compared, coregistering PET/MR imaging with or without SI assessment, and FDG PET/CT. It was shown that the capability to assess tumor resectability and accuracy of whole-body MRI and PET/MRI with SI assessment (97.1%) was significantly higher than that of PET/MRI without SI assessment and FDG PET/CT (85%; p<0.001). In other

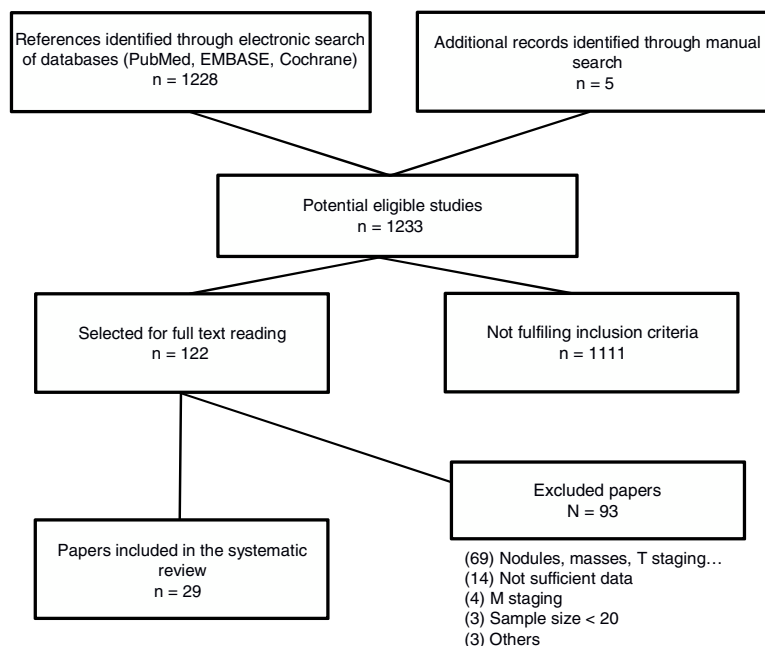


Figure 1. Flowchart of study selection process.

studies by OHNO et al.^{12,23} it has been observed that sensitivity and diagnostic accuracy was higher with MRI (STIR turbo SE and fast advantage spin-echo sequence (FASE-DWI)¹²) compared with FDG PET/CT both for quantitative²³ and qualitative¹² analysis.

Other published studies^{24–30} comparing MRI sequences (fundamentally DWI-MRI and STIR turbo SE sequences) and FDG PET/CT, showed similar results. Both sensitivity and diagnostic accuracy²⁵ were higher with MRI sequences than with PET/CT, in addition a high negative predictive value (NPV) of DW-MRI (97%).²⁷ These studies postulated MRI as a technique that could correctly differentiate metastatic from non-metastatic nodes and showed fewer false-positives than PET in the mediastinum ($p=0.011$) and in normal or enlarged lymph nodes. No statistically significant differences were observed between DWI-MRI and STIR turbo SE.²⁵

There were three studies^{26,28,31} comparing MRI with FDG PET/CT for preoperative -nodal staging in NSCLC (with 93, 52 and 49 patients, respectively). Diagnostic accuracy of MRI was not significantly higher than that of FDG PET/CT, although they concluded that it had fewer false positives, and probably the best option would be to combine both methods for an adequate preoperative staging, even avoiding the use of invasive diagnostic techniques.

One study³² with 33 patients compared prospectively the diagnostic efficacy of MRI with FDG PET/CT. Results showed that MRI was a feasible technique for the assessment of NSCLC, comparable but not superior to FDG PET/CT in N-staging.

Characteristics of included studies are summarized in [Table 2](#) and [Table 3](#).

Meta-analysis and systematic review results

Four meta-analysis with 12, 10, 18 and 19 studies included, respectively, had been published^{11,33–35} comparing the diagnostic value of MRI in N staging of NSCLC which agreed on its high specificity and diagnostic accuracy in detecting metastatic lymph nodes in patients with lung cancer. These studies had restrictive inclusion criteria and were focused in a specific type of MRI. No study reported serious complications.

Study quality

The scoring of the included studies ranged between 0 and 10 points. The highest quality was for three studies with more than 100 patients. The mean scoring of the included studies was 5.6 points. [Table 2](#) presents in detail the quality of each study.

Discussion

The results of this systematic review point out that MRI, especially in some sequences such as STIR turbo SE and DW-MRI, has a high diagnostic accuracy to diagnose metastatic or non-metastatic lymph nodes in N-staging in non-small cell lung cancer patients. These studies specially highlighted its high sensitivity, specificity and diagnostic accuracy. In comparison with conventional techniques such as combined FDG PET/CT or both techniques separately, some studies considered MRI sequences superior for N-staging, and some other studies considered MRI sequences comparable but not superior to conventional techniques. No study considered MRI inferior than conventional techniques. Even in those studies where MRI was comparable but not superior to FDG PET/CT, MRI had fewer false positives.

Knowing that MRI has a useful role in the preoperative mediastinal and hilar nodal staging, the next step is where this imaging test may fit in clinical practice. Some authors speculate that MRI sequences are superior to FDG PET/CT and can be used in place of it as an alternative in the clinical practice.^{17,27} Other study^{32,34,24}

support that MRI and FDG PET/CT, would provide complementary information, so using them together without eliminating or replacing any test as part of the usual protocol would improve significantly diagnostic capability for N-staging²⁸ and making it less necessary to use invasive diagnostic techniques.³¹ Finally, the remaining studies, regardless of whether they conclude that MRI is superior or similar than FDG PET/CT, do not make recommendations on the ideal time to perform the MRI in the preoperative staging, whether it should replace some conventional test, or if otherwise, it would be better to combine them.

Some advantages of MRI should be highlighted: 1) there is no radiation exposure; 2) patients do not have to fast before examination; 3) less test time (30 minutes for DWI or STIR vs. 90 minutes for PET/CT); 4) less test cost;²⁴ 5) administration of contrast medium is not necessary;²⁷ 6) easier accessibility to MRI because not all hospitals have PET/CT.¹⁴ MRI is a simple technique available in most hospitals that allows performing between 5–20 sequences, each of which provides a type of information about tissues (anatomical or functional). In some of them, as in case of STIR sequence that is performed with cardiac synchronization, the use of some software that usually comes integrated in the resonance device itself may be required. It should also be noted that there are also disadvantages: presence of motion artifacts (breathing, cardiac movement, pulsations...) or other artifacts as metallic bodies, tattoos, prostheses, surgical clips, etc. They might negatively affect the quality of lung image. Claustrophobia is the main inconvenient of this technique.³⁶

Methodological shortcomings of the available literature

Different methodological problems continue to hinder MRI use in clinical practice. Radiologists and nuclear medicine physicians have more experience and availability with FDG PET/CT images than MRI³⁷ probably because their use has not been sufficiently encouraged or protocols have not been developed. It would be convenient to investigate which sequence of MRIs are more useful for mediastinal staging with multicenter comparative studies and establish an optimal acquisition protocol that has not been defined currently. It is also necessary to develop a standard acquisition protocol as a routine clinical application.³³ The methods that have been used until now to differentiate metastatic from non-metastatic lesions have been the quantitative (ADC value) and qualitative (visual score) methods. Although no significant differences have been demonstrated between them, the sensitivity and accuracy of quantitative methods has been found to be slightly higher compared to the qualitative method (93% and 87% vs. 88% and 86%, respectively).¹³ Tumor lesions are known to have a decreased ADC value; however, cut off values have not been established to clearly differentiate between metastatic and non-metastatic lymph nodes to date.¹³ It is important to keep in mind that specifically lesions (necrotic lesions, mucinous carcinoma or small nodules) could not be diagnosed by MRI. For example, ADC value for necrotic lesions could be lower than lesions without necrosis. Mucinous carcinoma, with its hypointense nature, could incur in false negative because it behaves with high ADC values.³⁸ Nodules smaller than 3 mm cannot be detected by MRI³⁸ and between 4–6 mm^{23,25,29} could go unnoticed even if they have micrometastatic foci.

Other published reviews

The published meta-analyses did not offer a global view of MRI and this was the reason for performing the present review. SHEN et al.³⁴ included in their meta-analysis 18 studies but they only studied DW-MRI sequence. CHEN et al.³³ only studied DW-MRI sequence too. The conventional method of usual clinical practice with which MRI was compared was PET or CT separately and, in few studies with PET/CT (both combined). WU et al.³⁵ included 19

Table 2

Characteristics of included studies (19 prospective studies; does not include meta-analysis).

AUTHOR/YEAR	COUNTRY	DESIGN	N	NODES	AGE	SEX (M/W)	NODES LOCATION	TUMOR	MR	SEQUENCES	STANDARD REFERENCE	CONCLUSION	STUDY'S QUALITY
Nomori, 2016 ³⁰	Japan	P	157	1033	70	95/62	Hilar and mediastinal	124 ADC, 24 SQC, 3 ADSC, 4 LCC, 2 OTH	1.5T	T1-weighted T2-weighted DWI-MR	Histology *TCT	Superior to PET; correct identification of false positives	6 points
Huellner, 2016 ¹⁶	Switzerland	P	42	ND	65	29/13	Hilar and mediastinal	ND	3T	T1-weighted T1-inversion T2-weighted	Histology *TCT	Comparable to PET/CT (not superior)	6 points
Ohno, 2015 ¹²	Japan	P	95	78	72	56/39	Hilar and mediastinal	71 ADC, 10 ADCis, 8 SQC, 4 ADSC, 2 LCC	3T	STIR-FASE FASE-DWI EPI-DWI	Histology *TCT	STIR-FASE and FASE-DWI superior to PET/CT and EPI-DWI (sensitivity and accurate)	7 points
Ohno, 2015 ²²	Japan	P	140	ND	72	75/65	Hilar and mediastinal	103 ADC, 20 ADCis, 13 SQC, 1 LCC	3T	T1 field echo T1-weighted STIR-FASE	Histology *TCT	Superior to PET/CT	8 points
Schaarschmidt, 2014 ¹⁷	USA	P	38	146	60.1	24/14	ND	16 ADC, 6 SQC, 16 OT	3T	T1 FLASH TIRM T2 BLADE TSE T2 HASTE T2 TrueFISP VIBE sequence	Histology *EBUS *TCT	Superior to PET/CT	5 points
Heusch, 2014 ¹⁸	Germany	P	22		65	12/10	Hilar and mediastinal	ND	3T	T1-weighted T2-weighted T1 FLASH	Histology *EBUS *TCT	Comparable to PET/CT (not superior)	7 points
Xu, 2013 ²⁹	China	P	42	119	55	27/15	Mediastinal	ND	1.5T	DWI-MR	Histology *TCT	Clinically useful to detect malignancy	4 points
Usuda, 2013 ³⁸	Japan	P	158	ND	68	94/64	Hilar and mediastinal	114 ADC, 36 SQC, 10 OT	1.5T	T1-weighted T2-weighted DWI-MR	Histology *TCT	DWI-MR superior to PET/CT	4 points
Sommer, 2012 ³²	Switzerland	P	33	ND	63.9	24/9	Hilar and mediastinal	16 ADC, 8 SQC, 2 LCC, 1 ADSC, 1 NET, 6 OT	1.5T	T1-weighted T2-weighted DWIBS	Histology (no data) or cytology	DWIBS comparable to PET/CT (not superior)	4points
Kim, 2012 ³¹	Korea	P	49	ND	62	29/20	Hilar and mediastinal	32 ADC, 14 SQC, 2 LCC, 1 PDN	1.5T	T2-weighted DWI-MR	Histology *PCNA *EBUS *MDT *TCT	Combined MRI and PET/TC improve the sensitivity	5 points
Ohno, 2011 ²¹	Japan	P	250	1122	72	136/114	Hilar and mediastinal	218 ADC, 23 SQC, 6 LCC, 3 ADSC	1.5T	STIR-FASE DWI-MR	Histology *MDT *TCT	STIR-FASE superior to PET/CT and DWI-MR (sensitivity and accurate)	6 points
Nakayama, 2010 ²⁵	Japan	P	70	441	68	38/32	Hilar and mediastinal	52 ADC, 18 SQC	1.5T	T1-weighted T2-weighted DWI-MR STIR-MR	Histology *TCT	DWI-MR useful differentiating malignancy	4 points

Table 2 (Continued)

AUTHOR/YEAR	COUNTRY	DESIGN	N	NODES	AGE	SEX (M/W)	NODES LOCATION	TUMOR	MR	SEQUENCES	STANDARD REFERENCE	CONCLUSION	STUDY'S QUALITY
Moriwaka, 2008 ²⁸	Japan	P	93	137	66.1	76/17	Hilar and mediastinal	39 ADC, 28 SQC, 12 OTH, 14 BNG	1.5T	STIR-FASE	Histology *EBUS *MDT *TCT	STIR-FASE not superior to PET/CT. Better combine them.	5 points
Hasewaga, 2008 ²⁷	USA	P	42	ND	66	30/12	Mediastinal nodes	ND	1.5T	DWI-MR	Histology *TCT	Useful (high negative predictive value)	2 points
Yi, 2008 ¹⁹	Korea	P	135	712	61	125/40	Hilar and mediastinal	86 ADC, 59 SQC, 9 PDN, 3 PLC, 3 ADSC, 3 SRC, 2 LCC	3T	T1-weighted T2-weighted	Histology *PCNA *TCT	Comparable to PET/CT (not superior)	8 points
Plathow, 2008 ²⁶	Germany	P	52	ND	62	36/16	ND	ND	1.5T	WB-MRI	Histology *MDT *TCT	Combined WB-MRI and PET/TC has positive effects for TNM staging	6 points
Nomori, 2008 ²⁴	Japan	P	88	734	70	47/41	Mediastinal nodes	67 ADC, 18 SQC, 3 ADSC	1.5T	DWI-MR	Histology *TCT	Superior to PET/CT (less false positives)	4 points
Ohno, 2007 ²³	Japan	P	115	ND	68	59/56	Hilar and mediastinal	96 ADC, 13 SQC, 6 LCC	1.5T	STIR-Turbo SE	Histology *MDT *TCT	STIR-Turbo SE superior to PET/CT (sensitivity and accurate)	7 points
Kim, 2007 ²⁰	Korea	P	113	570	61	91/22	Hilar and mediastinal	58 ADC, 41 SQC, 3 LCC, 3 ADSC, 3 PLC, 2 SRC, 2 PDN, 1 CND	3T	T1-weighted T2-weighted	Histology *MDT *TCT	Useful detecting malignancy	9 points

ADC: adenocarcinoma. ADCis: adenocarcinoma in situ. ADSC: adenosquamous. BLADE: proprietary name for periodically rotated overlapping parallel lines with enhanced reconstruction [PROPELLER] in MR systems. BNG: benign. CND: carcinoid. DWI-MR: diffusion weighted imaging magnetic resonance. DWIBS: single shot echo planar imaging. EBUS: endobronchial ultrasound-guided transbronchial needle aspiration. FLASH: fast low angle shot gradient echo sequence. HASTE: half fourier acquired single short turbo spin echo sequence. LCC: large cell carcinoma. M: male. MDT: mediastinoscopy. MEC: mucoepidermoid carcinoma. MR: magnetic resonance. MX: mixed small cell carcinoma and adenocarcinoma. NET: neuroendocrine tumor. NSCLC: non-small cell lung cancer. OTH: others. P: prospective. PCNA: percutaneous fine needle aspiration. PDN: poorly differentiated non-small cell lung cancer. PLC: pleomorphic carcinoma. R: retrospective. SCC: small cell carcinoma. SQC: squamous cell carcinoma. SRC: sarcomatoid carcinoma. TCT: thoracotomy.

Table 3
Comparison of diagnostic performance for lymph node metastasis by all methods.

STUDY	MRI					PET/CT or CT*				
	Sensitivity (%)	Specificity (%)	Accuracy (%)	PPV (%)	NPV (%)	Sensitivity (%)	Specificity (%)	Accuracy (%)	PPV (%)	NPV (%)
Nomori, 2016 ³⁰	79	92	75	75.2	57.5	58	90	67	ND	ND
Huellner, 2016 ¹⁶	ND	ND	77	ND	ND	ND	ND	86	ND	ND
Ohno, 2015 ¹²	82.1	98.7	90.4	98.5	84.6	57.7	97.4	77.6	95.7	69.8
Ohno, 2015 ²²	100	92.9	98.6	98.2	100	93.8	85.7	92.1	96.3	77.4
Schaarschmidt, 2015 ¹⁷	ND	ND	ND	ND	ND	ND	ND	ND	ND	ND
Heusch, 2014 ¹⁸	88	93	91	88	93	75	86	82	75	86
Xu, 2013 ²⁹	85.2	100	87.8	100	60	ND	ND	ND	ND	ND
Usuda, 2013 ³⁸	63.9	98.4	90.6	75.9	93.1	36.1	96.8	83.1	68.4	85.1
Sommer, 2012 ³²	44	93	85	61	89	47	96	88	71	90
Kim, 2012 ^{# 31}	69	93	89	71	93	46	96	87	75	88
Ohno, 2011 ²¹	82.8	89.2	86.8	81.9	89.7	72.4	94.2	85.6	85.2	85.8
STIR (top)										
DWI (lower)										
Nakayama, 2010 ²⁵	74.2	90.4	84.4	82.1	85.5					
STIR (top)	50	98.1	87.1	88.9	86.9	ND	ND	ND	ND	ND
DWI (lower)										
Moriwaka, 2008 ²⁸	56.3	100	90	100	88.5					
Hasewaga, 2008 ²⁷	96.3	67.3	84.7	81.4	92.5	90.2	60.5	80.3	79.6	81.8
Yi, 2008 ¹⁹	80	97	95	80	97	92	100	ND	ND	ND
Plathow, 2008 ²⁶	52	94	86	75	88	48	96	86	75	88
Nomori, 2008 ^{# 24}	88.5	96.1	ND	ND	ND	92.3	100	ND	ND	ND
Ohno, 2007 ²³	67	99	ND	95.6	97.1	67	97	ND	92.3	0
Kim, 2007 ²⁰	89	99	98.2	89	99	83.2	96.2	95.1	65.9	98.3
	53	91	86	ND	ND	ND	ND	ND	ND	ND

* depending on the study; #Kim's study: MRI results are combined with PET/CT, not MRI alone.
PPV: positive predictive value; NPV: negative predictive value.

studies where they compared DW-MRI with FDG PET/CT but only in 3 of the 19 studies patients underwent DW-MRI, in the remaining 16, they only underwent FDG PET/CT. Finally, PEERLINGS et al.¹¹ included only 12 studies with very strict selection criteria. For this reason, we considered to carry out this systematic review to offer a larger number of studies, with a broader view and considering all MRI sequences for the mediastinal lymph nodes study.

Recently, the first screening of lung cancer using low-dose CT (LDCT) compared to MRI has been published, and suitable results have been obtained in favor of MRI with an excellent sensitivity and specificity for the detection of nodules compared to LDCT. These results seem to reaffirm the promising use of resonance in the study of this type of neoplasms.³⁹

Conclusion

With the studies available, it can be concluded that MRI, and specially DWI sequence, seems to play a relevant role in the N-staging of patients with NSCLC, compared to conventional methods (CT, PET, separately and both combined). MRI has shown at least similar or better results in diagnostic accuracy to differentiate metastatic from non-metastatic lymph nodes. Conversely, it cannot be established with the current evidence which would be the best time to do it, if it could replace any of the usual imaging tests or if it could be combined with them.

It would be convenient to validate a resonance protocol, as well as the standardization of ADC values to differentiate between malignant and benign lesions. In the near future, additional prospective and multicenter studies are warranted to confirm the clinical role of MRI in the staging of lung cancer.

Authors contribution

Tara Pereiro. Conception of the work. Data collection. Data analysis and interpretation. Drafting the article. Critical revision of the article. Final approval of the version to be published.

Alberto Ruano. Conception of the work. Drafting the article. Critical revision of the article. Final approval of the version to be published.

José Martín Carreira. Critical revision of the article. Final approval of the version to be published.

Antonio Golpe. Critical revision of the article. Final approval of the version to be published.

Anxo Martínez. Critical revision of the article. Final approval of the version to be published.

Luis Valdés. Conception of the work. Drafting the article. Critical revision of the article. Final approval of the version to be published.

Conflicto de intereses

Los autores declaran no tener ningún conflicto de intereses.

References

- Fact Sheets by Cancer [Internet]. [cited 2017 Jul 19]. Available from: http://globocan.iarc.fr/Pages/fact_sheets.cancer.aspx?cancer=lung
- Siegel RL, Miller KD, Jemal A. Cancer Statistics, 2017. *CA Cancer J Clin*. 2017 Jan;67:7–30.
- Bialous SA, Sarna L. Lung Cancer and Tobacco: What Is New? *Nurs Clin North Am*. 2017 Mar;52:53–63.
- Samet JM, Avila-Tang E, Boffetta P, Hannan LM, Olivo-Marston S, Thun MJ, et al. Lung Cancer in Never Smokers: Clinical Epidemiology and Environmental Risk Factors. *Clin Cancer Res*. 2009 Sep 15;15:5626–45.
- Torres-Durán M, Ruano-Ravina A, Parente-Lamelas I, Leiro-Fernández V, Abal-Arca J, Montero-Martínez C, et al. Lung cancer in never-smokers: a case-control study in a radon-prone area (Galicia, Spain). *Eur Respir J*. 2014 Oct;44:994–1001.
- Detterbeck FC, Boffa DJ, Kim AW, Tanoue LT. The Eighth Edition Lung Cancer Stage Classification. *Chest*. 2017 Jan;151:193–203.
- Paul NS, Ley S, Metser U. Optimal imaging protocols for lung cancer staging: CT, PET, MR imaging, and the role of imaging. *Radiol Clin North Am*. 2012 Sep;50:935–49.
- Fernandes AT, Shen J, Finlay J, Mitra N, Evans T, Stevenson J, et al. Elective nodal irradiation (ENI) vs. involved field radiotherapy (IFRT) for locally advanced non-small cell lung cancer (NSCLC): A comparative analysis of toxicities and clinical outcomes. *Radiother Oncol J Eur Soc Ther Radiol Oncol*. 2010 May;95:178–84.
- Billé A, Pelosi E, Skanjeti A, Arena V, Errico L, Borasio P, et al. Preoperative intrathoracic lymph node staging in patients with non-small-cell lung

- cancer: accuracy of integrated positron emission tomography and computed tomography. *Eur J Cardio-Thorac Surg Off J Eur Assoc Cardio-Thorac Surg*. 2009 Sep;36:440–5.
10. Cheran SK, Nielsen ND, Patz EF. False-negative findings for primary lung tumors on FDG positron emission tomography: staging and prognostic implications. *AJR Am J Roentgenol*. 2004 May;182:1129–32.
 11. Peerlings J, Troost EGC, Nelemans PJ, Cobben DCP, de Boer JJC, Hoffmann AL, et al. The Diagnostic Value of MR Imaging in Determining the Lymph Node Status of Patients with Non-Small Cell Lung Cancer: A Meta-Analysis. *Radiology*. 2016 Oct;281:86–98.
 12. Ohno Y, Koyama H, Yoshikawa T, Takenaka D, Kassai Y, Yui M, et al. Diffusion-weighted MR imaging using FASE sequence for 3T MR system: Preliminary comparison of capability for N-stage assessment by means of diffusion-weighted MR imaging using EPI sequence, STIR FASE imaging and FDG PET/CT for non-small cell lung cancer patients. *Eur J Radiol*. 2015 Nov;84:2321–31.
 13. Ohno Y, Hatabu H, Takenaka D, Higashino T, Watanabe H, Ohbayashi C, et al. Metastases in mediastinal and hilar lymph nodes in patients with non-small cell lung cancer: quantitative and qualitative assessment with STIR turbo spin-echo MR imaging. *Radiology*. 2004 Jun;231:872–9.
 14. Usuda K, Maeda S, Motono N, Ueno M, Tanaka M, Machida Y, et al. Diagnostic Performance of Diffusion-Weighted Imaging for Multiple Hilar and Mediastinal Lymph Nodes with FDG Accumulation. *Asian Pac J Cancer Prev APJCP*. 2015;16:6401–6.
 15. Torres-Durán M, Barros-Dios JM, Fernández-Villar A, Ruano-Ravina A. Residential radon and lung cancer in never smokers. A systematic review. *Cancer Lett*. 2014 Apr 1;345:21–6.
 16. Huellner MW, de Galiza Barbosa F, Husmann L, Pietsch CM, Mader CE, Burger IA, et al. TNM Staging of Non-Small Cell Lung Cancer: Comparison of PET/MR and PET/CT. *J Nucl Med Off Publ Soc Nucl Med*. 2016 Jan;57:21–6.
 17. Schaarschmidt BM, Buchbender C, Nensa F, Grueneisen J, Gomez B, Köhler J, et al. Correlation of the Apparent Diffusion Coefficient (ADC) with the Standardized Uptake Value (SUV) in Lymph Node Metastases of Non-Small Cell Lung Cancer (NSCLC) Patients Using Hybrid 18F-FDG PET/MRI. *PLoS ONE [Internet]*. 2015 Jan 9;10.
 18. Heusch P, Buchbender C, Köhler J, Nensa F, Gauler T, Gomez B, et al. Thoracic staging in lung cancer: prospective comparison of 18F-FDG PET/MR imaging and 18F-FDG PET/CT. *J Nucl Med Off Publ Soc Nucl Med*. 2014 Mar;55:373–8.
 19. Yi CA, Shin KM, Lee KS, Kim B-T, Kim H, Kwon OJ, et al. Non-small cell lung cancer staging: efficacy comparison of integrated PET/CT versus 3.0-T whole-body MR imaging. *Radiology*. 2008 Aug;248:632–42.
 20. Kim HY, Yi CA, Lee KS, Chung MJ, Kim YK, Choi BK, et al. Nodal metastasis in non-small cell lung cancer: accuracy of 3.0-T MR imaging. *Radiology*. 2008 Feb;246:596–604.
 21. Ohno Y, Koyama H, Yoshikawa T, Nishio M, Aoyama N, Onishi Y, et al. N stage disease in patients with non-small cell lung cancer: efficacy of quantitative and qualitative assessment with STIR turbo spin-echo imaging, diffusion-weighted MR imaging, and fluorodeoxyglucose PET/CT. *Radiology*. 2011 Nov;261:605–15.
 22. Ohno Y, Koyama H, Yoshikawa T, Takenaka D, Seki S, Yui M, et al. Three-way Comparison of Whole-Body MR, Coregistered Whole-Body FDG PET/MR, and Integrated Whole-Body FDG PET/CT Imaging: TNM and Stage Assessment Capability for Non-Small Cell Lung Cancer Patients. *Radiology*. 2015 Jun;275:849–61.
 23. Ohno Y, Koyama H, Nogami M, Takenaka D, Yoshikawa T, Yoshimura M, et al. STIR turbo SE MR imaging vs. coregistered FDG-PET/CT: quantitative and qualitative assessment of N-stage in non-small-cell lung cancer patients. *J Magn Reson Imaging JMRI*. 2007 Oct;26:1071–80.
 24. Nomori H, Mori T, Ikeda K, Kawanaka K, Shiraiishi S, Katahira K, et al. Diffusion-weighted magnetic resonance imaging can be used in place of positron emission tomography for N staging of non-small cell lung cancer with fewer false-positive results. *J Thorac Cardiovasc Surg*. 2008 Apr;135:816–22.
 25. Nakayama J, Miyasaka K, Omatsu T, Onodera Y, Terae S, Matsuno Y, et al. Metastases in mediastinal and hilar lymph nodes in patients with non-small cell lung cancer: quantitative assessment with diffusion-weighted magnetic resonance imaging and apparent diffusion coefficient. *J Comput Assist Tomogr*. 2010 Jan;34:1–8.
 26. Plathow C, Aschoff P, Lichy MP, Eschmann S, Hehr T, Brink I, et al. Positron emission tomography/computed tomography and whole-body magnetic resonance imaging in staging of advanced nonsmall cell lung cancer—initial results. *Invest Radiol*. 2008 May;43:290–7.
 27. Hasegawa I, Boisselle PM, Kuwabara K, Sawafuji M, Sugiura H. Mediastinal lymph nodes in patients with non-small cell lung cancer: preliminary experience with diffusion-weighted MR imaging. *J Thorac Imaging*. 2008 Aug;23:157–61.
 28. Morikawa M, Demura Y, Ishizaki T, Ameshima S, Miyamori I, Sasaki M, et al. The effectiveness of 18F-FDG PET/CT combined with STIR MRI for diagnosing nodal involvement in the thorax. *J Nucl Med Off Publ Soc Nucl Med*. 2009 Jan;50:81–7.
 29. Xu L, Tian J, Liu Y, Li C. Accuracy of diffusion-weighted (DW) MRI with background signal suppression (MR-DWBS) in diagnosis of mediastinal lymph node metastasis of nonsmall-cell lung cancer (NSCLC). *J Magn Reson Imaging JMRI*. 2014 Jul;40:200–5.
 30. Nomori H, Cong Y, Sugimura H, Kato Y. Diffusion-weighted imaging can correctly identify false-positive lymph nodes on positron emission tomography in non-small cell lung cancer. *Surg Today*. 2016;46:1146–51.
 31. Kim YN, Yi CA, Lee KS, Kwon OJ, Lee HY, Kim B-T, et al. A proposal for combined MRI and PET/CT interpretation criteria for preoperative nodal staging in non-small-cell lung cancer. *Eur Radiol*. 2012 Jul;22:1537–46.
 32. Sommer G, Wiese M, Winter L, Lenz C, Klarhöfer M, Forrer F, et al. Preoperative staging of non-small-cell lung cancer: comparison of whole-body diffusion-weighted magnetic resonance imaging and 18F-fluorodeoxyglucose-positron emission tomography/computed tomography. *Eur Radiol*. 2012 Dec;22:2859–67.
 33. Chen G-X, Wang M-H, Zheng T, Tang G-C, Han F-G, Tu G-J. Diffusion-weighted magnetic resonance imaging for the detection of metastatic lymph nodes in patients with lung cancer: A meta-analysis. *Mol Clin Oncol*. 2017 Mar;6:344–54.
 34. Shen G, Hu S, Deng H, Kuang A. Performance of DWI in the Nodal Characterization and Assessment of Lung Cancer: A Meta-Analysis. *AJR Am J Roentgenol*. 2016 Feb;206:283–90.
 35. Wu L-M, Xu J-R, Gu H-Y, Hua J, Chen J, Zhang W, et al. Preoperative mediastinal and hilar nodal staging with diffusion-weighted magnetic resonance imaging and fluorodeoxyglucose positron emission tomography/computed tomography in patients with non-small-cell lung cancer: which is better? *J Surg Res*. 2012 Nov;178:304–14.
 36. Krupa K, Bekiesińska-Figatowska M. Artifacts in Magnetic Resonance Imaging. *Pol J Radiol*. 2015 Feb 23;80:93–106.
 37. Schaarschmidt BM, Grueneisen J, Metznermacher M, Gomez B, Gauler T, Roessel C, et al. Thoracic staging with (18)F-FDG PET/MR in non-small cell lung cancer – does it change therapeutic decisions in comparison to (18)F-FDG PET/CT? *Eur Radiol*. 2017 Feb;27:681–8.
 38. Usuda K, Sagawa M, Motono N, Ueno M, Tanaka M, Machida Y, et al. Advantages of diffusion-weighted imaging over positron emission tomography-computed tomography in assessment of hilar and mediastinal lymph node in lung cancer. *Ann Surg Oncol*. 2013 May;20:1676–83.
 39. Meier-Schroers M, Homs R, Skowasch D, Buermann J, Zipfel M, Schild HH, et al. Lung cancer screening with MRI: results of the first screening round. *J Cancer Res Clin Oncol*. 2018 Jan;144:117–25.