

ABCA3 Deficiency in a Newborn with Respiratory Failure



Deficiencia de ABCA3 en un recién nacido con insuficiencia respiratoria

Dear Editor,

Congenital surfactant deficiencies are rare conditions, including mutation in the surfactant protein B (SP-B), surfactant protein C (SP-C) and ABCA3 (ATP-binding cassette member A3) genes. They may present with respiratory failure and pulmonary hypertension (PH) in the newborn. Long-term outcomes are different according to the mutations.

We present an infrequent case, diagnosed in a tertiary hospital, who has survived.

A term female Arabian infant was born via spontaneous vaginal delivery. Mother and father were consanguineous. Immediately after birth, the infant developed respiratory distress and was initially managed with continuous positive airway pressure.

Her physical examination was notable for bilateral coarse breath sounds and generalized thoracic retractions. Chest radiograph demonstrated diffuse bilateral granular opacities. An echocardiogram revealed no evidence of anatomic heart disease with suprasystemic levels of pulmonary artery pressure. Over the next days, her gas exchange worsened, needing intubation and mechanical ventilation. She developed progressive hypoxic respiratory failure that needed high frequency oscillatory ventilation, and nitric oxide administration.

The infant was treated with antibiotics but infectious causes for PH were ruled out with negative blood cultures. Chest computer tomography (Fig. 1) at 15 days of life showed bilateral granular opacities and ground-glass opacification; two doses of surfactant were administered without improvement. Bronchoscopic bronchoalveolar lavage detected PAS positive material. With this information, a lung biopsy through video thoracoscopy was performed. There were marked alveolar epithelial hyperplasia and mild widening of alveolar walls and the suspicion of a genetic disorder of surfactant dysfunction was considered. She still needed mechanical ventilation and take away a treatment with monthly high intravenous doses of methylprednisolone in association with oral daily hydroxychloroquine and every other day azithromycin. Genetic testing showed a nonsense mutation in ABCA3 gene, c.4681C>T or p.R1561X. This mutation was present on both maternal and paternal alleles.

At 7 months of age the infant was transferred to a pediatric lung transplant unit where she underwent bilateral lung transplantation at 10 months of age. Currently she is 2 years old needing home mechanical ventilation support because of tracheal and right main bronchus malacia.

Interstitial lung diseases (ILD) are a heterogeneous group of pathological processes that affect pulmonary parenchyma and, in most cases, lead to an impairment of gas transfer and reduction of the lung capacity. There are no reliable estimates, but prevalence is likely <1 per 100 000.¹

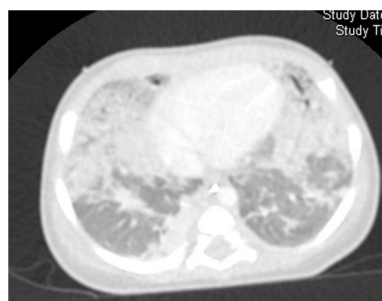


Fig. 1. CT with bilateral granular opacities and ground-glass opacification.

The definition requires at least three of the four following criteria in the absence of other known lung disorders: (1) respiratory symptoms (cough, rapid and/or difficult breathing, or exercise intolerance), (2) signs (resting tachypnea, adventitious sounds, retractions, digital clubbing, failure to thrive, or respiratory failure), (3) hypoxemia, and (4) diffuse abnormalities on chest X-ray or CT scan. Thus, establishing 3 of 4 criteria is a sensitivity method for recognizing patients that could benefit from and ILD evaluation.²

The earliest presentation of ILD is shortly after birth, with unexplained respiratory distress in a term neonate.

An organized classification scheme for ILD in children less was published by the chILD Research Network³⁻⁵ (Table 1).

Given the non-specific presentation of ILD, difficulty is frequently experienced in discerning ILD. Excluding these conditions prior to proceeding to more invasive test is important^{1,2,6}:

- **Infection screen.**
- An **echocardiography** to rule out structural cardiovascular disease and pulmonary hypertension.
- Baseline **chest X-ray.**
- Thin-**section CT** scanning. Ground glass opacification and air trapping are classical features detected.
- **Flexible bronchoscopy with BAL** to exclude infection or airway abnormalities.
- **Genetic testing.** Surfactant protein mutations produce recognizable clinical phenotypes of varying severity.
- **Lung biopsy** is the gold standard.

The gene for ABCA3 is expressed in alveolar type II cells, and the protein is localized to lamellar bodies. ABCA3 mutations have been associated with lethal neonatal respiratory distress and surfactant metabolism dysfunction. Outcomes in patients with ABCA3 mutations are variable, ranging from severe irreversible respiratory failure in early infancy to chronic static or progressive ILD.^{7,8}

There have been no controlled trials of therapeutic interventions in ILD syndrome. Case reports of improvement have been recorded with use of glucocorticoids, hydroxychloroquine, azathioprine, bronchodilators, mycophenolate, and other immune modulators.^{9,10} Lung transplantation is an option in end-stage lung disease.¹¹

Table 1
Classification for ILD in Children.

Diffuse developmental disorders	Acinar dysplasia, congenital alveolar dysplasia, alveolar-capillary dysplasia
Growth abnormalities	Pulmonary hypoplasia, structural pulmonary changes with chromosomal abnormalities
Specific conditions of undefined etiology	Pulmonary interstitial glycogenosis, neuroendocrine cell hyperplasia of infancy
Surfactant dysfunction mutations	SPFTB, SPFTC, ABCA3 genetic mutations
Disorders of the normal host	Infectious processes, environmental agents, aspiration syndromes, eosinophilic pneumonia
Disorders related to systemic disease processes	Immune-related disorders, storage disease, Langerhans cell histiocytosis
Disorders masquerading as interstitial disease	Arterial hypertensive vasculopathy, congestive vasculopathy, lymphatic disorders

The North American Children study¹² found a mortality rate of 30%, with 50% of patients experiencing on-going morbidity. It has become clear that some ILD entities are associated with very high mortality, whereas others have a favorable outcome.

References

1. Bush A, Cunningham S, Blic J, Barbato A, Clement A, Epaud R, et al. European protocols for the diagnosis and initial treatment of interstitial lung disease in children. *Thorax*. 2015;70:1078–84.
2. Kurland G, Deterding RR, Hagood JS, Young LR, Brody AS, Castile RG, et al. An official American thoracic society clinical practice guideline: classification, evaluation, and management of childhood interstitial lung disease in infancy. *Am J Respir Crit Care Med*. 2013;188:376–94.
3. Deutsch GH, Albright E, Chou PM, Cool CD, Coventry S, Davis MM, et al. Defining the spectrum of diffuse lung disease in infancy: a working classification of the pediatric interstitial lung disease cooperative. *Mod Pathol*. 2005;18:304.
4. Langston C, Dishop M. Infant lung biopsy: clarifying the pathologic spectrum. *Pathol Int*. 2004;54:S419–21.
5. Deutsch GH, Young LR, Deterding RR, Fan LL, Dell SD, Bean JA, et al., Pathology Cooperative Group. ChILD Research Co-operative Diffuse lung disease in young children: application of a novel classification scheme. *Am J Respir Crit Care Med*. 2007;176:1120–8.
6. Hines E, Walsh M, Armes J, Douglas T, Chawla J. Interstitial lung disease in infancy: a general approach. *J Paediatr Child Health*. 2016;52:370–6.
7. Doan ML, Guillerman RP, Dishop MK, Nogee LM, Langston C, Mallory GB, et al. Clinical, radiological and pathological features of ABCA3 mutations in children. *Thorax*. 2008;63:366–73.
8. Somaschini M, Nogee L, Sassi I, Danhaive O, Presi S, Boldrini R, et al. Unexplained neonatal respiratory distress due to congenital surfactant deficiency. *J Pediatr*. 2007;150:537–649.
9. Shulenin, Nogee LM, Annilo T, Wert SSE, Whitsett JA, Dean M. ABCA3 gene mutations in newborns with fatal surfactant deficiency. *N Engl J Med*. 2004;350:1296–303.
10. Bullard JE, Wert SE, Whitsett JA, Dean M, Nogee LM. ABCA3 mutations associated with pediatric interstitial lung disease. *Am J Respir Crit Care Med*. 2005;172:1026–31.
11. Moreno A, Maestre J, Balcells J, Marhuenda C, Cobos N, Roman A, et al. Lung transplantation in young infants with interstitial pneumonia. *Transpl Proc*. 2003;35:1951–3.
12. Kröner C, Wittmann T, Reu S, Teusch V, Klemme M, Rauch D, et al. Lung disease caused by ABCA3 mutations. *Thorax*. 2017;72:213–20.

M^a Carmen López Castillo,^{a,*} Estela Pérez Ruiz,^a
Pilar Caro Aguilera,^a María Adela Rodríguez Vives^b

^a Hospital Materno Infantil de Málaga, Spain

^b Facultad de Medicina de Málaga, Hospital Materno Infantil de Málaga, Spain

* Corresponding author.

E-mail address: mcarmen.lopez123@gmail.com

(M.C. López Castillo).

1579-2129/

© 2018 SEPAR. Published by Elsevier España, S.L.U. All rights reserved.

Tuberculosis and Microscopic Polyangiitis. A Rare Combination*



Tuberculosis y poliangiitis microscópica. Una asociación muy poco frecuente

To the Editor:

Tuberculosis (TB) is one of the most common causes worldwide of morbidity and mortality due to infection, with a recorded incidence in Spain in 2015 of 21.5 cases/100 000 inhabitants.¹

Vasculitis is a general term for a heterogeneous group of diseases characterized by inflammation and destruction of blood vessel walls.² Most cases are primary, but vasculitis can also be secondary to other diseases, including infections.³ At times the difference between TB and vasculitis can be difficult to determine, because they share similar characteristics, and moreover, both entities can coexist in the same patient.⁴ The definitions of vasculitis and its different forms are well established.⁵ We report the case of a patient that who presented simultaneous TB and microscopic polyangiitis (MPA).

This was a 68-year-old man with a history of TB, who attended the emergency room with a 1-month history of fever, bloody sputum, asthenia, weight loss, and dyspnea. His temperature was 38.4 °C, with no other significant findings. Blood tests were normal, and chest X-ray revealed scarring in the upper right lobe and a solid, spiculated parenchymal lesion. Chest computed tomography (CT) showed no changes in the middle and lower fields (Fig. 1A). No upper respiratory tract involvement was observed. Polymerase chain reaction was positive for *Mycobacterium tuberculosis* in bronchial aspirate and bronchoalveolar lavage. Core needle biopsy of the spiculated lesion revealed necrotizing granulomatous

inflammation with multinucleated Langhans giant cells (Fig. 1B), and positive Ziehl–Neelsen staining and polymerase chain reaction for *M. tuberculosis*. The patient developed sudden onset hemolytic anemia (hemoglobin > 6.8 g/dL, hematocrit 20.8%), acute renal failure (urea 123 mg/dL, creatinine 8.3 mg/dL), oligoanuria and elevated transaminases (values 5 times the upper limit of normal). Intubation, mechanical ventilation, and hemodialysis were required. In view of the patient's hepatic and renal insufficiency, antituberculous treatment began with ethambutol, levofloxacin, and streptomycin. Chest CT showed diffusely increased pulmonary radiodensity, mainly ground glass opacities and areas of consolidation in the peribroncovascular region, with moderate left loculated pleural effusion, with a fissural component, that was interpreted as diffuse alveolar hemorrhage (Fig. 1C). Renal biopsy revealed vasculitis with fibrinoid necrosis of the small arteries associated with focal and segmental necrotizing glomerulonephritis with an absence of immunoglobulin, complement and light chain deposits, suggestive of MPA (Fig. 1D and E). Pleural fluid was a lymphocytic exudate; ADA 45 U/L, with no other significant changes. Anti-neutrophil cytoplasmic antibodies (ANCA) (dilution 1/320; p-ANCA pattern) with anti-myeloperoxidase antibodies > 300 IU/mL were detected. Anti-glomerular basement membrane antibodies were negative. Treatment was administered with corticosteroids (3 initial boluses of methylprednisolone 500 mg/day, tapered to 15 mg/day of prednisone), plasmapheresis (7 sessions), and rituximab (700 mg/week for 4 weeks). Rifampicin and isoniazid could subsequently be reintroduced. Progress was slow but favorable, with stabilization of respiratory symptoms and radiological improvement (Fig. 1F).

The association between TB and vasculitis has been described, but generally always in association with granulomatosis with polyangiitis.^{4,6,7} As far as we know, this is the second case in which TB has been associated with MPA.⁷ Both diagnoses appear to be confirmed: positive polymerase chain reaction in 2 different samples in the case of TB; and for MPA, granulomatous inflammation with necrosis and multinucleated giant cells in lung tissue

* Please cite this article as: Riveiro V, Ricoy J, Toubes ME, Valdés L. Tuberculosis y poliangiitis microscópica. Una asociación muy poco frecuente. *Arch Bronconeumol*. 2018;54:635–637.