

cT4NxM1b¹). The patient received local palliative radiation therapy and chemotherapy with platinum/pemetrexed (Fig. 1B1 and B2). The third case was a 73-year-old man receiving active treatment guided by sensitivity testing results for documented *Mycobacterium xenopi* infection. Positron emission tomography showed a lesion measuring 40 × 25 mm with central cavitation in the left upper lobe (SUVmax 28.38) (Fig. 1C) and a hypermetabolic focus located in the left iliopsoas muscle with SUVmax 13.43, suggestive of MSM.

In all 3 cases, histological specimens were obtained for characterization, and the results were consistent with high grade undifferentiated tumor, striated muscle infiltrated with adenocarcinoma, and squamous carcinoma, respectively, all originating in the lung. The clinical progress of the patients differed: death 2 weeks after diagnosis, pain control, and reduced tumor size (Fig. 1B2) after targeted oncological treatment; clinical stabilization was achieved in the last 2 cases described.

Given the low prevalence of MSM, a detailed differential diagnosis that includes the more common malignant and benign entities (sarcomas, primary muscle lymphomas, and myxomas/hemangiomas) must be made. Although no clinical guidelines are available for the specific management of MSM, treatment is based on general oncological principles guided by clinical picture, site, and life expectancy, and approaches include observation, surgical excision (persistent solitary lesions after a period of remission), chemotherapy and radiation therapy (useful for pain control and for the reduction of tumor size).^{2–4}

The correct identification of MSM in LC patients is essential for clinical management and prognosis. For this reason, the possible neoplastic etiology of any muscle lesion, whether symptomatic or not, detected in LC patients must be evaluated with combined radiological procedures and histological confirmation of the lesion.

References

1. Sociedad Española de Oncología Médica. Las cifras del cáncer en España 2017. Available from: https://www.seom.org/seomcms/images/stories/recursos/Las_cifras_del_cancer_en_Esp.2017.pdf [accessed 06.11.17].
2. Pop D, Nadeemy AS, Venissac N, Guiraudet P, Otto P, Poudenx M, et al. Skeletal muscle metastasis from non-small cell lung cancer. *J Thorac Oncol*. 2009;4:1236–41.
3. Perisano C, Spinelli MS, Graci C, Scaramuzza L, Marzetti E, Barone C, et al. Soft tissue metastases in lung cancer: a review of the literature. *Eur Rev Med Pharmacol Sci*. 2012;16:1908–14.
4. Surov A, Hainz M, Holzhausen HJ, Arnold D, Katzer M, Schmidt J, et al. Skeletal muscle metastases: primary tumours, prevalence, and radiological features. *Eur Radiol*. 2010;20:649–58.

Blanca de Vega Sánchez,^{a,*} Ignacio Lobato Astiárraga,^a Rafael Lopez Castro,^b Maria Rosa López Pedreira,^c Carlos Disdier Vicente^{a,d}

^a Servicio de Neumología, Hospital Clínico Universitario de Valladolid, Valladolid, Spain

^b Servicio de Oncología Médica, Hospital Clínico Universitario de Valladolid, Valladolid, Spain

^c Servicio de Radiodiagnóstico, Hospital Clínico Universitario de Valladolid, Valladolid, Spain

^d Centro de Investigación en Red Enfermedades Respiratorias (CIBERES), Spain

* Corresponding author.

E-mail address: blancadevegasanchez@gmail.com (B. de Vega Sánchez).

1579-2129/

© 2017 SEPAR. Published by Elsevier España, S.L.U. All rights reserved.

Hyponatremia in COPD: A Little Known Complication[☆]



La hiponatremia en la EPOC, una complicación poco conocida

To the Editor,

Chronic obstructive pulmonary disease (COPD) is a chronic inflammatory disease, and in some patients, extrapulmonary manifestations can worsen prognosis.¹

COPD patients often have other concomitant diseases, particularly cardiovascular conditions, and it has been postulated that COPD plays a significant role in the pathogenesis of these processes.²

Hyponatremia developing during hospitalization for a COPD exacerbation is relatively common, and is associated with a poorer clinical course.³ Low sodium in blood may be a sign of water retention due to other comorbidities, such as heart or kidney failure, drug treatments, adrenal insufficiency after withdrawal of corticosteroids, or syndrome of inappropriate ADH secretion (SIADH). Diseases that may present with SIADH include lung infections (pneumonia, pulmonary abscess, tuberculosis, aspergillosis), asthma, COPD, lung tumors, cystic fibrosis, and acute respiratory

failure.⁴ Hypoxia is associated with ADH secretion,⁵ but hypercapnia is more commonly associated with this phenomenon.

Both in stable COPD and during exacerbations, hyponatremia, due to its prevalence, its impact on prognosis, and varying etiologies (which can coexist), is a challenge for the clinician and requires appropriate follow-up and treatment. Although the relationship between COPD and SIADH is often mentioned in the literature, we did not find any references to hyponatremia caused by SIADH in COPD (Medline and Pubmed searches, keywords: SIADH and COPD).

For this reason, we believe that our report of a patient with SIADH due to COPD is of interest and provides a good illustration of certain aspects of the differential diagnosis and treatment.

Our patient was an 84-year-old man, active smoker, with a history of benign prostate hypertrophy and exacerbator phenotype COPD with emphysema, and very severe obstruction (FEV1 27%), receiving treatment with silodosin, omeprazole, and glycopyrronium/indacaterol. He presented with intense dyspnea and cough with greenish expectoration. The only finding of note on physical examination was the presence of disperse rhonchi in both hemithoraxes and the absence of edema or signs of fluid overload. O₂ saturation was 89% with home oxygen therapy at 2l per minute (lpm). Clinical laboratory tests showed microcytic anemia (hemoglobin 10 g/dl), plasma sodium 111 mEq/l (normal value [NV]: 135–155 mEq/l), plasma osmolality 229 mOsm/l (NV: 280–300), PCR 64 mg/l (NV: 0–5), normal creatinine levels, urinary sodium 76 mEq/l (NV: 54–150), and urine osmolality 273 mOsm/l

[☆] Please cite this article as: Martín Guerra JM, Martín Asenjo M, Sánchez Muñoz LÁ, Dueñas Gutiérrez CJ. La hiponatremia en la EPOC, una complicación poco conocida. *Arch Bronconeumol*. 2018;54:391–393.

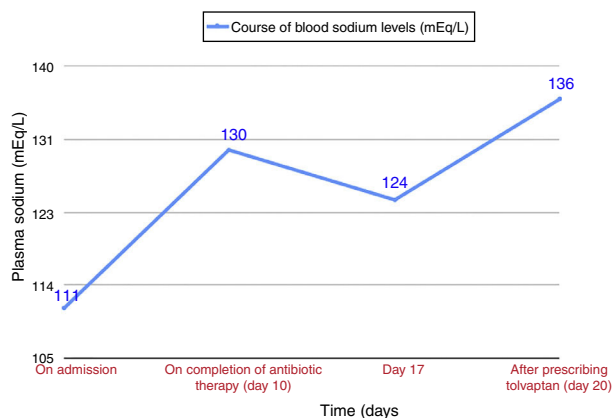


Fig. 1. Course of blood sodium levels during admission.

(NV: 30–1400); arterial blood gases with O_2 at 2 lpm: pH 7.35, pCO_2 54.8 mmHg, pO_2 57 mmHg, and HCO_3^- 29.7. Chest X-ray showed clamping of both costophrenic angles, signs of air trapping, and a slight increase in density reflecting scarring in the right lower lobe, present in previous X-rays. Given the suspected respiratory infection and the patient's history of COPD with very severe obstruction, treatment began with oxygen therapy, aerosol therapy, and beta-lactam and macrolide antibiotics. For the hyponatremia, water restriction at less than 500 cc/day was prescribed (according to the Furst formula⁶), plus diet with salt, furosemide, and hypertonic saline. The patient's sodium levels in blood did not normalize after completion of COPD treatment (Fig. 1), and no changes were observed on physical examination. Repeat clinical laboratory tests showed plasma sodium 124 mEq/l, plasma osmolality 247 mOsm/l, urine sodium 62 mEq/l, and urinary osmolality 372 mOsm/l, with normal thyroid and adrenal function. After ruling out other possible causes, a diagnosis of SIADH due to an exacerbation of emphysema phenotype COPD was given, and treatment began with tolvaptan 15 mg/24 h, leading to normalization of blood sodium in 4 days. The dose was reduced to 7.5 mg/24 h, and sodium levels in blood were normal in subsequent visits.

SIADH is characterized by the sustained release of arginine-vasopressin (ADH) in the absence of the usual stimuli, particularly hyperosmolality and hypovolemia. Diagnosis is based on hyponatremia, plasma hypoosmolality, urinary sodium >40 mmol/l, and urinary osmolality >100 mOsm/kg, after ruling out processes that involve loss of effective blood volume (heart failure, cirrhosis with ascites, etc.), and normal renal, adrenal, and thyroid function has been confirmed.⁶

Symptoms are non-specific, and can range from nausea, dizziness, general malaise, agitation and confusion to seizure or coma in cases of sudden onset or very low blood sodium levels.⁶ SIADH is the most common cause of hyponatremia, and its heterogeneous etiology⁷ includes most importantly infections, drugs, tumors⁸ (particularly small cell lung carcinoma), COPD, and asthma. Hyponatremia due to SIADH occurs quite frequently in small cell carcinoma, sometimes as a first manifestation,^{9–11} and is associated with decreased survival.¹²

Both COPD and small cell lung carcinoma are a cause of SIADH and strongly associated with smoking, so blood sodium must also be monitored in patients with COPD and a heavy accumulated consumption of tobacco.

Treatment of hyponatremia due to SIADH differs, depending on two different clinical scenarios. In acute situations with moderate/severe symptoms (sleepiness, confusion, stupor, respiratory distress), and plasma $Na^+ <120$ mEq/l, treatment should begin with 3% hypertonic saline.¹³ The initial infusion rate will be 0.5 mg/kg/h

or 1–2 ml/kg/h, depending on neurological signs.⁶ Treatment with tolvaptan (a selective vasopressin V2-receptor antagonist) may be considered, depending on progress. When SIADH develops with mild hyponatremia, water restriction and furosemide should be considered, and in patients who are not candidates for these measures or whose clinical symptoms persists, the use of tolvaptan is recommended.¹⁴

COPD exacerbation is a cause of SIADH, as demonstrated by Chanela et al.³ However, in our patient, hyponatremia persisted for almost 10 days after resolution of the infectious COPD exacerbation, and in the follow-up visit the patient continued to require tolvaptan to maintain normal sodium levels. A more typical course in SIADH due to COPD exacerbation would have been transient hyponatremia that normalized after resolution of the exacerbation.

We believe that this case of SIADH associated with a COPD exacerbation illustrates the need to include blood sodium monitoring in the management of these patients, in order to detect and reduce the morbidity and mortality of this fluid-electrolyte imbalance.¹⁵ It is also important to remember that this syndrome can, albeit rarely, be the first manifestation of lung cancer.

References

- Pauwels RA, Buist AS, Calverley PM, Jenkins CR, Hurd SS, GOLD Scientific Committee. Global strategy for the diagnosis, management, and prevention of chronic obstructive pulmonary disease. NHLBI/WHO Global Initiative for Chronic Obstructive Lung Disease (GOLD) Workshop summary. Global strategy for the diagnosis, management, and prevention of chronic obstructive pulmonary disease. NHLBI/WHO Global Initiative for Chronic Obstructive Lung Disease (GOLD) Workshop summary. *Am Respir Crit Care Med*. 2001;163:1256–76.
- Almagro Mena P, Rodríguez Carballeira M. Afectación extrapulmonar en la EPOC. ¿Qué es relevante y como debemos evaluarla? *Med Clin (Barc)*. 2011;118:23, monogr 2.
- Chalela R, González-García JG, Chillarón JJ, Valera-Hernández L, Montoya-Rangel C, Badenes D, et al. Impact of hyponatremia on mortality and morbidity in patients with COPD exacerbations. *Respir Med*. 2016;117:237–42.
- Melmed S, Polonsky KS, Larsen R, Kronenberg HM. *Tratado de endocrinología*. 13^o ed. Barcelona: Elsevier; 2016. p. 300–32.
- Kelestimir H, Leach RM, Ward JP, Forsling ML. Vasopressin and oxytocin release during prolonged environmental hypoxia in the rat. *Thorax*. 1997;52:84–8.
- Runkle I, Villabona C, Navarro A, Pose A, Formiga F, Tejedor A, et al. Tratamiento de la hiponatremia secundaria al síndrome de secreción inadecuada de la hormona antidiurética: algoritmo multidisciplinar. *Nefrología*. 2014;34:439–50.
- Catalá Bauset M, Gilsanz Peral A, Tortosa Henzi F, Zugasti Murillo A, Moreno Esteban B, Halperin Ravinovich I, et al. Guía clínica del diagnóstico y tratamiento de los trastornos de la neurohipófisis. *Endocrinol Nutr*. 2007;54:23–33.
- Adrogué HJ, Madias NE. Hyponatremia. *N Engl J Med*. 2000;342:1581–9.
- Kamoi K, Kurokawa I, Kasai H, Mizusawa A, Ebe T, Sasaki H, et al. Asymptomatic hyponatremia due to inappropriate secretion of antidiuretic hormone as the first sign of a small cell lung cancer in an elderly man. *Intern Med*. 1998;37:950–4.
- Fernández Fernández FJ, García Ribas I. Syndrome of inappropriate antidiuretic hormone secretion as the first manifestation of an occult small cell lung carcinoma. *An Med Interna*. 2002;19:599–600.
- Escribano González L, Núñez Martínez V, de Lorenzo-Cáceres Ascanio A. Mareo inespecífico como forma de presentación del síndrome de secreción inadecuada de hormona antidiurética. Formación médica continuada en atención primaria. 2008;15:116–7.
- Hansen O, Sørensen P, Hansen KH. The occurrence of hyponatremia in SCLC and the influence on prognosis: a retrospective study of 453 patients treated in a single institution in a 10-year period. *Lung Cancer*. 2010;68:111–4.
- Ayus JC, Olivera J, Frommer J. Rapid correction of severe hyponatremia with intravenous hypertonic saline solution. *Am J Med*. 1982;72:43–8.
- Verbalis JG, Alder S, Schrier RW, Berl T, Zhao Q, Czerwiec FS, SALT Investigators. Efficacy and safety of oral tolvaptan therapy in patients with the syndrome of inappropriate antidiuretic hormone secretion. *Eur J Endocrinol*. 2011;164:725–32.
- Victor RG, Haley RW, Willett DL, Peshock RM, Vaeth PC, Leonard D, et al., Dallas Heart Study Investigators. The Dallas Heart Study: a population-based probability sample for the multidisciplinary study of ethnic differences in cardiovascular health. *Am J Cardiol*. 2004;93:1473–80.

Javier Miguel Martín Guerra,* Miguel Martín Asenjo,
Luis Ángel Sánchez Muñoz, Carlos Jesús Dueñas Gutiérrez

* Corresponding author.

E-mail address: javi6vega@hotmail.com (J.M. Martín Guerra).

Servicio de Medicina Interna, Hospital Clínico Universitario de
Valladolid, Valladolid, Spain

1579-2129/

© 2018 Published by Elsevier España, S.L.U. on behalf of SEPAR.

Response to Omalizumab in a Patient With Chronic Eosinophilic Pneumonia and Poor Response to Corticosteroids[☆]



Respuesta a omalizumab en paciente con neumonía eosinófila crónica y mala respuesta al tratamiento con corticoides

To the Editor,

We report the case of a 55-year-old woman, former smoker since September 2012 (18 pack-years), with a history of allergic rhinoconjunctivitis and bronchial asthma. No infiltrates were observed in a chest X-ray performed in 2012. Skin prick tests showed sensitization to cat dander and grass and olive pollen.

She was admitted in 2014 for an acute episode of dyspnea, breath sounds, and non-productive cough without fever. Chest X-ray revealed an alveolointerstitial pattern predominantly in the lung bases. Chest computed tomography showed bilateral patchy ground glass infiltrates. Bronchoscopy was performed with trans-bronchial biopsy and bronchoalveolar lavage: neutrophils: 11%; eosinophils: 85.9%; lymphocytes: 0.6%. Biopsy showed a histological pattern of pulmonary eosinophilia suggestive of chronic eosinophilic pneumonia (CEP), with a focal pattern typical of organizing pneumonia. Lung function tests highlighted a restrictive pattern with carbon monoxide diffusion changes: FVC 1830 – 59%; FEV₁ 1410 – 54% and FEV₁/FVC 77%. DLCO 32%; KCO 63%; TLC 61%; and RV 86%. All immunological tests were negative; IgE 493 UI/ml. In the 6-min walk test, initial saturation was 97%, distance walked 440 m, and final saturation 85%.

CEP was diagnosed, with no known occupational or environmental risks, although a relationship with the administration of anti-inflammatories (celecoxib) could not be ruled out. This drug was discontinued, and treatment began with corticosteroids, resulting in both clinical and radiological worsening.

Given the poor response to treatment with corticosteroids, a surgical biopsy was performed, and the pathology study reported squamous-like interstitial pneumonia with eosinophils, consistent with CEP. The patient was placed on the lung transplantation waiting list. Lung function tests prior to the introduction of omalizumab

were: FVC 1430 – 47%; FEV₁ 1120 – 43%; FEV₁/FVC 78%; DLCO 24%; KCO 55%; TLC 44%; RV 81%.

In a review of the literature, 2 cases^{1,2} of CEP with a favorable response to omalizumab were identified, so treatment began with this drug, producing clinical improvement and functional stabilization, so we decided to gradually withdraw the corticosteroids. Twenty-four months after starting omalizumab, the patient has shown a remarkable improvement in her symptoms without corticosteroids, confirming the reversal of her previous functional decline noted from the introduction of this drug (Fig. 1). The patient was taken off the lung transplantation waiting list when the adverse effects of steroid treatment had resolved. When mepolizumab came on the market, this therapeutic option was proposed to the patient, but she refused it in view of her good progress.

CEP is an idiopathic disease characterized by an abnormal accumulation of eosinophils in the interstitial and alveolar space. Standard treatment is systemic corticosteroids. Response is usually so rapid and favorable, that if no response is observed, alternative diagnoses must be considered.

Our patient presented a poor response to high-dose corticosteroids, so a surgical biopsy was performed, which confirmed the initial diagnosis. We identified 2 cases of CEP with response to omalizumab in the literature^{1,2} involving patients with elevated IgE and poor response to corticosteroids (or a requirement for high doses). In both cases, treatment with omalizumab reversed deterioration, and produced improvements in lung function tests.

Omalizumab is a humanized anti-IgE antibody, usually indicated for the treatment of persistent allergic asthma. Numerous effects that go far beyond IgE immunomodulation have also been described.^{3–11} Omalizumab reduces basophil Fc epsilon RI alpha receptor expression.^{3–5} It also induces a decrease in triptase, Th2 cytokines (IL-4 and IL-13), and chemokines (IL-8 and RANTES), irrespective of IgE levels. Similarly, it reduces cytokine expression (IL-5, IL-10, and IL-13) in dendritic cells,^{6,7} and interferes with their ability to activate CD4. It also reduces eosinophil numbers^{8,9} in both sputum and lung tissue, monocytes,⁹ fraction of expired nitric oxide (FENO),^{9,10} and endothelin-1 concentrations in exhaled breath condensate.¹⁰ Moreover, stimulation of IgE increases the deposit of collagen I, III, and IV, and fibronectin by the Erk1/2 MAPK

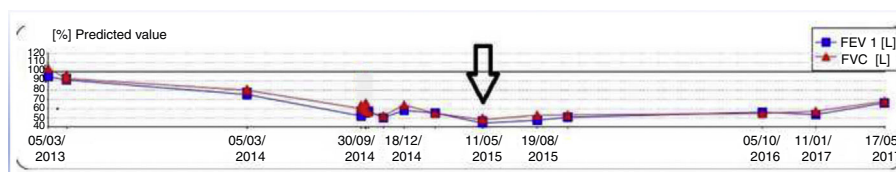


Fig. 1. Functional progress of our patient. The arrow indicates the time of starting omalizumab.

[☆] Please cite this article as: Laviña-Soriano E, Ampuero-López A, Izquierdo-Alonso JL. Respuesta a omalizumab en paciente con neumonía eosinófila crónica y mala respuesta al tratamiento con corticoides. Arch Bronconeumol. 2018;54:393–394.