

2. Drobnic F. El deportista con asma y la nueva normativa antidopaje de 2010 Menos trabajo a cambio de una terapia limitada. Arch Bronconeumol. 2010;46:280–1.
3. Boletín Oficial del Estado, Núm. 6, Sábado 7 de enero de 2017. Sec. I. pp. 766–775.
4. Available from: <https://www.wada-ama.org/en/resources/therapeutic-use-exemption-tue/medical-information-to-support-the-decisions-of-tuecs-asthma> [accessed 16.10.17].
5. Available from: <http://www.aepsad.gob.es/aepsad/control-dopaje/autorizaciones-de-uso-terapeutico.html> [accessed 16.10.17].
6. Carlsen KH, Hem E, Stensrud T, Held T, Herland K, Mowinckel P. Can asthma treatment in sports be doping? The effect of the rapid onset, long-acting inhaled beta2-agonist formoterol upon endurance performance in healthy well-trained athletes. Respir Med. 2001;95:571–6.
7. Pluim BM, de Hon O, Staal JB, Limpens J, Kuipers H, Overbeek SE, et al.  $\beta$ -Agonists and physical performance: a systematic review and meta-analysis of randomized controlled trials. Sports Med. 2011;41:39–57.
8. Drobnic F. Consideraciones sobre el informe de la prueba de broncoconstricción en el deportista. Arch Med Deporte. 1997;58:147–8.
9. Hostrup M, Kalsen A, Onslev J, Jessen S, Haase C, Habib S, et al. Mechanisms underlying enhancements in muscle force and power output during maximal cycle ergometer exercise induced by chronic  $\beta$ 2-adrenergic stimulation in men. J Appl Physiol (1985). 2015;119:475–86.
10. Ryall JG, Church JE, Lynch GS. Novel role for  $\beta$ -adrenergic signalling in skeletal muscle growth, development and regeneration. Clin Exp Pharmacol Physiol. 2010;37:397–401.
11. Krogh N, Rzeppa S, Dyreborg A, Dehnes Y, Hemmersbach P, Backer V, et al. Terbutaline accumulates in blood and urine following daily therapeutic inhalation. Med Sci Sports Exerc. 2017, <http://dx.doi.org/10.1249/MSS.0000000000001199>. PMID: 28072631 [Epub ahead of print].

Franchek Drobnic,<sup>a,b,c,\*</sup> Jesús Blanco-Alfaro<sup>d</sup>

<sup>a</sup> Departamento de Investigación en Ciencias del deporte del CAR, Sant Cugat del Vallés, Barcelona, Spain

<sup>b</sup> Servicios Médicos FC, Barcelona, Spain

<sup>c</sup> Unidad Medicina del Deporte, Hospital San Juan de Dios, Barcelona, Spain

<sup>d</sup> Departamento de Control del Dopaje, Agencia Española de Protección de la Salud en el Deporte AEPSAD, Madrid, Spain

Corresponding author.

E-mail address: [drobnic@car.edu](mailto:drobnic@car.edu) (F. Drobnic).

1579-2129/

© 2017 SEPAR. Published by Elsevier España, S.L.U. All rights reserved.

## Pulmonary Mycobacteriosis in a Patient Receiving Chronic Methotrexate Treatment<sup>☆</sup>



### Micobacteriosis pulmonar en un paciente en tratamiento crónico con metotrexato

Dear Editor,

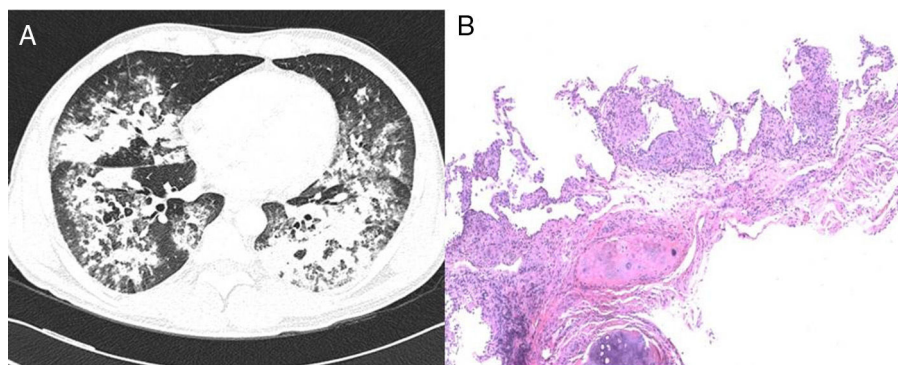
We report the case of a 42-year-old man, Dutch national, resident in Spain for 11 years. He was an active smoker with a cumulative pack-year index of 15, and no other toxic habits, and reported no use of saunas or hot tubs. He had a diagnosis of pityriasis lichenoides, treated with 7.5 mg methotrexate weekly for the previous 5 years. He attended the emergency department with a 2-week history of 38 °C fever, myalgia, cough, expectoration of mucus, and dyspnea on moderate exertion. Initial clinical laboratory results showed 11,190 leukocytes/mm<sup>3</sup> (70% neutrophils, 19% lymphocytes, 9% monocytes), C-reactive protein 11.2 mg/dl, and procalcitonin 0.56 ng/ml. Arterial blood gases were FiO<sub>2</sub> 0.24, pH 7.48, PaCO<sub>2</sub> 37 mmHg, PaO<sub>2</sub> 87 mmHg and HCO<sub>3</sub> 27 mmol/l. Chest X-ray revealed bilateral consolidations in the middle and lower fields. Urine antigen testing was negative for *Streptococcus pneumoniae* and *Legionella pneumophila* serogroup-1, and nasopharyngeal swabs for H1N1 virus, sputum smear microscopy and HIV serology were also negative. Community-acquired pneumonia with Fine score III<sup>1</sup> in an immunosuppressed patient was suspected, so antibiotic therapy with ceftriaxone and levofloxacin was started, and the patient was admitted to the respiratory medicine ward. Three days after admission, the patient's fever persisted with no clinical improvement, so the first bronchoscopy was performed, revealing a predominantly mononuclear cell count in the bronchoalveolar lavage (BAL): 58% macrophages, 60% lymphocytes, 3% neutrophils. Only adenovirus was identified by polymerase chain reaction (PCR), so cidofovir was added to the treatment. One week after hospitalization, the patient's failure to improve clinically and radiologically prompted the performance of a chest computed tomography (CT) which confirmed consolidation in both lung bases (Fig. 1A), so a second bronchoscopy was performed and a transbronchial biopsy

was obtained. Tests for anti-nuclear and anti-neutrophil cytoplasmic antibodies, rheumatoid and angiotensin-converting enzymes were all negative. Two days later, the patient presented clinical worsening with progressive consolidation and high oxygen requirements (PaO<sub>2</sub>/FiO<sub>2</sub>: 97 mmHg), so he was transferred to the Intensive Care Unit for monitoring and administration of high-flow oxygen therapy. Standard cultures of both bronchial aspirate and BAL grew saprophytic flora, and the sputum smear, galactomannan and study of viruses and parasites were all negative. BAL cytology showed persistent predominance of mononuclear cells. Transbronchial biopsy revealed non-necrotizing granulomas (Fig. 1B). Mycobacterial infection was suspected, although other etiologies such as sarcoidosis or pneumonitis associated with methotrexate could not be ruled out. Standard anti-tuberculosis treatment and methylprednisolone (1 mg/kg/day) were started. PCR testing (Real-Cycler TBM, Molecular Progeny) for *Mycobacterium tuberculosis* detection in BAL and the biopsy specimen was requested, both of which were negative. Having ruled out tuberculosis, a PCR was performed for non-tuberculous mycobacteria (NTM) (INNO-LIPA *Mycobacteria* v2, Innogenetics) on the first BAL sample, in which *Mycobacterium intracellulare* (*M. intracellulare*) and *Mycobacterium simiae* (*M. simiae*) were identified. Treatment was switched to rifampicin, ethambutol, azithromycin, and moxifloxacin, and rapid tapering of the corticosteroids began. Clinical and radiological improvement was observed, with oxygen saturation of 94% breathing room air at discharge. No microbiological confirmation was obtained from mycobacterial cultures in any of the respiratory samples tested. The patient continued treatment for 1 year, and remained asymptomatic with practically complete resolution of radiological changes.

The worldwide incidence and prevalence of pulmonary disease caused by NTM is increasing. It affects both immunosuppressed and immunocompetent individuals<sup>2</sup>; in our case, a patient receiving chronic treatment with methotrexate.

With regard to the mycobacteria identified in our patient, *M. simiae* is rarely associated with lung disease, suggesting that its isolation is due to environmental contamination.<sup>3</sup> Indeed, pseudo-outbreaks caused by contaminated hot water supplies have been reported.<sup>4</sup> Most cases have been described in the southern United States, Cuba, and Israel.<sup>3–5</sup> Affected patients are primarily elderly immuno competent individuals with underlying lung disease, but disseminated infection can also occur in patients

<sup>☆</sup> Please cite this article as: Dal Molín-Veglia MA, Sánchez-Martínez F, Fernández-Alarza AF, Domínguez-Álvarez M. Micobacteriosis pulmonar en un paciente en tratamiento crónico con metotrexato. Arch Bronconeumol. 2018;54:225–226.



**Fig. 1.** (A) Chest CT: pulmonary consolidations in middle lobe, lingula, and both lower lobes. (B) Transbronchial biopsy of the right lung base: evidence of non-necrotizing granulomatous pneumonitis (hematoxylin-eosin staining, 4×).

with advanced HIV infection (Aids).<sup>6</sup> Treatment is complicated by the lack of correlation between *in vitro* susceptibility and the *in vivo* response, but must include clarithromycin in combination with other antimicrobials, such as fluoroquinolones and cotrimoxazole.<sup>3,6</sup> *M. intracellulare*, on the other hand, is included in the *Mycobacterium avium* (*M. avium*) complex. This species, unlike *M. avium*, is isolated more frequently in patients without HIV infection and presents with two main radiological patterns: fibrocavitary disease and nodular bronchiectasis.<sup>3</sup> Cases have been reported in the United States, Japan, Europe, and South Africa.<sup>7</sup> It is resistant to chlorine and survives at high temperatures, so hot tubs or jacuzzis are associated with outbreaks.<sup>8</sup> Treatment must include a macrolide, rifampicin, ethambutol, and, if cavitary or disseminated lesions are observed, an injectable aminoglycoside during the induction phase is required.<sup>3</sup>

Methotrexate has anti-proliferative and immunosuppressive activity, and is one of the therapeutic options for the treatment of pityriasis lichenoides.<sup>9</sup> Chronic use can lead to immune changes that predispose to opportunistic infections.<sup>10–12</sup>

This is the first report in the literature of mycobacterial infection caused by *M. simiae* and *M. intracellulare* during chronic treatment with methotrexate. Our patient met the ATS/IDSA criteria<sup>3</sup> for the diagnosis of pulmonary disease caused by NTM, guided by the finding of granulomatous lesions in the biopsy and identification by molecular techniques. The patient also improved clinically and radiologically with treatment targeted at both microorganisms. However, the pathogenic role of *M. simiae* may be questionable, since previous studies have suggested that only 20% of isolates in respiratory samples are clinically relevant.<sup>13</sup> We cannot determine the influence that the initial treatment, including levofloxacin, may have had on the failure to grow *M. simiae* and *M. intracellulare* in the mycobacterial cultures, and the molecular biology techniques were objectively more sensitive for diagnosis.

In conclusion, NTM infections should be considered in the differential diagnosis of pneumonia in patients receiving immunosuppressive therapy.

## Acknowledgements

We thank Dr. Lara Pijuan of the Pathology Department of the Hospital del Mar and Dr. Ana C. Siverio Parés of Microbiology Reference Laboratory of Catalonia.

## References

1. Fine MJ, Auble TE, Yealy DM, Hanusa BH, Weissfeld LA, Singer DE, et al. A prediction rule to identify low-risk patients with community-acquired pneumonia. *N Engl J Med.* 1997;336:243–50.
2. Kendall BA, Winthrop KL. Update on the epidemiology of pulmonary nontuberculous mycobacterial infections. *Semin Respir Crit Care Med.* 2013;34:87–94.
3. Griffith DE, Aksamit T, Brown-Elliott BA, Catanzaro A, Daley C, Gordin F, et al. An official ATS/IDSA statement: diagnosis, treatment, and prevention of nontuberculous mycobacterial diseases. *Am J Respir Crit Care Med.* 2007;175:367–416.
4. Hana M, Sahly EL, Septimus E, Hanna S, Septimus J, Wallace RJ, et al. *Mycobacterium simiae* pseudo-outbreak resulting from a contaminated hospital water supply in Houston Texas. *Clin Infect Dis.* 2002;35:802–7.
5. Hummer D, Dux S, Samra Z, Kaufman L, Lavy A, Block CS, et al. *Mycobacterium simiae* infection in Israeli patients with AIDS. *Clin Infect Dis.* 1993;17:508–9.
6. Maoz C, Shitrit D, Samra Z, Peled N, Kaufman L, Kramer MR, et al. Pulmonary *Mycobacterium simiae* infection: comparison with pulmonary tuberculosis. *Eur J Clin Microbiol Infect Dis.* 2008;27:945–50.
7. Inderlied CB, Kemper CA, Bermúdez LE. The *Mycobacterium avium* complex. *Clin Microbiol Rev.* 1993;6:266–310.
8. Surgita Y, Ishii N, Katsuno M, Yamada R, Nakajima H. Familial cluster of cutaneous *Mycobacterium avium* infection resulting from use of a circulating, constantly heated bath water system. *Br J Dermatol.* 2000;142:789–93.
9. Khachemoune A, Blyumin M. Pityriasis lichenoides pathophysiology, classification and treatment. *Am J Clin Dermatol.* 2007;8:29–36.
10. Likuni N, Kitahama M, Ohta S, Okamoto H, Kamatani N, Nishinarita M. Evaluation of *Pneumocystis pneumonia* infection risk factors in patients with connective tissue disease. *Mod Rheumatol.* 2006;16:282–8.
11. Vadillo Font C, Hernández-García C, Pato E, Morado IC, Salido M, Júdez E, et al. Incidence and characteristics of tuberculosis in patients with autoimmune rheumatic diseases. *Rev Clin Esp.* 2003;203:178–82.
12. Park JS, Jung ES, Choi W, Park SY, Rim MY, Yu I, et al. *Mycobacterium intracellulare* pulmonary disease with endobronchial caseation in a patient treated with methotrexate. *Tuberc Respir Dis.* 2013;75:28–31.
13. Van Ingen J, Boeree MJ, Dekhuijzen PN, van Soolingen D. Clinical relevance of *Mycobacterium simiae* in pulmonary samples. *Eur Respir J.* 2008;31:106–9.

María Agustina Dal Molín-Veglia,<sup>a,b,c</sup>

Francisca Sánchez-Martínez,<sup>a,b,c,d,f</sup>

Antonio Fernando Fernández-Alarza,<sup>b,e</sup>

Marisol Domínguez-Álvarez<sup>b,c,f,g,\*</sup>

<sup>a</sup> Servicios de Medicina Interna y Enfermedades Infecciosas, Hospital del Mar, Barcelona, Spain

<sup>b</sup> Institut Hospital del Mar d'Investigacions Mèdiques (IMIM), Barcelona, Spain

<sup>c</sup> Universidad Autónoma de Barcelona (UAB), Barcelona, Spain

<sup>d</sup> Grupo de Estudio de las Infecciones por Micobacterias (GEIM) de la Sociedad Española de Enfermedades Infecciosas (SEIMC), Spain

<sup>e</sup> Servicio de Radiología, Hospital del Mar, Barcelona, Spain

<sup>f</sup> Servicio de Neumología, Hospital del Mar, Barcelona, Spain

<sup>g</sup> Centro de Investigación en red de Enfermedades Respiratorias (CIBERES), Instituto de Salud Carlos III (ISC III), Barcelona, Spain

\* Corresponding author.

E-mail address: 94422@parcdesalutmar.cat

(M. Domínguez-Álvarez).

1579-2129/

© 2017 SEPAR. Published by Elsevier España, S.L.U. All rights reserved.