

Bronchocentric Granulomatosis in an Immunocompetent Patient



Granulomatosis broncocéntrica en un paciente inmunocompetente

Dear Director,

Aspergillus tracheobronchitis comprises less than 7% of pulmonary aspergillosis cases.¹ It occurs most frequently in immunocompromised hosts and rarely in immunocompetent individuals. The clinical manifestations of this infection are usually nonspecific, and include cough, exertional dyspnoea, white or purulent sputum, fever and wheezing.¹

A 54-year-old female who had been suffering from allergic symptoms (sneezing, red eye, rhinitis, unproductive cough, chest discomfort and dyspnoea) for 6 months was admitted to our hospital. Inhaled steroids and antibiotic therapy were initiated due to suspicion of asthma and community-acquired pneumonia; however, her symptoms worsened. To identify the underlying pathology, thorax computed tomography (CT) was performed, and plaques in the trachea and main bronchus were detected (Fig. 1A). A rigid bronchoscopy was planned to ensure a patent airway and evaluate the bronchial system because of her respiratory symptoms and the diffuse plaques and airway obstruction observed on thorax CT. Mucoïd impaction and numerous gelatinous whitish plaques along the trachea and the right and left main bronchi were observed (Fig. 1B). Pathological evaluation of the biopsy material taken from the main bronchi and trachea revealed chronic inflammation and fungal hyphae. A fungal culture yielded no growth. Although the

pathology was not confirmed, we made a presumptive diagnosis of bronchocentric granulomatosis and *Aspergillus* tracheobronchitis based on her symptoms, discriminative bronchoscopic findings and unresponsiveness to antibiotics. Differential diagnosis was performed as the pathology was negative for cancer, lavage was negative for *Mycobacterium tuberculosis* and serum was negative for anti-neutrophilic cytoplasmic antibodies (ANCA). The patient was started on oral prednisolone due to her respiratory symptoms and tracheal lesions. Prednisolone was tapered after 7 days as the cough and dyspnoea had resolved. Galactomannan levels were measured twice at a 1-week interval, and were 0.21 and 0.29 ng/ml; these are lower than the 0.5 ng/ml reference value and so were accepted as negative. None of the specimens obtained yielded fungal growth. After 1 month of treatment, surveillance bronchoscopic examination revealed significant improvement in the gelatinous whitish plaques in the trachea and main bronchi (Fig. 1C). At the beginning of the treatment, her respiratory function was as follows: FEV1 1.15 (51.8%), FVC 1.87 (71.6%) and FEV1/FVC 59%. These values improved after treatment to FEV1 1.85 (84%), FVC 2.40 (83.8%) and FEV1/FVC 76.2%. Prednisolone was stopped and the patient has been followed up for 1 year without treatment.

By definition, bronchocentric granulomatosis is an abnormal cell-mediated response to *Aspergillus*. A diagnosis of tracheobronchial aspergillosis can be made when tissue histopathology shows hyphae, with or without a positive culture for *Aspergillus* from the same site. *Aspergillus* hyphae are identified in 40%–50% of cases.² *Aspergillus* tracheobronchitis is diagnosed by one of the following: histologic evidence of tissue invasion by *Aspergillus* in a biopsy, histology suggestive of aspergillosis associated with positive culture of *Aspergillus*, clinical and radiological findings strongly

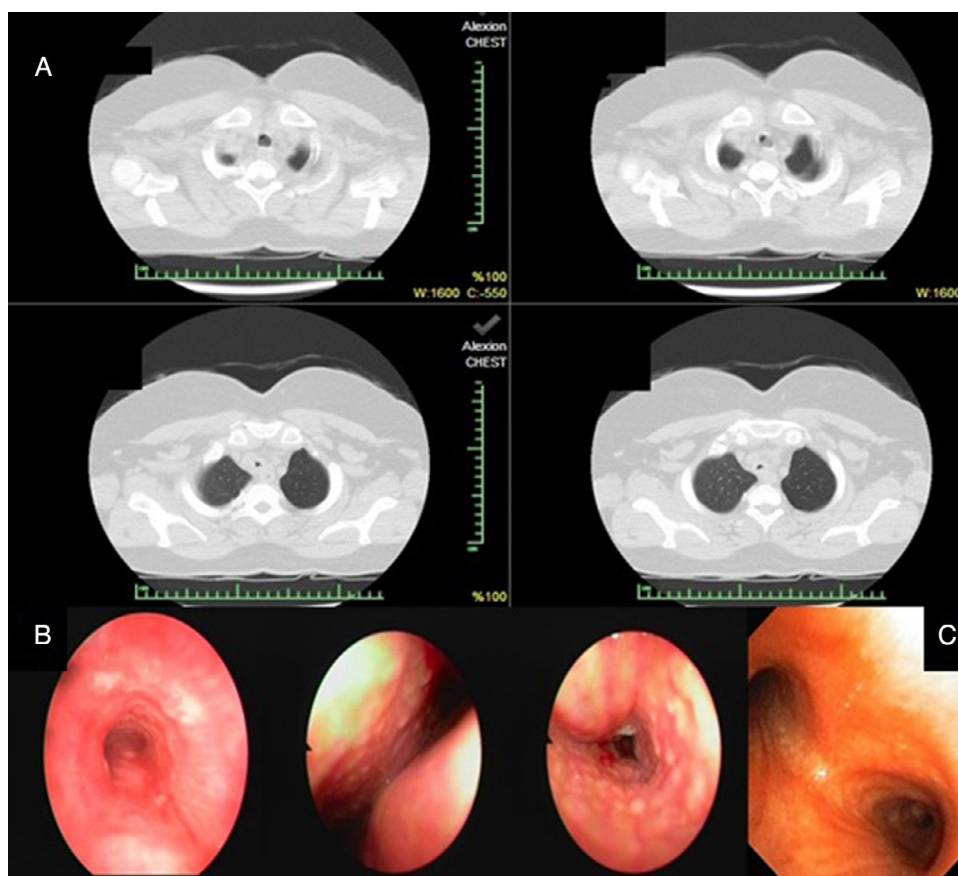


Fig. 1. (A) Plaques in the trachea by thorax computed tomography. (B) Mucoïd impaction and gelatinous whitish plaques along the trachea and the right and left main bronchus were observed by rigid bronchoscopy. (C) Surveillance bronchoscopic examination revealed a significant improvement in symptoms.

suggestive of aspergillosis associated with microbiologic identification in lavage fluid, or a positive galactomannan serum assay.¹ A background inquiry revealed that the patient had moved to a new house and received a large quantity of flowers before the onset of her symptoms. Because the patient was not immunocompromised, a diagnosis of fungal tracheobronchitis was not initially considered; this delayed the diagnosis by 6 months, which is in agreement with the literature.³ In immunocompetent patients, we consider *Aspergillus* tracheobronchitis in the presence of numerous gelatinous whitish plaques in the trachea and right and left bronchi. In this case, the earliest indication of an *Aspergillus* infection was mucoid impaction along the bronchus. Although hyphae were seen in the biopsy, fungal cultures of sputum and respiratory secretions were negative, and no galactomannan positivity was identified. Mucoid impaction and bronchocentric granulomatosis are seen in half of ABPA cases.⁴ After failing to identify an alternative cause, we interpreted bronchocentric granulomatosis in this patient as a histopathologic manifestation of fungal hypersensitivity.⁴

Cases of bronchocentric granulomatosis are classified according to the clinical presentation. The first subtype includes asthma and atopy, while the second subtype is idiopathic; some case reports suggest an association with other underlying diseases such as bronchogenic carcinoma, post-radiation pulmonary fibrosis, rheumatoid arthritis, and granulomatosis with polyangiitis.⁴ Patients with the first subtype tend to be younger (20–40 years), while non-asthmatic subtypes tend to be older (30–70 years). In our case, atopy was the only co-morbidity.⁴ Corticosteroids are effective mainly in patients with asthma and atopy.^{5,6} Corticosteroid therapy was effective in our patient, and resolved all symptoms.

In conclusion, bronchocentric granulomatosis caused by *Aspergillus* tracheobronchitis should be considered in immunocompetent patients with tracheobronchial infiltrates on CT scan who do not respond to inhaled steroids or broad-spectrum antibiotics.

Our patient yielded negative cultures and normal galactomannan values, but tracheal involvement was suggestive of *Aspergillosis* tracheobronchitis, and hyphae without tissue or vascular invasion were identified in a biopsy. Therefore, recovery of fungal hyphae in a biopsy specimen from an immunocompetent patient with atypical respiratory symptoms and CT findings should not be dismissed as contamination.

References

1. Krenke R, Grabczak EM. Tracheobronchial manifestations of *Aspergillus* infections. *Scientific World J.* 2011;11:2310–29.
2. Soubani AO, Chandrasekar PH. The clinical spectrum of pulmonary aspergillosis. *Chest.* 2002;121:1988–99.
3. Clancy CJ, Nguyen MH. Acute community acquired pneumonia due to aspergillus in presumably immunocompetent hosts: clues for recognition of a rare but fatal disease. *Chest.* 1998;114:629–34.
4. Patel N, Saleh A, Raoof S, Gudi M, George L, Prakash UBS. Tracheobronchial manifestations of aspergillosis. *J Bronchol.* 2010;17:45–53.
5. Li H, He J, Gu Y, Zhong N. Corticosteroid monotherapy in a case of bronchocentric granulomatosis with a two-year follow-up. *J Thorac Dis.* 2013;5:E207.
6. Umezawa H, Naito Y, Ogasawara T, Takeuchi T, Kasamatsu N, Hashizume I. Idiopathic bronchocentric granulomatosis in an asthmatic adolescent. *Respir Med Case Rep.* 2015;16:134–6. <http://dx.doi.org/10.1016/j.rmcr.2015.09.010>, eCollection 2015.

Cengiz Özdemir, Sinem Nedime Sökücü*

Yedikule Chest Disease and Thoracic Surgery Training and Research Hospital, Istanbul, Turkey

Corresponding author.

E-mail address: sinemtimur@yahoo.com (S.N. Sökücü).

1579-2129/

© 2017 SEPAR. Published by Elsevier España, S.L.U. All rights reserved.

Pulmonary Thromboembolism as a First Manifestation of Atrial Myxoma[☆]



Tromboembolismo pulmonar como primera manifestación de un mixoma auricular

To the Editor,

Atrial myxomas are the most common benign primary cardiac tumors. They occur preferentially in the left atrium and clinical manifestations can be varied, with asthenia, anorexia, and weight loss due to intracavitary flow obstruction in the mitral valve and systemic embolisms; however, only exceptionally do they cause pulmonary thrombosis.^{1–3}

A 47-year-old woman, smoker of 20 pack-years, with no other history of interest, was admitted to the respiratory medicine department with a 4-month history of dyspnea on moderate exertion, general malaise, asthenia, right pleuritic pain, and polyarthralgia. She had also had fever and mild hemoptysis in the previous 4 days. Physical examination showed basal oxygen saturation 94%, heart rate 103 bpm, BP 107/73 mmHg, with signs of pleural effusion on auscultation. Of note on clinical laboratory tests were elevated CRP (95.7 mg/l) and 18 500 leukocytes/mm³ with neutrophilia. Chest X-ray showed consolidation in the left

lower lobe with associated pleural effusion. Blood cultures, sputum microbiology, and antigen detection in urine were negative for pneumococcus and *Legionella*. Diagnostic thoracentesis was performed and was compatible with uncomplicated neutrophilic exudate. Cytology for malignant cells and microbiological cultures were negative. Despite starting empirical wide-spectrum antibiotic treatment, the patient's clinical, hemodynamic, and radiological situation worsened, with increased work of breathing, tendency to hypotension, and mildly altered level of consciousness. An angio-CT was performed, which revealed bilateral pulmonary thromboembolism (PTE), a filling defect in the left atrium, and multiple bilateral opacities consistent with pulmonary infarcts. Eco-Doppler of the lower limbs ruled out deep vein thrombosis (DVT).

On echocardiography, a large mass was observed in the left atrium (6.3×3.2 cm) that protruded in diastole toward the left ventricle, obstructing the outflow. Signs of severe pulmonary hypertension were also seen, with pulmonary artery systolic pressure 85 mmHg, and estimated left ventricular ejection fraction 60% (Fig. 1).

In view of the severity of the clinical picture and hemodynamic instability, the patient was transferred to the Intensive Care Unit. She subsequently worsened significantly, and the cardiovascular surgery department was contacted for removal of the intracardiac tumor. The pathology report of the surgical specimen confirmed a diagnosis of atrial myxoma. After surgery and anticoagulant treatment, clinical progress was very satisfactory; in a follow-up echocardiography, the pulmonary hypertension had resolved and the pulmonary angio-CT showed resolution of the intravascular

[☆] Please cite this article as: Climent M, Furest I, Moragón EM. Tromboembolismo pulmonar como primera manifestación de un mixoma auricular. *Arch Bronconeumol.* 2018;54:46–47.