

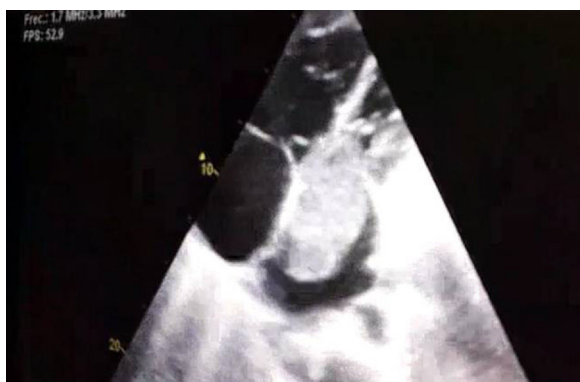

Fig. 1. Echocardiography showing a large mass in the left atrium (6.3×3.2 cm) in diastole protruding into the left ventricle.

clots. A thrombophilia study was also requested, and the patient was found to be a heterozygous carrier of the factor V Leiden mutation.

A myxoma is a benign cardiac tumor; however, its benign nature is relative, since it sometimes produces distant metastases and paraneoplastic syndromes caused by cytokines and growth factors produced by the tumor.^{4,5} Clinical presentation depends on size and location, and it can cause intracardiac flow obstruction, stenosis, and mitral regurgitation in the left cavities.⁵ Echocardiography is the diagnostic test of choice, and the curative treatment is surgical resection. Being a carrier of factor V Leiden mutation is not in itself an independent risk factor for the development of PTE, but rather an additional factor along with others that confer moderate or high risk.

The presence of systemic embolisms has been frequently noted in reviews of atrial myxoma. Our case is exceptional in that the myxoma manifested as PTE without associated DVT. We believe that this may be the consequence of various concomitant risk factors: hypercoagulability derived from the myxoma, thrombophilia, concomitant infection, and obstruction of the blood flow by the tumor which may promote the presence of “in situ” thrombi in the pulmonary circulation.

References

1. He DK, Zhang YF, Ye SX, Wang C, Kang B, Liang Y, et al. Risk factors for embolism in cardiac myxoma: a retrospective analysis. *Med Sci Monit.* 2015;21:1146–54.
2. García Zubiri C, Yebra Yebra M, Salas Antón C, García Madero R, Manzano Espinosa L, Yebra Bango M. Mixoma cardíaco: serie de 30 pacientes. *Rev Clin Esp.* 2009;209:478–82.
3. Gabe ED, Rodríguez Correa C, Vigliano C, San Martino J, Wisner JN, González P, et al. Mixomas cardíacos: correlación anatomoclínica. *Rev Esp Cardiol.* 2002;55:505–13.
4. Cobo Gómez N, Romero Reyes MJ, Mera Romero M, Pastor Torres LF. Mixoma auricular izquierdo y tromboembolia pulmonar. ¿Síndrome paraneoplásico? *Cardiocyte.* 2014;49:125–7.
5. Smith M, Chaudhry MA, Lozano P, Humphrey MB. Cardiac myxoma induced paraneoplastic syndromes: a review of the literature. *Eur J Intern Med.* 2012;23:669–73.

Maria Climent,* Ildefonso Furest, Eva Martínez Moragón

Neumología, Hospital Universitario Doctor Peset, Valencia, Spain

Corresponding author.

E-mail address: macligre@hotmail.com (M. Climent).

1579-2129/

© 2017 SEPAR. Published by Elsevier España, S.L.U. All rights reserved.

Pneumothorax due to Radiofrequency Ablation for Post-Herpetic Neuralgia[☆]



Neumotórax secundario a ablación por radiofrecuencia de neuralgia postherpética

To the Editor,

Postherpetic neuralgia is the most common late complication of herpes zoster, and occurs in 9%–19% of patients.¹ It is caused by nerve damage in the area affected by the virus and is defined as persistent pain longer than 3 months after resolution of the characteristic vesicular rash.^{2–4} The main clinical problem is persistent pain that interferes with the patient's daily activities. The chest region (dermatomes T1 to T12) is the area most commonly affected by postherpetic neuralgia, with an incidence of up to 50%.⁵ Various treatments have been proposed,^{6–10} including drugs, botulinum toxin injections, nerve blocks, peripheral nerve stimulation, surgical intervention, pulsed radiofrequency treatment, and radiofrequency ablation.¹¹

Given the scarcity of published scientific evidence for iatrogenic pneumothorax following the use of conventional radiofrequency, we present the case of a 62-year-old woman, with no toxic habits, diagnosed with fibromyalgia and osteoporosis, who developed pos-

therpetic neuralgia as a late complication of thoracic herpes zoster infection in 2011. She had been monitored by the pain unit since 2012, and had received several treatments without success, including nerve block with local anesthetics and steroids in 2015. In April 2016, she began treatment with conventional intercostal radiofrequency, involving stimulation of the painful area above the right 9th intercostal space at 80° for 90 s, without complications. A second incident-free radiofrequency session was conducted 12 weeks later, followed in December by a third conventional radiofrequency session at the 5th intercostal space. During this last session, the patient developed dyspnea, tachycardia 110 bpm, and hypotension, so an emergency chest X-ray was performed, showing right pneumothorax (Fig. 1). A chest tube was placed, after which complete reexpansion of the right lung was observed. The patient was discharged from the pulmonology department 48 h after the procedure with no complications.

Postherpetic neuralgia generally responds to drug therapy, and this should be used before any other intervention is attempted. Refractory cases can be treated with minimally invasive, though not entirely risk-free procedures such as nerve block, after which 0.09% of patients develop pneumothorax, a figure that rises to 0.42% if all patients are routinely given a chest X-ray.¹² However, pneumothorax is not a common complication of radiofrequency techniques: no events were reported in larger series of up to 96 patients undergoing this treatment for postherpetic neuralgia.⁹

Radiofrequency is a minimally invasive intervention for the management of chronic pain, and its use in chronic pain units has been increasing in recent years.

[☆] Please cite this article as: Cabrera César E, Fernández Aguirre MC, Vera Sánchez MC, Velasco Garrido JL. Neumotórax secundario a ablación por radiofrecuencia de neuralgia postherpética. *Arch Bronconeumol.* 2018;54:47–48.

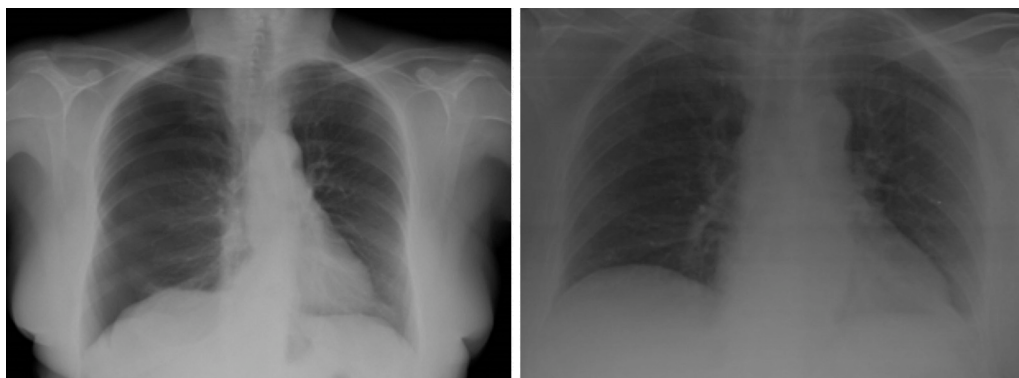


Fig. 1. Left: pneumothorax in right hemithorax. Right: pneumothorax resolved after chronic drainage.

The thoracic location of postherpetic neuralgia, in most cases, and the emergence of new techniques for pain control can lead to complications not initially considered, such as the case of our patient who presented pneumothorax in a healthy lung. The management of these cases begins with clinical suspicion, particularly in patients with risk factors. Treatment depends on the size of the pneumothorax. In the case of our patient, inter-procedural hemodynamic changes required urgent placement of a chest tube.

Despite their low incidence, facilities for the diagnosis and treatment of these complications must be available in these units, in the event that they do occur.

References

- Opstelten W, Mauritz JW, de Wit NJ, van Wijck AJM, Stalman WAB, van Essen GA. Herpes zoster and postherpetic neuralgia: Incidence and risk indicators using a general practice research database. *Fam Pract.* 2002;19:471–5.
- Helgason S, Peturson G. Prevalence of postherpetic neuralgia after a first episode of herpes zoster: prospective study with long term follow up. *BMJ.* 2000;321:794–6.
- Sampathkumar P, Drage LA, Martin DP. Herpes zoster (shingles) and postherpetic neuralgia. *Mayo Clin Proc.* 2009;84:274–80.
- Fields HL, Rowbotham M, Baron R. Postherpetic neuralgia: irritable nociceptors and deafferentation. *Neurobiol Dis.* 1998;5:209–27.
- Mondelli M, Romano C, Della Porta P, Rossi A. Electrophysiological findings in peripheral fibres of subjects with and without post-herpetic neuralgia. *Electroencephalogr Clin Neurophysiol.* 1996;101:185–91.
- Schmid T, Pautex S, Lang PO. Acute and postherpetic neuralgia in the elderly: analysis of evidence for therapeutic options. *Rev Med Suisse.* 2012;8:1374–8, 1380–2.
- Khadem T, Stevens V. Therapeutic options for the treatment of postherpetic neuralgia: a systematic review. *J Pain Palliat Care Pharmacother.* 2013;27:268–83.
- Goßrau G. Postherpetic neuralgia. *Hautarzt.* 2014;65:461–70.
- Ke M, Yinghui F, Yi J, Xuehua H, Xiaoming L, Zhijun C, et al. Efficacy of pulsed radiofrequency in the treatment of thoracic postherpetic neuralgia from the angulus costae: a randomized, double-blinded, controlled trial. *Pain Phys.* 2013;16:15–25.
- Bonezzi C, Demartini L. Treatment options in postherpetic neuralgia. *Acta Neurol Scand Suppl.* 1999;173:25–35, discusión 48–52.
- Rahman M, Richter EO, Osawa S, Rhoton AL Jr. Anatomic study of the infraorbital foramen for radiofrequency neurotomy of the infraorbital nerve. *Neurosurgery.* 2009;64:423–7.
- Moore DC, Bridenbaugh DL. Pneumothorax: its incidence following intercostal nerve block. *JAMA.* 1962;182:1005–8.

Eva Cabrera César,* M^a Carmen Fernández Aguirre,
M^a Carmen Vera Sánchez, Jose Luis Velasco Garrido

Servicio de Neumología, Hospital Universitario Virgen de la Victoria, Málaga, Spain

* Corresponding author.

E-mail address: evacabrerasesar@gmail.com (E. Cabrera César).

1579-2129/

© 2017 SEPAR. Published by Elsevier España, S.L.U. All rights reserved.

Effect of Isoniazid Resistance on the Tuberculosis Treatment Outcome



Efecto de la resistencia a la isoniazida en el resultado del tratamiento de la tuberculosis

Dear Director,

Tuberculosis (TB) remains a serious public health problem, and about one-third of world's population has active or latent TB. In Europe, there are 49 new cases and 7 deaths from TB every hour.¹ In Portugal, the incidence has been decreasing in recent years, and in 2014 the annual incidence was 20/1,00,000.²

Drug-resistant *Mycobacterium tuberculosis* has become a major threat to the control of TB and, among all first-line drugs, resistance is greatest to isoniazid (INH).^{3,4} In Portugal, INH resistance was 10.5% in 2014 among TB cases in whom susceptibility testing was performed.² In fact, there has been an increasing resistance to INH, despite the decreasing number of TB cases.²

INH is a first-line anti-TB drug because of its potent early bactericidal activity against rapidly dividing cells.^{3,5} However, treatment of active TB requires multiple anti-TB drugs along with INH to prevent selection and emergence of a drug-resistant population of *M. tuberculosis*. According to current World Health Organization (WHO) recommendations, INH mono-resistant TB should be treated with 6–9 months of rifampicin, ethambutol, and pyrazinamide, plus or minus a fluoroquinolone.⁶ These are also the current treatment guidelines in Portugal.

TB is a notifiable disease in Portugal, so clinicians report all cases to National-Tuberculosis-Surveillance-System (SVIG-TB) that has data on patient demographics, comorbidities, risk behaviors, and clinical, radiological, and microbiological information, as well as treatment outcomes.⁷

The objectives of this study were identify factors associated with INH mono-resistance, compare treatment outcomes of INH mono-resistant patients with drug-susceptible patients and understand the causes of unsuccessful treatment among INH mono-resistance TB cases.