

## Authorship

All the authors have contributed equally to the conception and drafting of this manuscript and are responsible for its content.

## References

1. Pérez Warnisher MT, Cabezas Pastor E, Seijo LM. Diagnóstico precoz del cáncer de pulmón. El futuro del cribado. Clínicas Respiratorias SEPAR. Monografía N.º 4 Cáncer de pulmón. Coordinador: Matilla González JM. Editorial Respira; Barcelona; 2016. p. 13–24.
2. Aberle DR, Adams AM, Berg CD, Black WC, Clapp JD, Fagerstrom RM, et al., National Lung Screening Trial Research Team. Reduced lung-cancer mortality with low-dose computed tomographic screening. *N Engl J Med.* 2011;365:395–409.
3. McCunney RJ, Li J. Radiation risks in lung cancer screening programs. *Chest.* 2014;145:618–24.
4. Patz EF Jr, Greco E, Gatsonis C, Pinsky P, Kramer BS, Aberle DR. Lung cancer incidence and mortality in National Lung Screening Trial participants who underwent low-dose CT prevalence screening: a retrospective cohort analysis of a randomised, multicentre, diagnostic screening trial. *Lancet Oncol.* 2016;17:590–9.
5. Ruano-Ravina A, Provencio-Pulla M, Casan Clarà P. Cribado de cáncer de pulmón con tomografía computarizada de baja dosis. Reflexiones sobre su aplicación en España. *Med Clin (Barc).* 2016;147:366–70.

Alberto Ruano-Ravina,<sup>a,b</sup> Mariano Provencio-Pulla,<sup>c,d</sup>  
Pere Casan Clarà<sup>e,f,\*</sup>

<sup>a</sup> Área de Medicina Preventiva y Salud Pública, Universidad de Santiago de Compostela, Santiago de Compostela, La Coruña, Spain

<sup>b</sup> CIBER de Epidemiología y Salud Pública (CIBERESP), Spain

<sup>c</sup> Servicio de Oncología, Hospital Puerta de Hierro-Majadahonda, Majadahonda, Madrid, Spain

<sup>d</sup> Instituto de Investigación Puerta de Hierro-Majadahonda, Majadahonda, Madrid, Spain

<sup>e</sup> Instituto Nacional de Silicosis, Área del Pulmón, Hospital Universitario Central de Asturias, Oviedo, Asturias, Spain

<sup>f</sup> Facultad de Medicina, Universidad de Oviedo, Oviedo, Asturias, Spain

\* Corresponding author.

E-mail address: [pcasan@ins.es](mailto:pcasan@ins.es) (P. Casan Clarà).

1579-2129/

© 2017 SEPAR. Published by Elsevier España, S.L.U. All rights reserved.

## Repair of Iatrogenic Tracheobronchial Injury With Synthetic Dural Graft



### Reparación de una lesión traqueobronquial iatrogénica con un injerto de duramadre sintética

Dear Editor:

Tracheobronchial injury (TBI), is a rare but life-threatening clinical condition. It can be produced by blunt or open trauma of the cervical and thoracic regions, or by iatrogenic causes, including tracheal intubation, tracheotomy, bronchoscopy, tracheal and bronchial stent placement.<sup>1</sup> In this article, we present a case of iatrogenic TBI that was repaired using a synthetic dural graft.

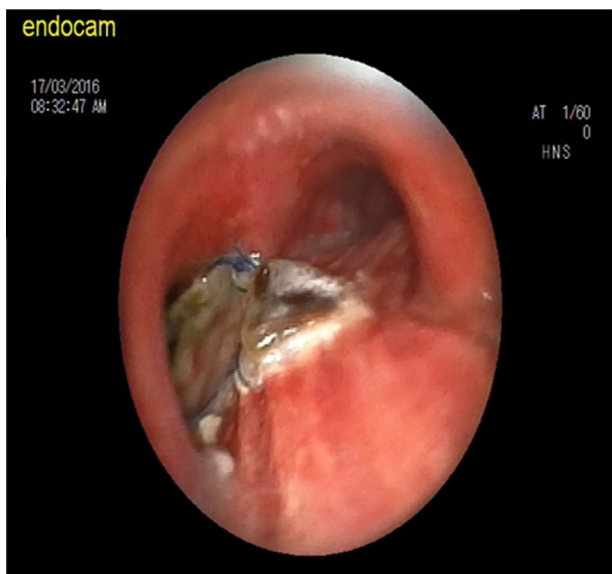


Fig. 1. FOB image at first (2-month) follow-up.

A 62-year old man presented in our hospital with weight loss and difficulty in swallowing. He was admitted to the general surgery unit and underwent gastroscopy, which revealed an ulcerated, fragile, bleeding lesion in the upper third of the esophagus. Histological study of the biopsy sample showed an epidermoid carcinoma. The patient agreed to undergo surgery. Preoperative left posterolateral thoracotomy performed to mobilize the esophagus led to a massive air leak, hypoventilation and desaturation. Emergency evaluation of the patient in the operating theater by the thoracic surgery consultant revealed a rupture. Primary repair of the injury was impossible due to a severe stricture observed in the left upper bronchus caused by cartilage tissue loss in the trachea. Given the state of emergency, a synthetic dural graft (polyethylene terephthalate, dimethyl siloxane) was placed on the injured area and anastomosed with 4/0 polypropylene suture. The graft line was reinforced with fibrin sealant and the application of a composite mesh. After oxygenation, an end-to-end anastomotic stapler was used to reconnect the proximal esophagus to the stomach fundus. The patient was discharged from the hospital 15 days after surgery, and was followed up at 2 and 3 months with fiber optic bronchoscopy (FOB) to evaluate the tracheobronchial lumen and graft (Fig. 1). The graft remained intact with no air leakage and no narrowing at the distal third of the trachea, carina and proximal left main bronchus. The patient is still being followed-up at our clinic.

Eighty percent of TBI's occur around the carina, mainly in the left main bronchus.<sup>2</sup> Primary surgical repair is the treatment of choice. However, based on clinical and endoscopic findings, conservative treatment can be employed in some cases.<sup>3</sup> In our case, a rupture measuring approximately 3 cm was observed in the left distal trachea, carina and cartilage and membranous portions of the left main bronchus, with a width of 1 cm in the carina, necessitating the use of the synthetic dural graft.

Bostanci et al. reported repairing a 7 cm rupture of the membranous trachea with a pleural patch and vascular graft.<sup>4</sup> In our case, a review of the literature did not yield any reports of TBI repair with synthetic dural graft.

We present this case to show that a synthetic dural graft, which is durable, water tight and highly elastic, can be a good alternative for TBI repair under appropriate conditions.

## References

1. Paraschiv M. Iatrogenic tracheobronchial rupture. *J Med Life*. 2014;7:343–8.
2. Martín de Nicolás JL, Gámez AP, Cruz F, Díaz-Hellín V, Marrón M, Martínez JI, et al. Long tracheobronchial and esophageal rupture after blunt chest trauma: injury by airway bursting. *Ann Thorac Surg*. 1996;62:269–72.
3. Marquette CH, Bocquillon N. Conservative treatment of tracheal rupture. *J Thorac Cardiovasc Surg*. 1999;117:399–401.
4. Bostancı EB, Ozer I, Ekiz F, Atıcı AE, Reyhan E, Akoğlu M, et al. Repair of an extensive iatrogenic tracheal rupture with a pleural patch and a vascular graft. *Ulus Travma Acil Cerrahi Derg*. 2012;18:83–6.

M. Arif Haberal<sup>a</sup> Özlem Şengören Dikiş<sup>b,\*</sup> Tekin Yıldız<sup>b</sup>

<sup>a</sup> Health Sciences University, Bursa Yüksek İhtisas Education and Research Hospital, Thoracic Surgery Department, Bursa, Turkey  
<sup>b</sup> Health Sciences University, Bursa Yüksek İhtisas Education and Research Hospital, Pulmonary Diseases Department, Bursa, Turkey

\* Corresponding author.

E-mail address: ozlemsengoren@hotmail.com (Ö.Ş. Dikiş).

<http://dx.doi.org/10.1016/j.arbres.2017.02.017>

0300-2896/

© 2017 SEPAR. Published by Elsevier España, S.L.U. All rights reserved.

## Spectrum of Alpha-1 Antitrypsin Deficiency Mutations Detected in Tenerife<sup>☆</sup>



### *Espectro de mutaciones deficitarias de alfa-1 antitripsina detectadas en Tenerife*

To the Editor,

Alpha-1 antitrypsin (AAT) is the most abundant protease inhibitor of human serum, with average concentrations in healthy individuals ranging between 120 and 220 mg/dl determined by nephelometry. The synthesis of AAT depends on the SERPINA1 gene.<sup>1,2</sup>

The most common deficiency alleles found in Spain are the PI\**S* and the PI\**Z*, and approximately 1/5 and 1/61 individuals in Spain, respectively, are carriers of this mutation.<sup>3–5</sup> These alleles have been associated with the development of pulmonary emphysema in early adulthood, liver diseases in children and adults, and other entities such as systemic vasculitis (especially Wegener's granulomatosis positive for c-ANCA) or necrotizing panniculitis.<sup>2,6</sup>

Few population genetic studies of AAT deficiency alleles have been conducted in the Canary Islands,<sup>7</sup> and none have identified rare deficiency alleles. For this reason, the aim of this study was to describe the spectrum of mutations found in the population of Tenerife seen at the Hospital Universitario Nuestra Señora de Candelaria (HUNSC).

This was a cross-sectional, descriptive study of a series that includes index cases with AAT plasma levels below 100 mg/dl who were referred to the Clinical Laboratory department of the HUNSC on clinical suspicion of alpha-1 antitrypsin deficiency (AATD) between January 1, 2009 and August 31, 2016.

AAT serum values were determined by nephelometry (BN ProSpec System, Siemens). Genomic DNA was purified from whole blood with EDTA (QIAamp DNA blood mini kit, Qiagen). The two most common deficiency alleles PI\**S* and PI\**Z* were genotyped by real-time PCR using FRET probes (LightCycler 2.0). The genotypes obtained were correlated with previously determined plasma AAT values, following the routine protocol in our hospital.<sup>8</sup> Patients with AAT plasma levels out of range of those expected for the genotypes S/Z obtained underwent complete sequencing of the coding exons and intronic sequences flanking the SERPINA1 gene (BigDye v3.1, Thermo Fisher), replacing conventional isoelectric focusing phenotyping. SERPINA1 sequencing was performed in a AB3500 capillary sequencer (Applied Biosystems), and results were compared with the NM\_001127701.1 reference sequence (SeqScape 3.0).

<sup>☆</sup> Please cite this article as: Martínez Bugallo F, Figueira Gonçalves JM, Martín Martínez MD, Díaz Pérez D. Espectro de mutaciones deficitarias de alfa-1 antitripsina detectadas en Tenerife. *Arch Bronconeumol*. 2017;53:595–596.

In total, 325 AATD patients with AAT plasma levels <100 mg/dl were included in the study. Studies directed at the PI\**S* and PI\**Z* deficiency alleles were conducted in all patients. Genotypes are shown in Table 1.

Forty-six patients (14.2%) had a genotype associated with severe deficiency (AAT<50 mg/dl), of which 24 were PI\**ZZ*, 10 PI\**SZ*, 1 PI\**SS*, 2 PI\**S*/Mmalton, 1 PI\**Z*/Q0amersfoort, 1 PI\**Z*/Q0cardiff, 1 PI\**Z*/Mmalton, 2 PI\**M*malton/Mmalton, 1 PI\**MZ*, 2 PI\**S*/NoSnoZ and 1 PI\**Z*/NoSnoZ. In total, 279 patients (85.8%) were recorded as having mild-to-moderate deficiency (AAT between 50 and 100 mg/dl), distributed as follows: 119 PI\**Z*/NoSnoZ, 59 PI\**SZ*, 36 PI\**S*/NoSnoZ, 24 PI\**SS*, 8 PI\**M*/Mmalton, 4 PI\**M*/Mpalermo, 2 PI\**S*/Mmalton, 1 PI\**S*/Mpalermo, 1 PI\**ZZ*, 1 PI\**MZ*, 1 PI\**MI*, 3 PI\**MM* and 20 NoSnoZ/NoSnoZ.

The percentage of carriers of rare deficiency alleles was 7.7%, 80% of whom had the mutation F76del (PI\**M*malton and PI\**M*palermo).

In this study, we performed an AATD diagnostic protocol based on the quantification of AAT plasma levels, followed by genotyping for deficiency alleles PI\**S* and PI\**Z*, as these are the most common in our population. In recent years, correlation of both results has been shown to be the most efficient technique, achieving an unequivocal diagnosis in approximately 96% of cases.<sup>8</sup> In the remaining patients, SERPINA1 full-gene sequencing was performed, a technique that

**Table 1**  
Genotypes and AAT Levels Obtained in the Study.

Genotype	n	%	AAT	SD
SS	25	7.7%	81.1	12.5
SZ	69	21.2%	59.4	12.0
ZZ	25	7.7%	25.9	9.8
M/M	3	0.9%	88.5	7.4
NoSnoZ/NoSnoZ	20	6.2%	80.0	10.5
NoSnoZ/S	38	11.7%	83.2	13.5
NoSnoZ/Z	122	37.5%	78.0	11.3
S/Rare	5	1.5%	50.8	5.8
S/Mmalton	4	1.2%	49.5	5.9
S/Mpalermo	1	0.3%	56.0	–
Z/Rare	3	0.9%	32.9	12.6
Z/Mmalton	1	0.3%	18.9	–
Z/Q0cardiff	1	0.3%	49.5	–
Z/Q0amersfoort	1	0.3%	30.4	–
M/Rare	13	4%	76.9	6.3
M/Mmalton	8	2.5%	77.0	4.5
M/Mpalermo	4	1.2%	74.9	8.2
M/I	1	0.3%	84.8	–
Rare/Rare	2	0.6%	16.6	–
Mmalton/Mmalton	2	0.6%	16.6	–
Total	325	100%	56.5	19.9

AAT: alpha-1 antitrypsin deficiency; SD: standard deviation; rare: rare deficiency variants.