

Clinical Image

Endobronchial Leiomyoma: Outcome of Conservative Management[☆]



Resultados del manejo conservador de un leiomioma endobronquial

Francisco García Gómez,^a Ana Triviño,^{a,*} Karla Tello Collantes^b

^a Servicio de Cirugía Torácica, Hospital Universitario Puerta del Mar, Cádiz, Spain

^b Servicio de Anatomía Patológica, Hospital Universitario Puerta del Mar, Cádiz, Spain

We report the case of a 46-year-old woman who attended the respiratory medicine clinic due to dyspnea, MRC grade I–II. Radiological study and fiberoptic bronchoscopy revealed a rounded, hypervascularated, pedunculated mass, located 2 cm from the main carina, with an implantation base of less than 1 cm in the left main bronchus.

Given the characteristics of the mass and the risk of hemorrhage, we decided to perform resection under rigid fiberoptic bronchoscopy-guidance, to obtain a biopsy and resolution of the occlusion.

The patient was discharged 24 h after the procedure without any incidents. A diagnosis of endobronchial leiomyoma was confirmed (Fig. 1), and the patient was followed up with flexible fiberoptic bronchoscopy and imaging tests. Nine months after treatment, she remains asymptomatic and free of disease.

Pulmonary leiomyoma is a rare tumor of mesodermal origin.^{1,2} Treatment of choice is resection using the most conservative technique possible. For endoluminal tumors, White et al.¹ and Tan et al.² defend the treatment of endobronchial leiomyoma using an endoscopic resection technique with endoforceps, electrocautery or laser, since no reports of relapse or distant seeding have been described after limited resection.

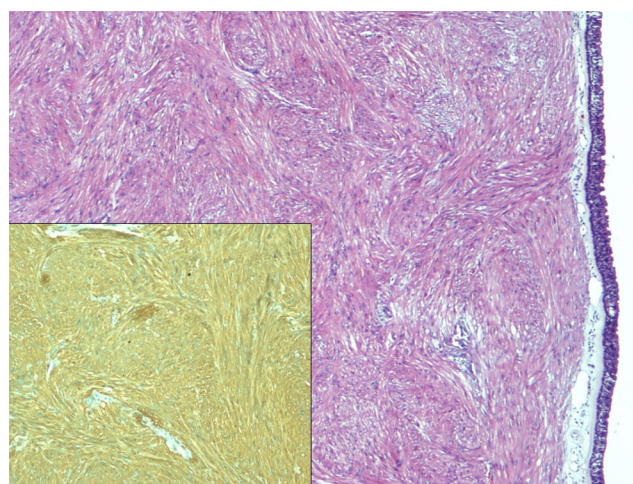


Fig. 1. Image showing a fasciculated subepithelial fusocellular tumor with no necrosis or mitotic activity (H&E ×4), with positive immunostaining for smooth muscle actin (lower image, SMA ×10).

References

1. White SH, Ibrahim NBN, Forrester-Wood CP, Jeyasingham K. Leiomyomas of the lower respiratory tract. *Thorax*. 1985;40:306–11.
2. Tan JH, Takano AM, Hsu AA. Resection with preserved histologic morphology of a rare tumour via bronchoscopic cryosurgery. *J Thorac Dis*. 2016;8:2964–7.

[☆] Please cite this article as: García Gómez F, Triviño A, Tello Collantes K. Resultados del manejo conservador de un leiomioma endobronquial. *Arch Bronconeumol*. 2017;53:518.

* Corresponding author.

E-mail address: atrivi.17@hotmail.com (A. Triviño).