



Scientific Letters

Percutaneous Closure of Coronary Artery Fistula Before Lung Transplantation[☆]



Embolización percutánea en fístula de arteria coronaria previo al trasplante pulmonar

To the Editor,

We report the case of a 54-year-old man, waitlisted for lung transplantation with a diagnosis of end-stage diffuse bronchiectasis. On arrival at the catheterization laboratory for coronary angiography prior to transplantation, the patient developed a hypertensive crisis (BP 200/110 mmHg), at which stage he reported habitually uncontrolled blood pressure. Coronary angiography revealed coronary arteries free of lesions and a coronary artery fistula emerging from the left common trunk (LCT), 3 mm in caliber at the proximal end and 2 mm at the most distal end (Video 1, Appendix), with drainage to the left pulmonary artery, causing hemodynamic alterations in the form of high cardiac output (thermodilution 7.86 l/min). Increased pulmonary pressures (mPAP 71 mmHg, PVR 5.5 Wood units [WU]) associated with pulmonary hyperflow and significant diastolic dysfunction due to hypertensive heart disease evidenced in the rest of the study data (mean PCP 35 mmHg and left ventricular end-diastolic pressure [LVEDP] 25 mmHg). The examination was completed with heart computed tomography (Fig. 1A). Transesophageal echocardiography (TEE) showed involvement of right chambers, while the bubble test ruled out intra-cardiac shunt. Diastolic changes with LV parietal hypertrophy and normal LV systolic function were confirmed. Percutaneous closure of the fistula in the proximal/medial segment was performed with 3 coils measuring 3 mm × 4 mm and 3 mm × 2 mm. Occlusion was confirmed immediately with fluoroscopy (Video 2, Appendix), and subsequently with a follow-up coronary CT one month after the procedure (Fig. 1B). Follow-up right heart catheterization revealed a marked improvement in

mPAP (48 mmHg) after resolution of pulmonary hyperflow (cardiac output 4.3 l/min and aPVR 4.6 WU), and persistently elevated PWP and LVEDP associated with the patient's hypertensive left heart disease (PWP 25 mmHg and LVEDP 23 mmHg).

Coronary artery fistulas are abnormal connections between a coronary artery and one of the heart chambers or one of the vessels located around the heart.^{1,2} Most are congenital, but they may also be acquired.¹ Coronary artery fistulas are observed in 0.2%–0.6% of all angiograms.¹ Most patients are asymptomatic; however, the fistula can sometimes form an arteriovenous short circuit with hemodynamic repercussions, generating heart failure due to volume overload caused by the left-to-right shunt, ischemia due to coronary steal syndrome, fistula rupture or thrombosis, arrhythmias, and infectious endocarditis.^{1,2}

In adults it is usually an incidental finding during a coronary angiography,¹ as was the case with our patient during the pre-lung transplant study. Some authors recommend closure of the fistula, even in asymptomatic patients.² Reidy et al.^{1,3} performed the first percutaneous closure in 1983, and since then this procedure has been considered an effective and less traumatic option than surgical closure.² Several authors have demonstrated its safety and effectiveness^{3,4} in the management of this disease, reserving surgical closure for multiple or large fistulas.² Several devices have been used for percutaneous closure, the most commonly used being coils and Amplatzer vascular plugs. Amplatzer vascular plugs are usually used in longer, wider fistulas, and coils in smaller fistulas.^{3,4} Fistulas usually originate in the left anterior descending artery, followed by the right coronary and circumflex arteries,^{1,3} and frequently drain into the pulmonary artery.¹ Approximately 10% of closures are incomplete or recurrent.¹

Percutaneous closure of coronary artery fistula prior to lung transplantation is a safe and effective option that reduces the risk associated with volume overload, coronary steal and other complications encountered in patients with this anomaly.

[☆] Please cite this article as: Urmeneta Ulloa J, Molina Borao I, Ochoa Rea ME, Sánchez-Insa E. Embolización percutánea en fístula de arteria coronaria previo al trasplante pulmonar. Arch Bronconeumol. 2017;53:520–521.

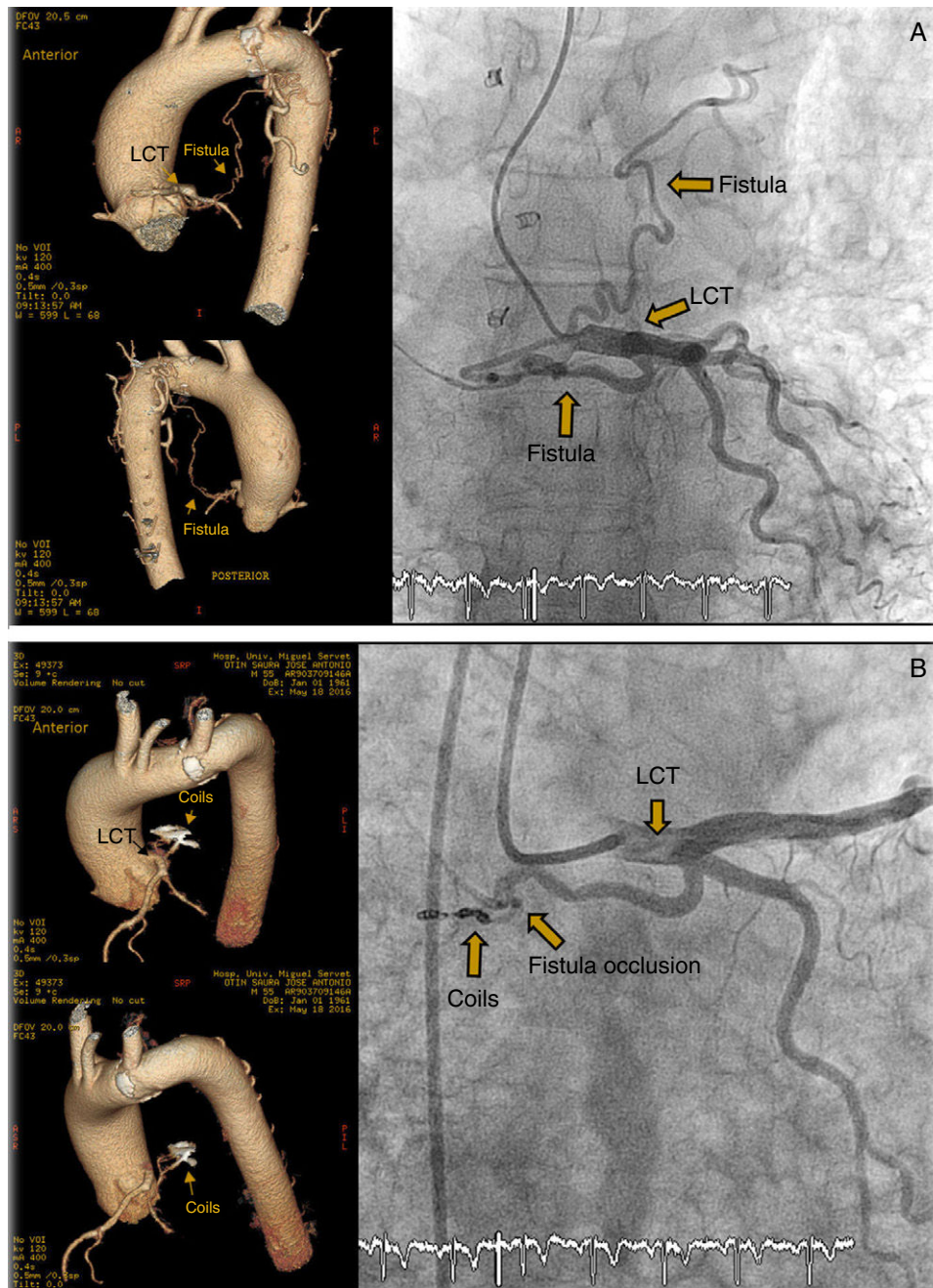


Fig. 1. (A) Coronary artery fistula from the LCT to the left pulmonary artery. CT and angiography. (B) Percutaneous closure of coronary artery fistula using coils. CT and angiography.

Appendix A. Supplementary data

Supplementary data associated with this article can be found, in the online version, at [doi:10.1016/j.arbr.2017.07.008](https://doi.org/10.1016/j.arbr.2017.07.008).

References

1. Jama A, Barsoum M, Bjarnason H, Holmes DR Jr, Rihal CS. Percutaneous closure of congenital coronary artery fistulae: results and angiographic follow-up. *JACC Cardiovasc Interv.* 2011;4:814–21.
2. Díaz de la Llera LS, Fournier Andray JA, Gómez Moreno S, Mayol Deya A, González García A, Pérez Fernández-Cortacero JA. Percutaneous occlusion with coils of coronary artery fistulas in adults. *Rev Esp Cardiol.* 2005;58:93–6 [Article in Spanish].
3. Armsby LR, Keane JF, Sherwood MC, Forbess JM, Perry SB, Lock JE. Management of coronary artery fistulae. Patient selection and results of transcatheter closure. *J Am Coll Cardiol.* 2002;39:1026–32.

4. Girona J, Martí G, Betrián P, Gran F, Casaldàliga J. Percutaneous embolization of vascular fistulas using coils or amplatzer vascular plugs. *Rev Esp Cardiol.* 2009;62:765–73 [Article in English, Spanish].

Javier Urmeneta Ulloa,* Isabel Molina Borao, Maria Elisa Ochoa Rea, Esther Sánchez-Insa

Departamento de Cardiología, Hospital Universitario Miguel Servet, Zaragoza, Spain

* Corresponding author.

E-mail address: javierurmeneta@hotmail.com (J. Urmeneta Ulloa).

1579-2129/

© 2017 SEPAR. Published by Elsevier España, S.L.U. All rights reserved.