

Clinical Image

Plastic Bronchitis in a Patient With Silicosis[☆]



Bronquitis plástica en un paciente con silicosis

José Jesús Blanco Pérez,^{a,b,*} Victoria Arnalich Montiel,^{a,b} José Luis Guerra Vales^{a,b}

^a Servicio de Neumología, Hospital Alvaro Cunqueiro, EOXI, Vigo, Pontevedra, Spain

^b IRIDIS Group (Investigation in Rheumatology and Immuno-Mediated Diseases) del Instituto de Investigación Biomédica de Vigo, Ourense y Pontevedra, Vigo, Pontevedra, Spain

We report the case of a 49-year-old man with complicated silicosis and a history of pulmonary tuberculosis, non-smoker, with obstructive airflow limitation. He consulted due to episodes of intense dyspnea coinciding with expectoration of thick bloody secretions with a similar appearance to the bronchial tree (Fig. 1), occurring several days a week. The fiberoptic bronchoscopy showed no relevant findings and the pathology study of the bronchial cast revealed fibrinoinflammatory mucoid material, with abundant histiocytes.

Plastic bronchitis (PB) is a rare lung disease characterized by the formation and expectoration of bronchial casts that obstruct the bronchial lumen.¹ It has been described as a complication of primary lymphatic abnormalities in patients with congenital heart disease (after the Fontan procedure), respiratory infections, cystic fibrosis, COPD, and allergic bronchopulmonary aspergillosis.¹ We report a case of PB associated with silicosis. Treatment is controversial and therapeutic choices, which are based on isolated case reports, include mainly dornase alfa, low-dose macrolides, and nebulized hypertonic saline and acetylcysteine. Response to inhalation of fibrinolytics and nebulized heparin has been reported.^{1,2} In our patient, episodes of mucus plug expulsion reduced notably with the administration of prednisone (15 mg/day) and nebulized heparin sodium (5000 IU/12 h).

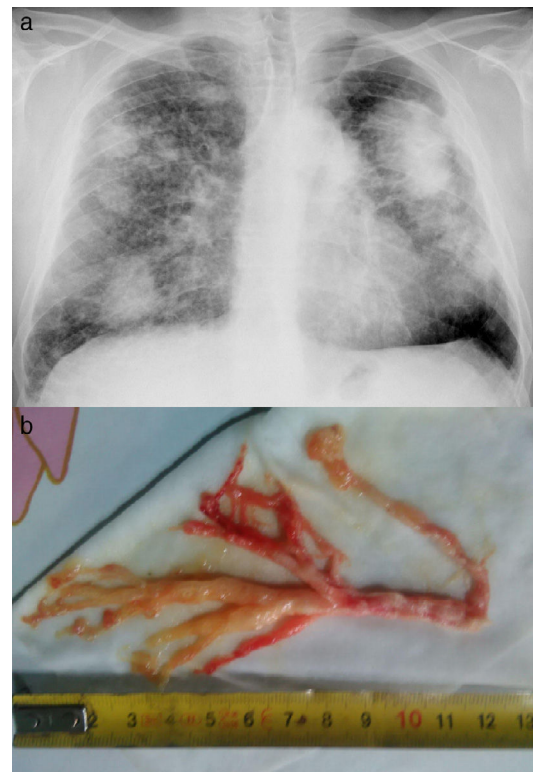


Fig. 1. (a) Interstitial pattern with bilateral conglomerates and (b) expectorated bronchial cast.

References

1. Rubin BK. Plastic bronchitis. *Clin Chest Med.* 2016;37:405–8.
2. Eberlein MH, Drummond MB, Haponik EF. Plastic bronchitis: a management challenge. *Am J Med Sci.* 2008;335:163–9.

[☆] Please cite this article as: Blanco Pérez JJ, Arnalich Montiel V, Guerra Vales JL. Bronquitis plástica en un paciente con silicosis. *Arch Bronconeumol.* 2017;53:516.

* Corresponding author.

E-mail address: josejesus.blanco.perez@sergas.es (JJ. Blanco Pérez).