

achieves high concentrations in pleural fluid,^{8,9} pleural empyemas caused by Aspergillosis are usually treated with a combination of various antifungals⁵ due to the high mortality rate (34%–75%, depending on when it is evaluated).^{1,6} Intrapleural administration has been described in isolated cases,^{1,10} and more studies are required to support this strategy. Treatment for all empyemas requires chest drainage, and if the patient presents life-threatening hemoptysis, lung resection surgery should be considered.¹¹

In summary, in an immunocompromised cancer patient with pleural empyema, cultures in the appropriate media should be performed to rule out fungal infection. Treatment must consist of chest drainage and the long-term administration of a combination of various antifungals, including voriconazole, since mortality in these infections is high.

References

1. Ko SC, Chen KY, Hsueh PR, Luh KT, Yang PC. Fungal empiema thoracis: an emerging clinical entity. *Chest*. 2000;117:1672–8.
2. Shiraishi Y, Katsuragi N, Nakajima Y, Hashizume M, Takahashi N, Miyasaka Y. Pneumonectomy for complex aspergilloma: is it still dangerous. *Eur J Cardiothorac Surg*. 2006;29:9–13.
3. Pagano L, Caira M, Candoni A, Offidani M, Fianchi L, Martino B, et al. The epidemiology of fungal infections in patients with hematologic malignancies: the SEIFEM-2004 study. *Haematologica*. 2006;91:1068–75.
4. De Pauw B, Walsh JT, Donnelly JP, Stevens AD, Edwards EJ, Calandra T, et al. European Organization for Research and Treatment of Cancer/Invasive Fungal Infections Cooperative Group; National Institute of Allergy and Infectious Diseases Mycoses Study Group (EORTC/MSG) Consensus Group. Revised definitions of invasive fungal disease from the European Organization for Research and Treatment of Cancer/Invasive Fungal Infections Cooperative Group and the National Institute of Allergy and Infectious Diseases Mycoses Study Group (EORTC/MSG) Consensus Group. *Clin Infect Dis*. 2008;46:1813–21.
5. Walsh TJ, Bulkley BH. *Aspergillus* pericarditis: clinical and pathologic features in the immunocompromised patient. *Cancer*. 1982;49:48–54.
6. Nigo M, Vial MR, Munita JM, Jiang Y, Tarrand J, Jiménez CA, et al. Fungal empyema thoracis in cancer patients. *J Infect*. 2016;72:615–21.
7. Walsh TJ, Anaissie EJ, Denning DW, Herbrecht R, Kontoyiannis DP, Marr KA, et al. Treatment of aspergillosis: clinical practice guidelines of the Infectious Diseases Society of America. *Clin Infect Dis*. 2008;46:327–60.
8. Matsuda M, Koreeda Y, Mataka H, Taira T, Noma S, Higashimoto I. A case of *Aspergillus* empyema successfully treated with combination therapy of voriconazole and micafungin: excellent penetration of voriconazole and micafungin into pleural fluid. *Inter Med*. 2010;49:1163–9.
9. Stern JB, Girard P, Caliandro R. Pleural diffusion of voriconazole in a patient with *Aspergillus fumigatus* empiema thoracis. *Antimicrob Agents Chemother*. 2004;48:1065.
10. Baquero-Artigao F, Garcia-Miguel JM, Hernández F, Hernández N, del Castillo F. Combined systemic and intrapleural treatment of *Aspergillus* plmonary empiema after invasive aspergillosis. *Pediatr Infect Dis J*. 2003;22:471–3.
11. Hillerdal G. Pulmonary *Aspergillus* infection invading the pleura. *Thorax*. 1981;36:745–51.

Lucía Ferreiro,^{a,b,*} M. Luisa Pérez del Molino,^c
Marta Sonia González-Pérez,^d Luis Valdés^{a,b}

^a Servicio de Neumología, Complejo Hospitalario Universitario de Santiago de Compostela, Santiago de Compostela, La Coruña, Spain

^b Grupo Interdisciplinar de Investigación en Neumología, Instituto de Investigaciones Sanitarias de Santiago (IDIS), Santiago de Compostela, La Coruña, Spain

^c Servicio de Microbiología, Complejo Hospitalario Universitario de Santiago de Compostela, Santiago de Compostela, La Coruña, Spain

^d Servicio de Hematología, Complejo Hospitalario Universitario de Santiago de Compostela, Santiago de Compostela, La Coruña, Spain

* Corresponding author.

E-mail address: lferfer7@gmail.com (L. Ferreiro).

1579-2129/

© 2016 SEPAR. Published by Elsevier España, S.L.U. All rights reserved.

Is a Respiratory Day Hospital Useful in Patients with Severe Disease?*



¿Es útil un hospital de día de enfermedades respiratorias en pacientes graves?

To the Editor:

Respiratory day hospitals (RDH) are a useful alternative form of hospitalization.¹ However, no studies are available that demonstrate their suitability for managing exacerbations in patients with severe respiratory disease. In this communication, we report our experience in this area.

Between December 2013 and November 2014, we performed an observational, longitudinal, quasi-experimental study (patients were their own controls) of all patients who attended the RDH (2 or more admissions/emergency visits due to decompensation of an underlying respiratory disease in the previous year). All patients were followed for 1 year, and data from the previous year were obtained from their clinical records. The study was approved by the Ethics Committee (no. 2016/424). Widely accepted criteria were used to establish the diagnosis of COPD, asthma, and bronchiectasis, and to determine levels of physical activity, dyspnea grade, deterioration of state of health, BODE index,

6-minute walk test, classification of COPD patients, and definition of sepsis.^{2–12}

A descriptive analysis was conducted of patient characteristics, and visits to the emergency department/hospitalizations between the year prior to and the year after the patient's first visit to the RDH were compared using the Wilcoxon non-parametric test for paired data, and variables associated with hospitalization were studied. It was estimated that the mean annual number of events (emergency visits and admissions) in these patients would be 9–10, and that after implementation of the RDH this rate could be reduced by 25%. To achieve a power of 85%, 125 patients would be needed to detect significant differences ($p < 0.05$) between the number of events before and after RDH.

During the study period, 1053 visits to the RDH for exacerbations were recorded in 129 patients (COPD [87], bronchiectasis [12], asthma [7], and others [23]). Fig. 1 shows the level of physical activity (low/moderate in 112/129) (Fig. 1A), dyspnea grade (mMRC 34 in 71/129) (Fig. 1B), 6-minute walk test (42/129 walked < 250 m) (Fig. 1C), and FEV1 (84/129 < 50%) of the overall study population (Fig. 1D). Among COPD patients, 57/87 had a BODE index > 4 (Fig. 1E), 82/87 were GOLD stage D (Fig. 1F), 76/87 had a GesEPOC exacerbator phenotype (Fig. 1G), 76/87 had CAT ≥ 10, 5/87 had a body mass index < 21, 5/87 had alpha-1 antitrypsin deficiency, and 16/87 were receiving BiPAP home oxygen therapy (Fig. 1H). In total, 8.6% of visits (91/1053) required hospital admission, mainly due to the need for intravenous antibiotics (25; 27.5%), acute respiratory failure (21; 23.1%), and failure of previous outpatient therapy (12; 13.2%). When the year prior to and the year after the first visit to

* Please cite this article as: Lourido-Cebreiro T, Rodríguez-García C, Gude F, Valdés L. ¿Es útil un hospital de día de enfermedades respiratorias en pacientes graves? Arch Bronconeumol. 2017;53:400–402.

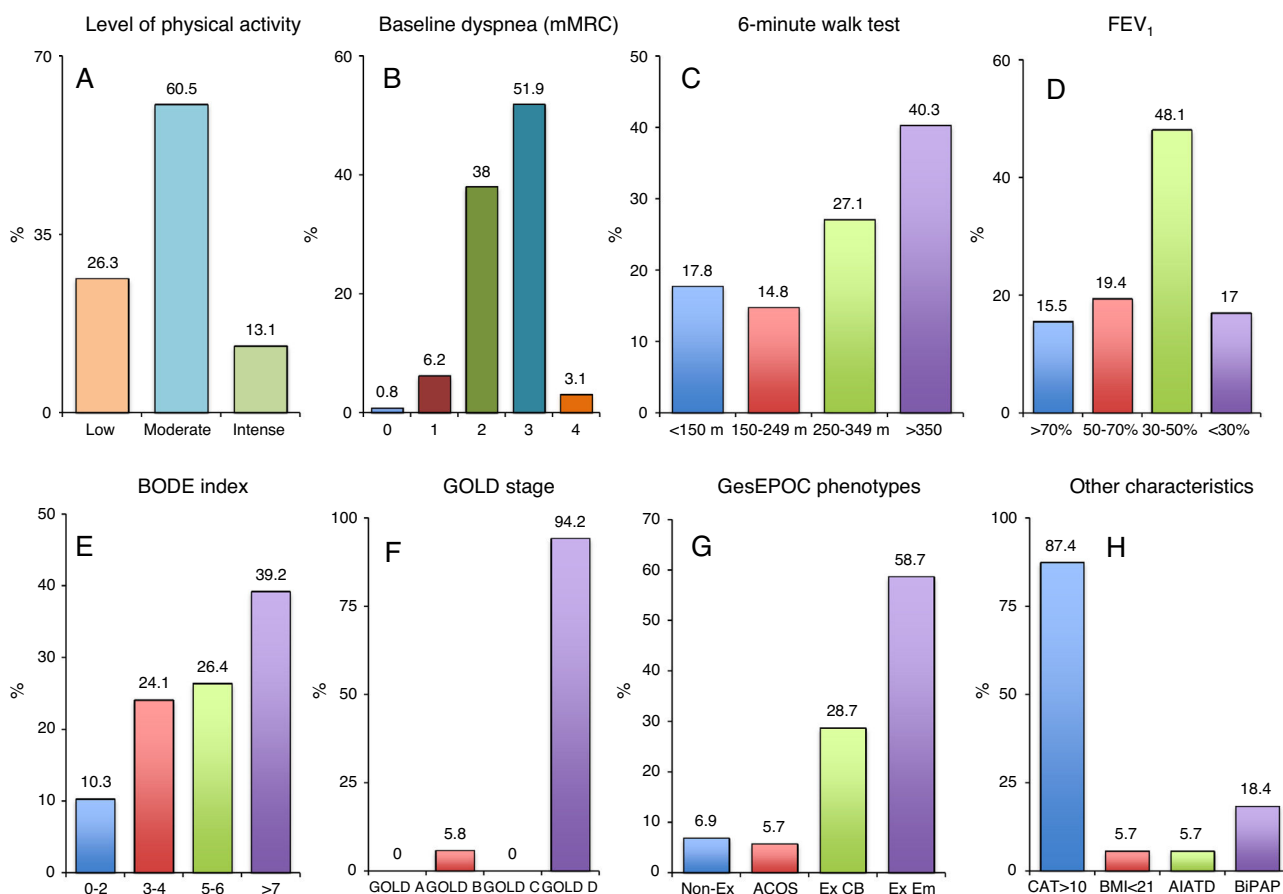


Fig. 1. (A) Level of physical activity, (B) dyspnea grade, (C) 6-minute walk test, and (D) FEV₁ in the overall study population. (E) BODE index, (F) GOLD stage, (G) GesEPOC phenotype, (H) CTA, body mass index, alpha-1 antitrypsin deficiency, and BiPAP home therapy in COPD patients. AIATD: alpha-1 antitrypsin deficiency; BiPAP: bilevel positive airway pressure; BMI: body mass index; CAT: chronic obstructive pulmonary disease assessment test; CB: chronic bronchitis; Em: emphysema; Ex: exacerbator; mMRC: modified Medical Research Council.

the RDH were compared, a reduction in both the number of visits to the emergency room (110 vs 57; $P=.001$), and in the number of hospital admissions (236 vs 183; $P=.006$) was observed. Results were similar when data from patients who died during the follow-up year (19; 14.7%) were excluded: 90 vs 43 visits to the emergency room ($P=.002$); and 190 vs 141 hospital admissions ($P=.003$). Moreover, 81.8% (45/55) of patients receiving continuous home oxygen therapy had COPD.

A multivariate analysis of COPD patients found that factors associated with a greater risk of admission were respiratory acidosis (OR 9.67; 95% CI: 1.48–62.9), diabetes mellitus (OR 2.01; 95% CI: 1.08–3.77), low blood pressure (OR 0.99; 95% CI: 0.97–1.00), tachycardia (OR 1.02; 95% CI: 1.00–1.04), diuretic failure (OR 19.7; 95% CI: 4.32–89.8), isolation of a multiresistant microorganism in sputum (OR 4.41; 95% CI: 2.06–9.42), sepsis (OR 4.01; 95% CI: 1.16–13.8), and use of accessory muscles (OR 4.94; 95% CI: 2.60–9.40).

This study confirms that even in the first year of functioning, the RDH can reduce pressure on the emergency department and the number of admissions, despite the advanced respiratory disease status and high comorbidity burden of the patients seen. Moreover, it shows that certain factors are associated with a higher risk of admission among COPD patients. Our results coincide with those of other studies,^{1,13,14} although our series differs in that most of our patients had very severe disease and presented higher exacerbation rates.

The significant reduction, in both the number of visits to the emergency room (110 vs 57; $P=.001$), and the number of hospital admissions (236 vs 183; $P=.006$) compared to the previous year appears to confirm the efficacy of the RDH. These results may be directly associated with the more specialized care provided the RDH doctors and nurses in the management of the respiratory patient.

The opening hours of the RDH are limited and a patient's destination must be decided within a few hours, so we examined which factors in COPD patients might predict hospitalization, to be able to anticipate their final destination. Some of the factors we identified are indicative of very severe COPD exacerbations¹¹: patients who may need ventilation (acidosis) or who have hemodynamic instability (tachycardia and hypotension).

The limitations of this study are: (1) no strict protocol for reevaluation of each exacerbation (all patients were seen 72 hours after an exacerbation,¹¹ but some had to be seen several times); (2) use of an mMRC scale for evaluating dyspnea in all patients although it is only validated for COPD. We decided to use this tool because it is easy to apply and because it is usually collected in the emergency department; and (3) lack of a cost-effectiveness study.

In short, a RDH can constitute an alternative to conventional hospitalization, and is suitable for the outpatient management of a large number of respiratory exacerbations, even in severe patients. COPD patients present a series of factors that predict a greater risk of hospital admission.

References

- Pomares-Amigó X, Montón-Soler C. Hospitales de día de enfermedades respiratorias: ¿qué hemos aprendido? *Med Clin (Barc)*. 2011;136:454–5.
- Celli BR, Decramer M, Wedzicha JA, Wilson KC, Agustí A, Criner GJ, et al. An official American Thoracic Society/European Respiratory Society statement: Research questions in COPD. *Am J Respir Crit Care Med*. 2015;191:e4–27.
- Reddel HK, Bateman ED, Becker A, Boulet LP, Cruz AA, Drazen JM, et al. A summary of the new GINA strategy: a roadmap to asthma control. *Eur Respir J*. 2015;46:622–39.
- Martínez-García MA, de Gracia J, Vendrell-Relat M, Girón RM, Máz-Carro L, de la Rosa-Carrillo D, et al. Multidimensional approach to non-cystic fibrosis bronchiectasis: the FACED score. *Eur Respir J*. 2014;43:1357–67.
- Esteban C, Quintana JM, Aburto M, Moraza J, Egurrola M, Pérez-Izquierdo J, et al. Impact of changes in physical activity on health-related quality of life among patients with COPD. *Eur Respir J*. 2010;36:292–300.
- Bestall JC, Paul EA, Garrod R, Garnham R, Jones PW, Wedzicha JA. Usefulness of the Medical Research Council (MRC) dyspnoea scale as a measure of disability in patients with chronic obstructive pulmonary disease. *Thorax*. 1999;54:581–6.
- Jones PW, Harding G, Berry P, Wiklund I, Chen WH, Kline Leidy N. Development and first validation of the COPD Assessment Test. *Eur Respir J*. 2009;34:648–54.
- Celli BR, Cote CG, Marin JM, Casanova C, Montes de Oca M, Méndez RA, et al. The body-mass index, airflow obstruction, dyspnea, and exercise capacity index in chronic obstructive pulmonary disease. *N Engl J Med*. 2004;350:1005–12.
- Casanova C, Costa CG, Marin JM, de Torres JP, Aguirre-Jaime A, Méndez R, et al. The 6-min walking distance: long-term follow up in patients with COPD. *Eur Respir J*. 2007;29:535–40.
- Vestbo J, Hurd SS, Agustí AG, Jones PW, Vogelmeier C, Anzueto A, et al. Global strategy for the diagnosis, management, and prevention of chronic obstructive pulmonary disease: GOLD executive summary. *Am J Respir Crit Care Med*. 2013;187:347–65.
- Grupo de trabajo de GesEPOC. Guía de práctica clínica para el diagnóstico y tratamiento de pacientes con enfermedad pulmonar obstructiva crónica (EPOC)—Guía española de la EPOC (GesEPOC). *Arch Bronconeumol*. 2012;48 Suppl. 1:2–58.
- Singer M, Deutschman CS, Seymour CW, Shankar-Hari M, Annane D, Bauer M, et al. The third international consensus definitions for sepsis and septic shock. *JAMA*. 2016;315:801–10.
- Cots F, Raventós J, Ausín P, Chiarello P, Balcells E, Castells X, et al. Hospital de día: análisis de resultados, costes y asignación de recursos. *Arch Bronconeumol*. 2013;49:54–62.
- Casas-Méndez LF, Montón-Soler C, Baré-Mañas M, Casabon-Salas J, Pomares-Amigo X, Aguirre-Larracochea U. Hospital de día de enfermedades respiratorias: impacto sobre la tasa de ingresos hospitalarios por exacerbaciones de la enfermedad pulmonar obstructiva crónica. *Med Clin (Barc)*. 2011;136:665–8.

Tamara Lourido-Cebreiro,^{a,*} Carlota Rodríguez-García,^a Francisco Gude,^{b,c} Luis Valdés^{a,d}

^a Servicio de Neumología, Complejo Hospitalario Universitario de Santiago, Santiago de Compostela, Spain

^b Unidad de Epidemiología Clínica, Complejo Hospitalario Universitario de Santiago, Santiago de Compostela, Spain

^c Grupo Epidemiología de Enfermedades Frecuentes, Instituto de Investigaciones Sanitarias de Santiago (IDIS), Complejo Hospitalario Universitario de Santiago, Santiago de Compostela, Spain

^d Servicio de Neumología, Grupo Interdisciplinar de Investigación en Neumología, Instituto de Investigaciones Sanitarias de Santiago (IDIS), Complejo Hospitalario Universitario de Santiago, Santiago de Compostela, Spain

* Corresponding author.

E-mail address: tamara.lourido.cebreiro@sergas.es

(T. Lourido-Cebreiro).

1579-2129/

© 2016 SEPAR. Published by Elsevier España, S.L.U. All rights reserved.

An Unusual Occupant of the Pulmonary Artery[☆]



Un ocupante insólito de la arteria pulmonar

To the Editor:

A hydatid cyst in the pulmonary arteries is a very rare presentation of hydatid disease that has been published on a very few occasions. In most cases, it is caused by rupture and embolization of a cardiac cyst¹ or hematogenous dissemination from a hepatic focus.² We report the case of a patient with hydatid cysts in the right lung and pulmonary artery, with no previous history of cardiac or hepatic hydatid disease.

This was a 56-year-old man with no substance abuse or significant medical history who consulted his primary care physician due to a 2-week history of bloody expectoration accompanied by right chest pain. The chest radiograph revealed a polylobulated mass in the right lower lobe with hilar thickening, initially suggestive of lung cancer. Chest computed tomography showed a mass measuring 11 × 8.8 cm in the right lower lobe with hypodense areas suggestive of cysts. The mass showed a 10 cm contact with pleural surface, extending with peribronchovascular distribution toward the hilar region. Multiple nodular images of similar characteristics measuring up to 4.5 cm were seen inside the artery. Radiological findings were suggestive of pulmonary hydatidosis with invasion of the right lower lobe artery (Fig. 1A–C).

[☆] Please cite this article as: Gómez Hernández MT, Rodríguez Pérez M, García Hernández P, Jiménez López MF. Un ocupante insólito de la arteria pulmonar. *Arch Bronconeumol*. 2017;53:402–404.

After serological confirmation of *Echinococcus granulosus* infection, the case was presented before the multidisciplinary committee, and the decision was taken to start antiparasitic treatment with albendazole (400 mg/12 h) and praziquantel (1800 mg/12 h), with follow-up CT for evaluating treatment response and subsequent surgical resection.

After 6 weeks of antiparasitic treatment, the radiological findings showed little reduction in mass size and persisting internal cavitated areas, along with significant neovascularization originating in the thoracic artery via the bronchial arteries, and in the celiac trunk, via the arteries of the diaphragm. The patient's lung function test results were within normal limits.

Surgical resection was performed, and antiparasitic treatment continued throughout the peri-operative period. Intraoperative findings included hepatization of the lower right lobe, significant vascularization originating in the bronchial arteries, and increased caliber of the right lower lobe artery. After control and clamping of the right pulmonary artery at the extrapericardiac origin, arteriotomy was performed at the lower lobe branch, and the intravascular hydatid cysts were extracted (Fig. 1D). The proximal lumen of the pulmonary artery was aspirated to the level of the clamp. Given the significant perihilar inflammatory reaction, the proximal intermediate bronchus could not be resected, so a middle-lower bilobectomy was performed.

The only post-operative complication presented by the patient was prolonged air leak. He was discharged on day 8 after surgery, and referred to the infectious diseases department for follow-up and control of his medical treatment.

Hydatidosis is a parasitic infection caused by the larval forms of *Echinococcus granulosus*. The most commonly affected organs