

Clinical Image

An Unusual Case of Bronchoaspiration of a Foreign Body in a Polytraumatized Patient[☆]



Un caso particular de broncoaspiración de cuerpo extraño en el paciente politraumatizado

María A. Ballesteros,^{a,*} Enrique Chicote Álvarez,^a Victor M. Mora Cuesta^b

^a Servicio de Medicina Intensiva, Hospital Universitario Marqués de Valdecilla, Santander, Cantabria, Spain

^b Servicio de Neumología, Hospital Universitario Marqués de Valdecilla, Santander, Cantabria, Spain

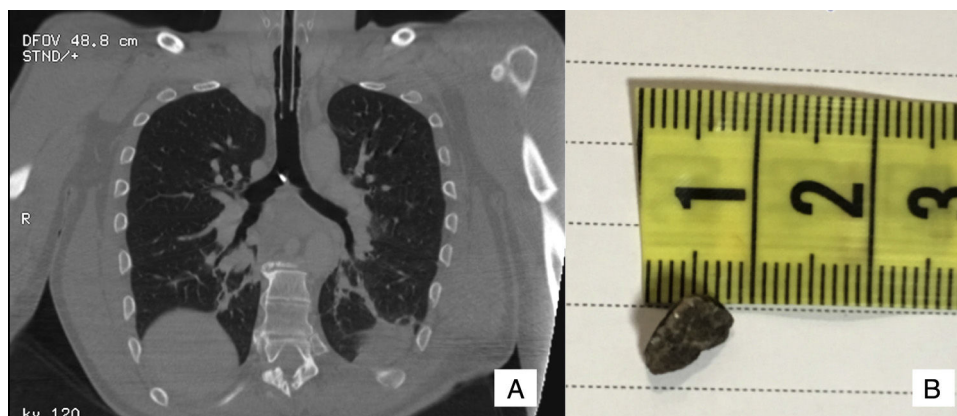


Fig. 1. (A) Chest tomography sagittal slice showing a radio-opaque foreign body in the carina. (B) Stone, 1 cm in largest diameter, extracted by fiberoptic bronchoscopy.

Cases of bronchoaspiration of teeth have been described in polytrauma patients,¹ but aspiration of other foreign bodies is less common. Clinical suspicion, a detailed clinical history, and a comprehensive evaluation of diagnostic tests are essential to rule out aspiration in this type of patient.²

We report the case of 45-year-old man who was admitted to the intensive care unit for multiple injuries resulting from a high-impact accident. He had Glasgow coma scale score 8, anisocoria, periorbital hematoma, and facial wounds. Airway patency was ensured with a cervical collar, and sedation and analgesia were given along with mannitol to control intracranial hypertension. A radiological study was performed, showing severe cranio-encephalic trauma and facial injuries. A review of the chest computed tomography revealed a radio-opaque image in the tracheal carina (Fig. 1A). The oral cavity was examined and all teeth were found to

present. Flexible fiberoptic bronchoscopy was performed, showing that the object was a stone measuring 1 cm in its longest diameter. The foreign body had moved to the right primary bronchus so a balloon was used to bring it up to the carina, from where it was extracted (Fig. 1B). After it was removed, the bronchial tree was examined again with fiberoptic bronchoscopy, and no other fragments were found. The patient progressed favorably and could be extubated 48 h after admission.

References

- Madan K, Aggarwal AN, Bhagat H, Singh N. Acute respiratory failure following traumatic tooth aspiration. *BMJ Case Rep.* 2013;201, pii:bcr2012008393.
- Wang L, Pudasaini B, Wang XF. Diagnose of occult bronchial foreign body: a rare case report of undetected Chinese medicine aspiration for 10 long years. *Medicine (Baltimore).* 2016;95:e4076.

[☆] Please cite this article as: Ballesteros MA, Chicote Álvarez E, Mora Cuesta VM. Un caso particular de broncoaspiración de cuerpo extraño en el paciente politraumatizado. *Arch Bronconeumol.* 2017;53:398.

* Corresponding author.

E-mail address: gelesballesteros@yahoo.com (M.A. Ballesteros).