

References

1. Ramos CP, Falsen E, Alvarez N, Akervall E, Sjöden B, Collins MD. *Actinomyces graevenitzi* sp. nov. isolated from human clinical specimens. *Int J Syst Bacteriol.* 1997;47:46–53.
2. Mabeza GF, Macfarlane J. Pulmonary actinomycosis. *Eur Respir J.* 2003;21:545–51.
3. Fujita Y, Iikura M, Horio Y, Ohkusu K, Kobayashi N. Pulmonary *Actinomyces graevenitzi* infection presenting as organizing pneumonia diagnosed by PCR analysis. *J Med Microbiol.* 2012;61:1156–8.
4. Tietz A, Aldridge KE, Figueroa JE. Disseminated coinfection with *Actinomyces graevenitzi* and *Mycobacterium tuberculosis*: case report and review of the literature. *J Clin Microbiol.* 2005;43:3017–22.
5. Katsenos S, Galinos I, Styliara P, Galanopoulou N, Psathakis K. Primary bronchopulmonary actinomycosis masquerading as lung cancer: apropos of two cases and literature review. *Case Rep Infect Dis.* 2015;2015:609637.

Alberto Caballero Vázquez,^{a,*} Juan Jose Cruz Rueda,^b
Julián Andrés Ceballos Gutierrez^c

^a Unidad de Gestión Clínica de Neumología, Complejo Hospitalario Universitario de Granada, Granada, Spain

^b Unidad de Gestión Clínica de Neumología, Hospital Torrecárdenas, Almería, Spain

^c Unidad de Neumología, Servicio de Medicina Interna, Hospital Comarcal de Santa Ana, Motril, Granada, Spain

* Corresponding author.

E-mail address: albertocaballerovarez@yahoo.es

(A. Caballero Vázquez).

1579-2129/

© 2016 SEPAR. Published by Elsevier España, S.L.U. All rights reserved.

***Strongyloides stercoralis* Infection with a Diffuse Miliary Pattern[☆]**



Infección por Strongyloides stercoralis con patrón miliar difuso

To the Editor,

We read with great interest the well-written letter to the editor by Ronda et al.,¹ who reported the case of an 84-year-old man

presenting with severe involvement by *Strongyloides stercoralis* infection. Chest computed tomography (CT) demonstrated consolidation in the left upper lobe, with areas of cavitation with irregular walls. Cytological analysis of bronchial aspirate showed *S. stercoralis* larvae.

We would like to report another case of *S. stercoralis* hyperinfection, with a very uncommon CT pattern: micronodular dissemination. A 73-year-old man was admitted to our hospital with a 2-week history of productive cough, weakness, fever, and

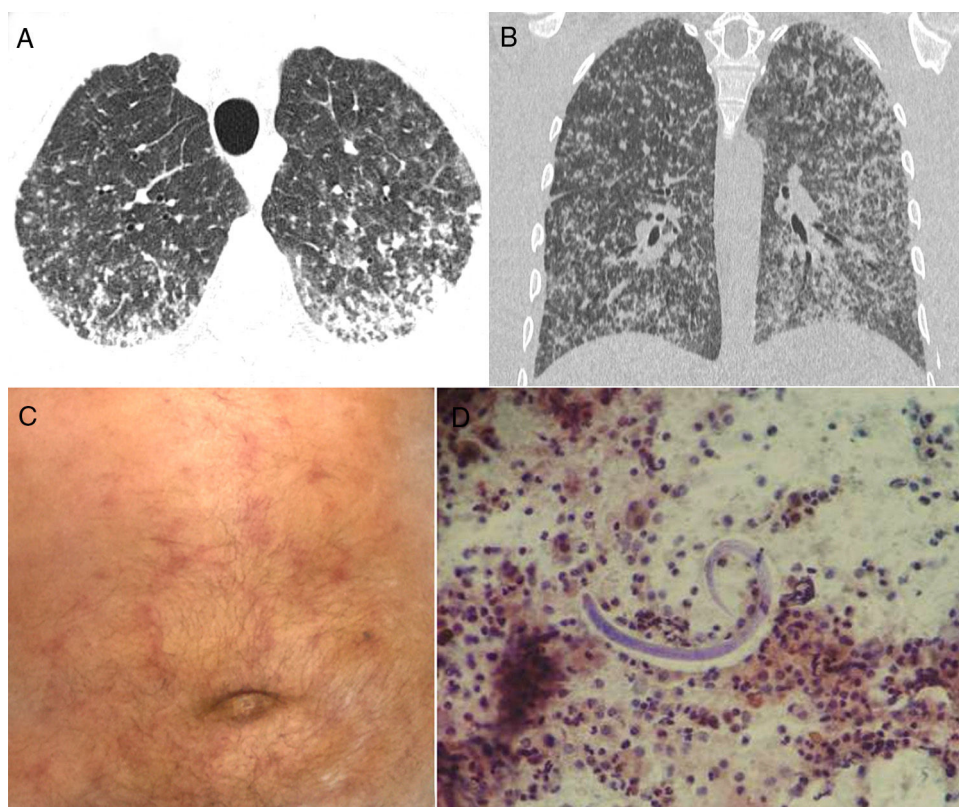


Fig. 1. Axial (A) and coronal (B) reformatted CT images show numerous bilateral small nodules, with some confluence in the posterior and lower lung regions. (C) Physical examination demonstrated a purpuric serpiginous rash on the patient's abdomen. (D) Bronchoalveolar lavage revealed the presence of *Strongyloides stercoralis* filariform larvae.

[☆] Please cite this article as: Hochegger B, Zanetti G, Marchiori E. Infección por *Strongyloides stercoralis* con patrón miliar difuso. *Arch Bronconeumol.* 2017;53:352–353.

progressive dyspnea. He had lost 8 kg weight in 2 months, but had no other complaint. His oxygen saturation in room air was 96%. Laboratory findings were normal. Chest CT revealed numerous bilateral small nodules, with some coalescence in the posterior and lower lung regions (Fig. 1A, B). On day 8, he developed a maculopapular (purpuric) rash (Fig. 1C). Bronchoalveolar lavage (BAL) performed during flexible fiberoptic bronchoscopy revealed the presence of *S. stercoralis* larvae (Fig. 1D). BAL findings for bacteria, fungus, and acid-fast bacteria were negative. Blood cultures were also negative. A stool sample demonstrated numerous larvae, as well as a few adult organisms. The patient was negative for human immunodeficiency virus (HIV), but positive for human T-cell lymphotropic virus (HTLV) I/II quantitative antibodies. A diagnosis of *Strongyloides* hyperinfection syndrome was made, and treatment with ivermectin and albendazole was started.

Strongyloidiasis, an infection caused by the nematode *S. stercoralis*, is prevalent in tropical and subtropical countries.^{2–4} In the setting of severe immunosuppression, the worm may disseminate, causing severe life-threatening syndromes such as hyperinfection and dissemination, showing massive infection.² These syndromes are associated with significant morbidity and mortality.² The clinical diagnosis is often delayed because the clinical and radiographic findings are nonspecific. The most important risk factor for the development of *Strongyloides* infection is residence in or visit to an endemic area.⁵ *S. stercoralis* hyperinfection is generally fatal, as it is normally associated with immunosuppression, either iatrogenic (e.g., caused by systemic corticosteroid use) or to underlying illness (e.g., HIV infection, HTLV-1 carriage, or organ transplantation).^{2,5}

Hyperinfection syndromes manifest clinically in a nonspecific manner, with gastrointestinal and pulmonary symptoms being the most common findings.² The pathognomonic rash of *Strongyloides* infection is a serpiginous and urticarial petechial purpuric eruption over the abdomen and proximal thigh.⁴ Pulmonary symptoms and signs consistent with adult respiratory distress syndrome or intra-alveolar hemorrhage may be seen. Radiographic changes may

include nodular, reticular, and airspace opacities, with distribution ranging from multifocal to lobar.³ Blood eosinophilia is seen in more than 75% of patients with chronic *Strongyloides* infection, but may be absent in immunocompromised patients with hyperinfection syndrome.^{2,3,5} Detection of a large number of larvae in stool and/or BAL fluid or sputum is a hallmark of hyperinfection.⁵ Therefore, the diagnosis rests mainly on the recognition of the organism's morphology in pathology specimens.² In conclusion, in endemic areas, *Strongyloides* hyperinfection should be included in the differential diagnosis of pulmonary miliary lesions.

References

1. Esteban Ronda V, Franco Serrano J, Briones Urriaga ML. Pulmonary *Strongyloides stercoralis* infection. Arch Bronconeumol. 2016;52:442–3.
2. Apewokin S, Steciuk M, Griffin S, Jhala D. *Strongyloides* hyperinfection diagnosed by bronchoalveolar lavage in an immunocompromised host. Cytopathology. 2010;21:345–7.
3. Ali HA, Walkenstein M. Bilateral nodular pulmonary infiltrates in an immunocompromised host. Thorax. 2008;63:753.
4. Harper G, Ong JL, Anasarca, renal failure, hemoptysis, and rash in a 32-year-old male Mexican immigrant. Clin Infect Dis. 2014;59:601–2.
5. Marcos LA, Terashima A, Dupont HL, Gotuzzo E. *Strongyloides* hyperinfection syndrome: an emerging global infectious disease. Trans R Soc Trop Med Hyg. 2008;102:314–8.

Bruno Hochhegger,^a Gláucia Zanetti,^b Edson Marchiori^{b,*}

^a Irmandade Santa Casa de Misericórdia de Porto Alegre, Rio Grande do Sul, Brazil

^b Department of Radiology, Federal University of Rio de Janeiro, Rio de Janeiro, Brazil

* Corresponding author.

E-mail address: edmarchiori@gmail.com (E. Marchiori).

1579-2129/

© 2016 SEPAR. Published by Elsevier España, S.L.U. All rights reserved.

Pulmonary Disease Caused by *Mycobacterium szulgai*[☆]



Enfermedad pulmonar producida por *Mycobacterium szulgai*

To the Editor,

Mycobacterium szulgai is slow-growing, rarely isolated environmental non-tuberculous mycobacterium (NTM).¹ It accounted for less than 0.2% of isolated strains in a study of over 36 000 NTM samples from 14 countries, including Spain.² Like other NTM, it can be present in dust, soil, water, plants, and animals.³ Isolation from the respiratory tree does not always imply disease, so the American Thoracic Society and the Infectious Diseases Society of America have produced a series of diagnostic criteria in an attempt to establish the pathogenic role of this and other NTM when isolated from biological samples.⁴

We report the case of a 49-year-old woman, employed as a cleaner, smoker of 35 pack-years, chronic alcoholic with moderate COPD, who was transferred by ambulance to the emergency department in coma (Glasgow scale 3), shock (BP 50/30 mmHg) and respiratory failure (SO₂ 75% with FIO₂ 0.21), where she was intubated and mechanical ventilation was applied, with administration

of vasoactive amines and admission to the ICU. Two months previously she had reported general malaise, 10 kg weight loss, and in the last week, fever of up to 39 °C, cough and mucopurulent expectoration.

Examination showed that she was severely underweight (BMI 14.2), with global loss of breath sounds in both pulmonary fields. Analytical parameters on admission were 16 200 leukocytes/mm³ (81% neutrophils, 9% lymphocytes, and 10% monocytes), ESR 11 mm/h, blood glucose 174 mg/dl, AP 133 IU/l, gamma GT 231 IU/l, LDH 392 IU/l, and high-sensitivity C-reactive protein 9 mg/dl. Other parameters – complete blood count, hemostasis and biochemistry – were normal, including procalcitonin and immunoglobulins. Urine sample was negative for *Streptococcus pneumoniae* antigen and positive for *Legionella pneumophila* serogroup 1 antigen, so the initial empirical treatment with ceftriaxone and azithromycin was switched to levofloxacin.

Chest radiograph revealed fibrocavitary tracts in both upper fields with signs of air trapping, confirmed on CT (Fig. 1). No particular findings were revealed in the head or the abdomen. Fiberoptic bronchoscopy was performed, showing signs of inflammation of the bronchial mucosa, and bronchial aspirates were obtained for standard and mycobacterial culture. Standard culture techniques showed growth of saprophytic flora, with no *Legionella* spp. or fungal strains. No alcohol-acid resistant bacilli (AARB) were observed on Ziehl-Neelsen staining. A serology study for HIV and IgM antibodies against *Mycoplasma pneumoniae*, *Coxiella burnetii*, *Chlamydia pneumoniae*, *Legionella pneumophila* and

[☆] Please cite this article as: Milagro Beamonte A, Briz Muñoz E, Torres Sopena L, Borderías Clau L. Enfermedad pulmonar producida por *Mycobacterium szulgai*. Arch Bronconeumol. 2017;53:353–354.