

## References

- Rodríguez-Frías F, Miravittles M, Vidal R, Camos S, Jardi R. Rare alpha-1-antitrypsin variants: are they really so rare? *Ther Adv Respir Dis*. 2012;6:79–85.
- Piras B, Ferrarotti I, Lara B, Martínez MT, Bustamante A, Ottaviani S, et al. Clinical phenotypes of Italian and Spanish patients with alpha1-antitrypsin deficiency. *Eur Respir J*. 2013;42:54–64.
- Reid CL, Wiener GJ, Cox DW, Richter JE, Geisinger KR. Diffuse hepatocellular dysplasia and carcinoma associated with the Mmalton variant of alpha 1-antitrypsin. *Gastroenterology*. 1987;93:181–7.
- Curiel DT, Holmes MD, Okayama H, Brantly ML, Vogelmeier C, Travis WD, et al. Molecular basis of the liver and lung disease associated with the alpha 1-antitrypsin deficiency allele Mmalton. *J Biol Chem*. 1989;264:13938–45.
- Sproule BJ, Cox DW, Hsu K, Salkie ML, Herbert FA. Pulmonary function associated with the Mmalton deficient variant of alpha 1-antitrypsin. *Am Rev Respir Dis*. 1983;127:237–40.
- Canva V, Piotte S, Aubert JP, Porchet N, Lecomte-Houcke M, Huet G, et al. Heterozygous M3Mmalton alpha1-antitrypsin deficiency associated with end-stage liver disease: case report and review. *Clin Chem*. 2001;47:1490–6.
- Ferrarotti I, Baccheschi J, Zorzetto M, Tinelli C, Corda L, Balbi B, et al. Prevalence and phenotype of subjects carrying rare variants in the Italian registry for alpha 1-antitrypsin deficiency. *J Med Genet*. 2005;42:282–7.

Juan Marco Figueira Gonçalves,<sup>a,\*</sup> Francisco Martínez Bugallo,<sup>b</sup> David Díaz Pérez,<sup>a</sup> María Dolores Martín Martínez,<sup>b</sup> Ignacio García-Talavera<sup>a</sup>

<sup>a</sup> Servicio de Neumología y Cirugía Torácica, Hospital Universitario Nuestra Señora de la Candelaria, Santa Cruz de Tenerife, Tenerife, Spain

<sup>b</sup> Unidad de Genética, Servicio de Análisis Clínicos, Hospital Universitario Nuestra Señora de la Candelaria, Santa Cruz de Tenerife, Tenerife, Spain

\* Corresponding author.

E-mail address: [juanmarcofigueira@gmail.com](mailto:juanmarcofigueira@gmail.com)

(J.M. Figueira Gonçalves).

## Hering-Breuer Reflex and Non-invasive Mechanical Ventilation. Does it Also Occur During Expiration?\*



### Reflejo de Hering-Breuer y ventilación mecánica no invasiva ¿también durante la espiración?

Dear Editor:

Interpreting and evaluating the importance of patient-ventilator asynchronies in non-invasive mechanical ventilation (NIMV) is an extremely difficult task. Some of the experiences published in the literature suggest that some asynchronies detected in clinical practice are directly induced by the ventilator, as muscles respond to mechanical stimuli. For example, the phenomenon known as “reverse triggering”<sup>1</sup> has been described in profoundly sedated adult patients receiving invasive ventilation and may be a new form of diaphragmatic neuromechanical coupling, induced by a reflex mediated by the stretch receptors during inspiration (Hering-Breuer reflex). This phenomenon has only been described in sedated patients receiving invasive ventilation, and to date no cases of muscle response to mechanical stimuli have been described in patients receiving NIMV.

We report the case of a 62-year-old woman with amyotrophic lateral sclerosis, with predominant upper neuron involvement and significant hyperreflexia. NIMV was indicated due to forced vital capacity below 50% predicted value, mild hypercapnia (PaCO<sub>2</sub> 46 mmHg) and incipient intolerance to a decubitus position. Titration began with a nasal interface and chinstrap for periods of 1–2 h on consecutive days with a Lumis® 150 pressure ventilator (ResMed, North Ryde, Australia). Parameters at the end of the first session were: IPAP 18 cmH<sub>2</sub>O, EPAP 5 cmH<sub>2</sub>O, rise time 150 ms, Timin 0.6 s and Timax 1.5 s, triggering and cycling settings at mean values. Unintentional leak was maintained at acceptable values after a chinstrap was placed (less than 10 l/min overall), and breathing rate was around 18–20 bpm. During real time monitoring of pressure-time and flow-time curves, deflection was observed at the start of flow-time waveform expiration, despite good initial tolerance (Fig. 1A).

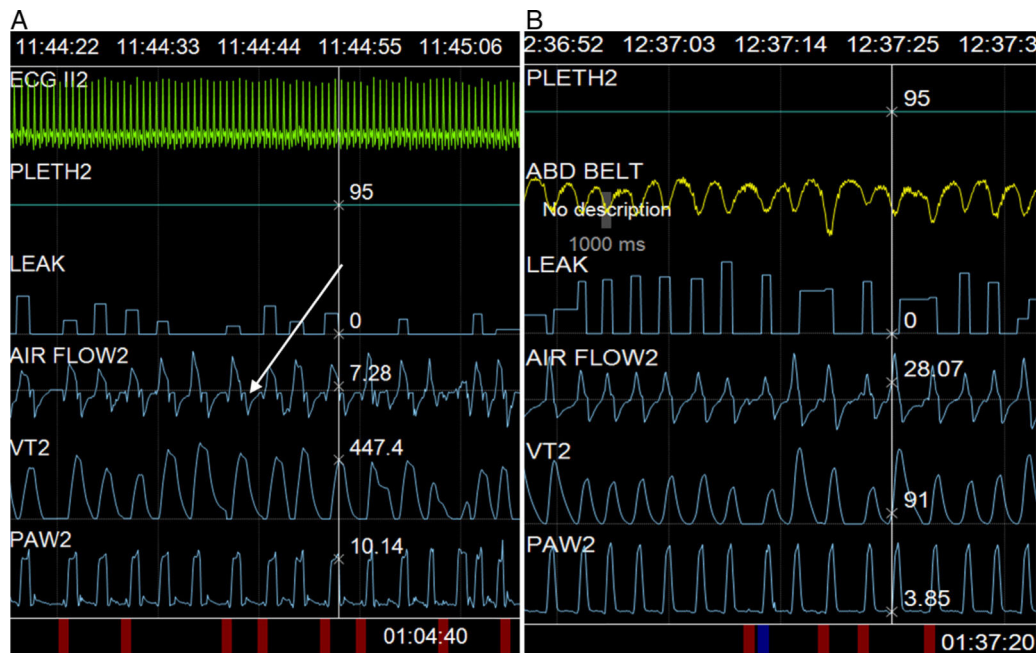
Since deflection occurred at the start of expiration, with persistent exertion during this phase (premature cycling asynchrony<sup>2</sup>), the cycling setting was modified, prolonging rise time to 250 ms (in order to delay maximum flow, and thus, cycling), and Timin of 0.8 was superimposed, but the abnormality persisted. Finally, while previous rise time values were maintained without superimposing the time criterion, the deceleration ramp was modified from inspiration to expiration, and was set at 250 ms, with subsequent resolution of the disorder (Fig. 1B).

The abnormality could be resolved only by modifying the descent time in this patient with marked hyperreflexia, suggesting that the visible alteration in flow-time curves might be due to an automatic response of the patient’s respiratory system. This is similar to the situation described by Akoumianaki et al.,<sup>1</sup> although these authors described the phenomenon in patients receiving sedation and relaxation. Instead of being a chest expansion reflex, the response appears to be associated more with a deflation reflex that remains relatively constant from cycle to cycle.

Not all ventilator models record deceleration. To date, its use in clinical practice has not been reported in the literature, although, theoretically at least, it should improve tolerance to the sudden flow inversion that occurs during the transition from inspiration to expiration. Most of the time this flow inversion, that may be as high as 80 lx’ [although in our patient it was around 60 lx’ (20–40 lx’)] does not produce any symptoms, but some patients might report discomfort. In our patient, the flow inversion appeared to trigger an automatic respiratory response, intensified by concomitant generalized hyperreflexia. Amyotrophic lateral sclerosis may present in different forms, not only in terms of muscle topography, but also in the degree of spasticity and hyperreflexia. Thus, predominant lower motor neuron involvement produces weakness and atrophy, while upper motor neuron involvement produces basically spastic hypertonia and hyperreflexia that can affect any muscle group. Reflecting findings made first in animal models and later in patients,<sup>3</sup> our patient’s diaphragm may have been activated due to deflation in the presence of vagal nerve integrity. This anomaly can also be observed on spirometry in forced expiratory maneuvers, when cough is induced by maximum expiration (Fontana reflex).<sup>4</sup>

In conclusion, patient-ventilator asynchrony observed in our patient does not appear to be the same as cases previously described in the literature, since it does not meet the characteristics of premature cycling (it is not modified by prolonging inspiratory time or cycling settings) or reverse triggering (the cycle before the asynchrony is not controlled). For this reason, diaphragmatic

\* Please cite this article as: Galdeano M, Luján M. Reflejo de Hering-Breuer y ventilación mecánica no invasiva ¿también durante la espiración? *Arch Bronconeumol*. 2016;52:618–619.



**Fig. 1.** Screenshot obtained during ventilation adaptation. (A) The deflection mentioned in the text can be observed (arrow) and (B) resolution after setting a deceleration ramp of 250 ms.

activation during transition to expiration may be a plausible interpretation that would explain the persistence of asynchrony and improvement with progressive depressurization.

## References

1. Akoumianaki E, Lyazidi A, Rey N, Matamis D, Pérez-Martínez N, Giraud R, et al. Mechanical ventilation-induced reverse-triggered breaths: a frequently unrecognized form of neuromechanical coupling. *Chest*. 2013;143:927–38.
2. Vignaux L, Vargas F, Roeseler J, Tassaux D, Thille AW, Kossowsky MP, et al. Patient-ventilator asynchrony during non-invasive ventilation for acute respiratory failure: a multicenter study. *Intensive Care Med*. 2009;35:840–6.
3. Lavorini F, Fontana GA, Chellini E, Magni C, Pistolesi M, Widdicombe J. Respiratory expulsive efforts evoked by maximal lung emptying. *Chest*. 2011;140:690–6.
4. Lavorini F, Fontana G, Chellini E, Magni C, Pistolesi M, Widdicombe J. The Fontana paradoxical reflex? *Chest*. 2011;140:586–8.

Marina Galdeano,<sup>a,\*</sup> Manel Luján<sup>b,c</sup>

<sup>a</sup> Unitat de Cures Respiratòries Intermèdies, Servei de Pneumologia, Hospital Universitari Sagrat Cor, Universitat de Barcelona, Barcelona, Spain

<sup>b</sup> Servei de Pneumologia, Hospital de Sabadell, Corporació Parc Taulí, Universitat Autònoma de Barcelona, Sabadell, Barcelona, Spain

<sup>c</sup> CIBER de Enfermedades Respiratorias (CIBERES), Spain

\* Corresponding author.

E-mail address: [marinagaldeano@gmail.com](mailto:marinagaldeano@gmail.com) (M. Galdeano).

## NUT Midline Carcinoma of the Lung, A Rare Form of Lung Cancer<sup>☆</sup>



### *Carcinoma NUT pulmonar, una forma poco frecuente de cáncer de pulmón*

Dear Editor:

Nuclear carcinoma of the testis (NUT) is very rare tumors with specific genetic changes that progress very aggressively. They often affect children and young adults. They may occur in different organs, but they are characteristically located in the midline of the head and neck.<sup>1</sup> Very few cases have been published that describe this entity in the lungs and mediastinum.

We report the case of a 23-year-old man, smoker of about 10 cigarettes/day, who presented in our hospital with a 2-week history of pain in the right hemithorax radiating to the shoulder, and asthenia. Computed tomography (CT) showed increased density without air bronchogram occupying the posterior and apical segments of the right upper lobe (RUL) with amputation of the corresponding segmentary bronchi, paratracheal mediastinal lymphadenopathies, and significant right pleural effusion (Fig. 1). Given these findings, a positron emission tomography (PET) was performed, revealing a metabolically positive mass in the RUL, with extensive pleural involvement in the same side, mediastinal lymph node involvement, and bilateral supra/infraclavicular lytic bone lesions and metastasis. Fiberoptic bronchoscopy revealed complete stenosis of the posterior and apical segments of the RUL bronchus due to thickened, hypervascularized mucosa, possibly of a neoformative origin. Diagnostic confirmation was obtained from a pleural biopsy obtained by thoracoscopy. The pathology report described a neoplasm formed of nests of undifferentiated cells, and, along with this cell population, abrupt areas of squamous differentiation. The

<sup>☆</sup> Please cite this article as: Benito Bernáldez C, Romero Muñoz C, Almadana Pacheco V. Carcinoma NUT pulmonar, una forma poco frecuente de cáncer de pulmón. *Arch Bronconeumol*. 2016;52:619–621.