

Clinical Image

Complete Tracheal Resection in Closed Cervical Spine Injury[☆]



Sección traqueal completa por traumatismo cervical cerrado

Carmen María Rodríguez Gómez,* Matilde Rubio Garay, Xavier Baldó Padró

Servicio de Cirugía Torácica, Hospital Josep Trueta, Girona, Spain

We report the case of a 17-year-old male patient with closed cervical spine injury due to a traffic accident, hemodynamically stable, with continuous desaturations requiring orotracheal intubation. Computed tomography performed in our hospital revealed complete cervical tracheal disruption with a 5 cm proximal to distal dehiscence, with the orotracheal tube located in the mediastinum (Fig. 1A and B). Given these findings, emergency surgery was performed, with anterior transverse cervicotomy and intrafield intubation (Fig. 1C), and end-to-end tracheal anastomosis with unloading distal tracheotomy. The patient was extubated on the third day after surgery, and discharged 9 days after the intervention, with withdrawal of the tracheotomy tube and closure after confirmation of airway patency and adequate gastrointestinal ingestion. Six months later, dysphonia persisted due to paralysis of both vocal cords in the paramedian position.

Complete tracheal disruption caused by high impact closed cervical spine injuries is rare,¹ occurring at an incidence of approximately 1%, but it is potentially fatal and requires immediate

diagnosis and therapeutic intervention.² Phonatory and respiratory function may be compromised by paresis or paralysis of the vocal cords caused by unilateral or bilateral avulsion of the recurrent nerve.

Acknowledgements

We thank Dr. Tobed of the ENT Department of the Hospital Josep Trueta for his help in the surgical intervention and subsequent follow-up of the patient.

References

- Swoboda L, Walz H, Kirchner R, Wertzel H, Hasse J. Tracheal and bronchial rupture after blunt thoracic trauma. *Zentralbl Chir.* 1993;118:47–52.
- Yamanda T, Aoki T, Kaneko K, Miyazawa M, Yoshida K, Haniuda M. Complete disruption of the trachea due to blunt neck trauma. *Nihon Kyobu Geka Gakkai Zasshi.* 1995;43:543–6.

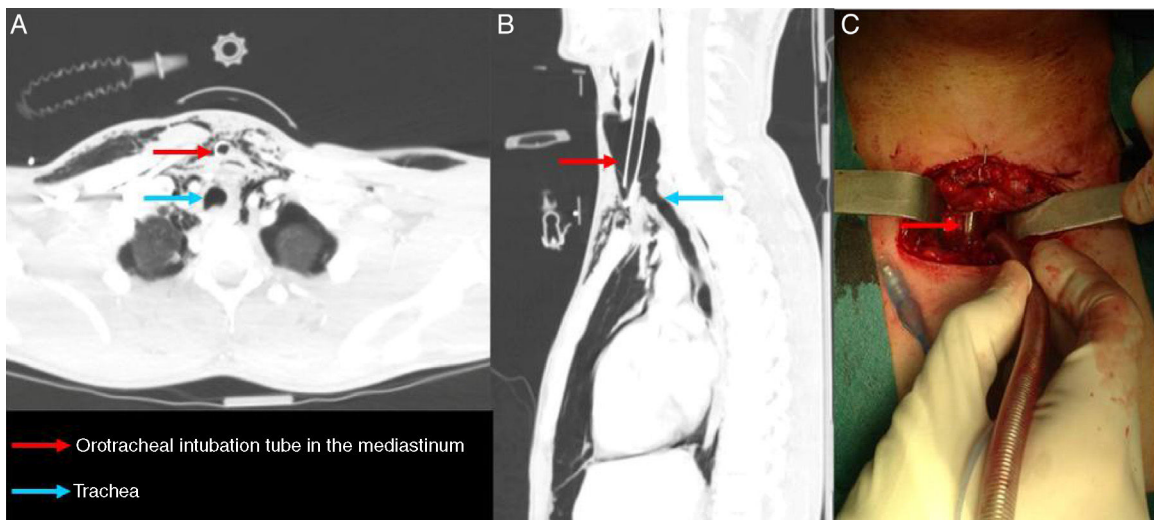


Fig. 1. (A) Axial computed tomography (CT) slice. (B) Sagittal CT slice. (C) Surgical image with intraoperative distal intubation.

[☆] Please cite this article as: Rodríguez Gómez CM, Rubio Garay M, Baldó Padró X. Sección traqueal completa por traumatismo cervical cerrado. *Arch Bronconeumol.* 2016;52:614.

* Corresponding author.

E-mail address: mia.2612@hotmail.com (C.M. Rodríguez Gómez).