

Clinical Image

**Malignant Melanoma Metastasis in the Form of Nonsolid Nodules:
Diagnosis by Percutaneous Lung Biopsy[☆]**



**Metástasis de melanoma maligno en forma de nódulos no sólidos: diagnóstico mediante
biopsia pulmonar percutánea**

Ivan Vollmer,^{a,*} José Ramírez,^b Marcelo Sánchez^a

^a Servicio de Radiodiagnóstico (CDIC), Hospital Clínic, Barcelona, Spain

^b Servicio de Anatomía Patológica (CDB), Hospital Clínic, Barcelona, Spain

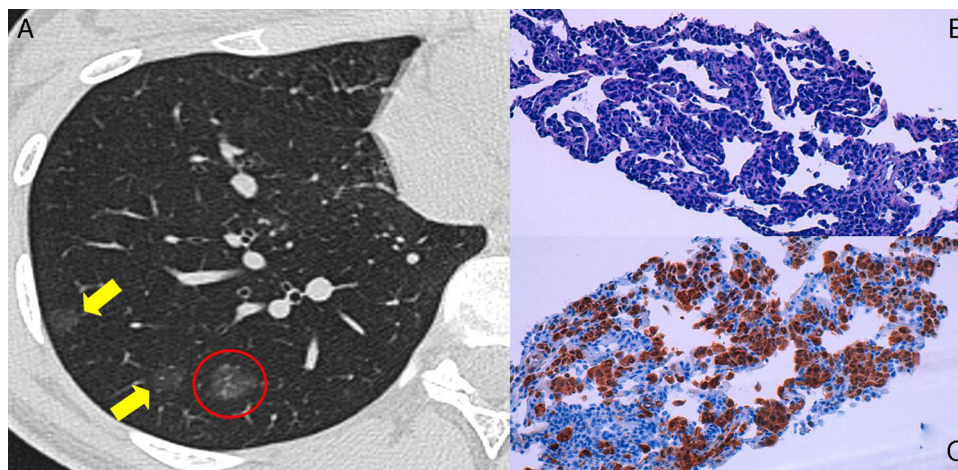


Fig. 1. Computed tomography image (A) showing multiple nonsolid nodules (arrows) in the right lung. The nonsolid nodule that was biopsied is indicated within the red circle. Microscopic images (250 \times) of the lung biopsy (B and C), showing interstitial infiltration by the cancer cells on hematoxylin–eosin staining (B). S100 protein positivity indicates melanocytic differentiation (C).

We report the case of a 20-year old patient with a diagnosis of malignant melanoma in the presteral region (Clark level III, Breslow 3.56), treated with excisional biopsy and subsequent widening of surgical margins and sentinel node detection.

The patient was monitored by computed tomography (CT), which, 15 months after surgery, revealed multiple nonsolid nodules on both lungs. A follow-up CT in 3 months was recommended, and

this scan revealed persistent nodular lesions, increased in size and density (Fig. 1A). In view of the clinical suspicion of lung metastasis, a CT-guided percutaneous biopsy was performed, which confirmed the diagnosis.

Although most persistent nonsolid lesions are lesions within the lung adenocarcinoma spectrum, the differential diagnosis must include metastases from gastrointestinal cancers, melanoma, and renal carcinoma.

[☆] Please cite this article as: Vollmer I, Ramírez J, Sánchez M. Metástasis de melanoma maligno en forma de nódulos no sólidos: diagnóstico mediante biopsia pulmonar percutánea. Arch Bronconeumol. 2016;52:433–434.

* Corresponding author.

E-mail address: vollmer@clinic.ub.es (I. Vollmer).

There are only 2 reports in the literature of melanoma lung metastasis in the form of nonsolid nodules which required surgical biopsy for confirmation.^{1,2} In our case, percutaneous biopsy showed typical melanoma cell growth, with infiltration of the alveolar septa and preservation of air spaces (Fig. 1B and C), conferring the appearance of a nonsolid nodule on CT.

References

1. Okita R, Yamashita M, Nakata M, Teramoto N, Bessho A, Mogami H. Multiple ground-glass opacity in metastasis of malignant melanoma diagnosed by lung biopsy. *Ann Thorac Surg.* 2005;79, e1–2.
2. Kang MJ, Kim MA, Park CM, Lee CH, Goo JM, Lee HJ. Ground-glass nodules found in two patients with malignant melanomas: different growth rate and different histology. *Clin Imaging.* 2010;34:396–9.