



Clinical Image

## Calcium Pill Aspiration<sup>☆</sup>

### Aspiración de un comprimido de calcio

Sumedh S. Hoskote, Ali I. Saeed\*

Division of Pulmonary Critical Care and Sleep Medicine, Mayo Clinic, Rochester, Olmsted, MN, United States



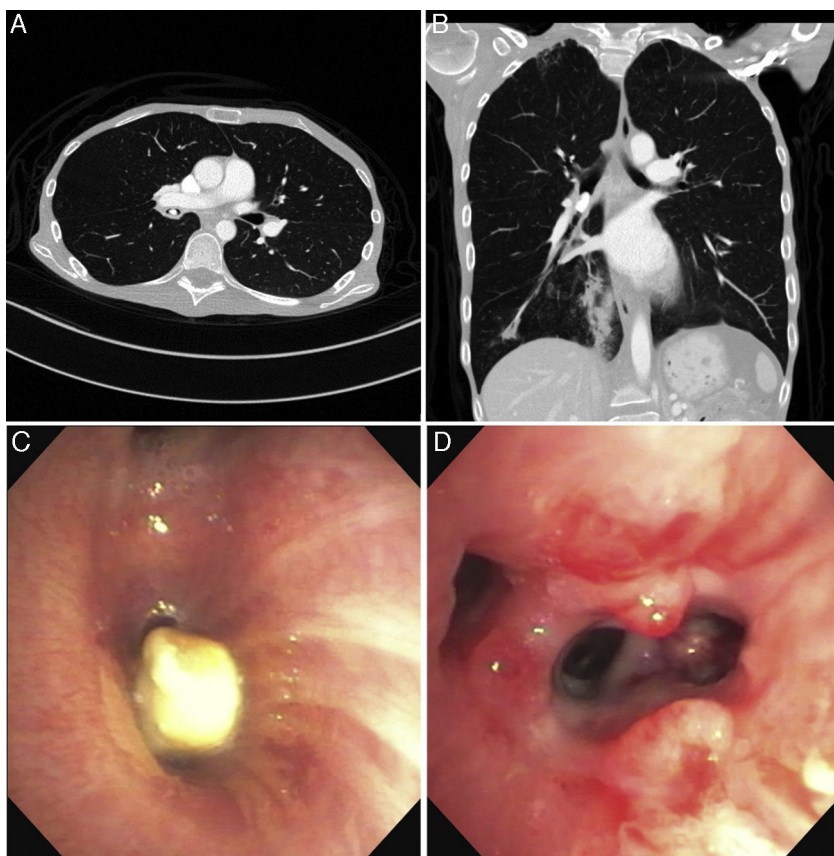
A 44-year-old female with malnutrition, myopathy secondary to disuse or malnutrition, and mast cell activation syndrome initially presented with a 3-month history of worsening shortness of breath and occasional cough. She was referred to bronchoscopy after being found to have an endobronchial lesion on chest computed tomography (Fig. 1, top panel). A clinical suspicion of endobronchial carcinoid was raised due to persistent and severe diarrhea. Flexible bronchoscopy revealed a foreign body in the bronchus intermedius (Fig. 1, bottom panel) which was removed using a wire basket. Extensive granulation tissue was noted in

the bronchus intermedius around the foreign body and copious purulent secretions were aspirated. The size and appearance of the foreign body was consistent with the patient's calcium citrate once-a-day pill; however, she did not recall the aspiration event. Aspiration of multivitamin or calcium tablets is rarely reported,<sup>1,2</sup> possibly due to their size. It is not known whether a calcium pill may spontaneously dissolve if the patient is unable to cough it up. In our patient, the high radio-density (mean 576 Hounsfield Units) and its sharp edges suggested pill aspiration.

<sup>☆</sup> Please cite this article as: Hoskote SS, Saeed AI. Aspiración de un comprimido de calcio. Arch Bronconeumol. 2017;53:27–28.

\* Corresponding author.

E-mail addresses: [saeed.ali@mayo.edu](mailto:saeed.ali@mayo.edu), [sumedh.hoskote@gmail.com](mailto:sumedh.hoskote@gmail.com) (A.I. Saeed).



**Fig. 1.** Top panel shows the axial (left) and coronal (right) appearance of the aspirated pill on CT chest. The bottom panel shows the bronchoscopic appearance of the pill (left) and the intense granulation tissue reaction seen after pill removal (right).

## References

1. Micallef J, Montefort S, Mallia Azzopardi C, Galea J. Two cases of aspiration of calcium tablets. *Lung India*. 2011;28:312–4.
2. Limper AH, Prakash UB. Tracheobronchial foreign bodies in adults. *Ann Intern Med*. 1990;112:604–9.