

Several factors intervened in our choice of a conservative approach: (a) control of bleeding due to the obliteration of the vessel by mediastinal hematoma; (b) the resolution of blood effusion in the pleural cavity after VAT; (c) previous myocardial revascularization (using the left internal mammary artery) with mediastinal fibrosis, making open BAA access difficult; (d) good hemodynamic status. In view of the patient's stable condition, we used VAT as a first-line approach. Moreover, sinus tachycardia and hyperventilation could be symptoms of a worsening general status, requiring an urgent non-targeted approach. Video-assisted thoracoscopy has proved to be ideal for emptying and cleaning the pleural cavity and allowed us to determine that the bleeding originated in the mediastinum (Fig. 1).

References

1. Furuse M, Saito K, Kunieda E, Aihara T, Touei H, Ohara T, et al. Bronchial arteries: CT demonstration with arteriographic correlation. *Radiology*. 1987;162:393-8.

2. Mizuguchi S, Inoue K, Kida A, Isota M, Hige K, Aoyama T, et al. Ruptured bronchial artery aneurysm associated with bronchiectasis: a case report. *Ann Thorac Cardiovasc Surg*. 2009;15:115-8.
3. Hung SW. Where is the ruptured bronchial artery aneurysm. *Eur J Cardiothorac Surg*. 2010;38:389-90.
4. Yoon W, Kim JK, Kim YH, Chung TW, Kang HK. Bronchial and nonbronchial systemic artery embolization for life-threatening hemoptysis: a comprehensive review. *Radiographics*. 2002;22:1395-409.
5. Tanaka K, Ihaya A, Horiuchi T, Morioka K, Kimura T, Uesaka T, et al. Giant mediastinal bronchial artery aneurysm mimicking benign esophageal tumor: a case report and review of 26 cases from literature. *J Vasc Surg*. 2003;38:1125-9.

Duilio Divisi,* Andrea de Vico, Roberto Crisci

Department of Thoracic Surgery, University of L'Aquila, "G. Mazzini" Hospital, Teramo, Italy

* Corresponding author.

E-mail address: duilio.divisi@aslteramo.it (D. Divisi).

Keratinolytic Fungi in the Feather Stuffing of a Sofa: A Rare Cause of Hypersensitive Pneumonitis[☆]



Hongos queratinolíticos en el relleno de plumas de un sofá: una causa poco frecuente de neumonitis por hipersensibilidad

Clinical Case Report

We report the case of a 56-year-old man, former smoker, with a history of dyslipemia, gastroesophageal reflux, and idiopathic pulmonary fibrosis, referred from another hospital for investigation of progressive interstitial disease. He had been employed as a firefighter and a farm worker. He had contact with chickens and also had a feather sofa. No significant family history was reported.

One year previously, he had presented with pleuritic central chest pain, fever, dry cough, and progressive dyspnea, initially thought to be idiopathic pulmonary disease. All possible sources of domestic exposure were ruled out, and the patient was treated with prednisone 30 mg/day for 3 months, and then with N-acetylcysteine 1800 mg/day, but continued to deteriorate clinically. On physical examination, crackles were heard on lung auscultation and nail clubbing was noted. Autoimmune markers were normal. The only significant finding was raised anti-*Aspergillus fumigatus* and anti-*Penicillium* spp. IgG antibodies. Lung function testing showed forced expiratory volume in 1 s (FEV1) of 62%, forced vital capacity (FVC) 62%, FEV1/FVC ratio of 76%, generally reduced lung volumes, and diffusing capacity for carbon monoxide of 54%. He had moderate hypoxemia and normocapnia. In the walk test, he achieved 600 m, with oxygen saturation falling to 87%. Computed tomography showed a pattern inconsistent with usual interstitial pneumonia (Fig. 1). Bronchoalveolar lavage was performed, revealing cellularity and predominant neutrophils. Cryobiopsy was also obtained from the right basal segment. Histology examination showed pulmonary parenchyma with predominantly reactive interstitial histiocytosis suggestive of hypersensitive pneumonitis.

We suspected that some contact element was causing the clinical picture, so feathers from the sofa were cultivated and *Aspergillus fumigatus* was isolated. The case was diagnosed as chronic hyper-

sensitive pneumonitis (HP), caused by exposure to this mold. Treatment began with prednisone 30 mg/day, and exposure to the antigen was eliminated. Clinical and functional improvement occurred within a few months.

Discussion

This is the first reported case of HP caused by exposure to the feather stuffing of a sofa colonized by *Aspergillus fumigatus*.

Differential diagnosis between advanced chronic HP and idiopathic pulmonary fibrosis is difficult and can only be achieved by intensive investigation of potential exposure to antigens.^{1,2} Some molds (*Aspergillus*, *Acremonium*, *Alternaria*, *Beuveria*, *Curvularia*, *Paecilomyces* and *Penicillium*) synthesize keratinases, which degrade keratin in feathers.³ If the clinical picture is compatible, the presence of disease should be considered in patients with raised IgG antibodies to these antigens.^{4,5} In our case, anti-*Aspergillus fumigatus* IgG levels were very high, and as this mold was found in an element to which the patient was continually exposed, this anti-

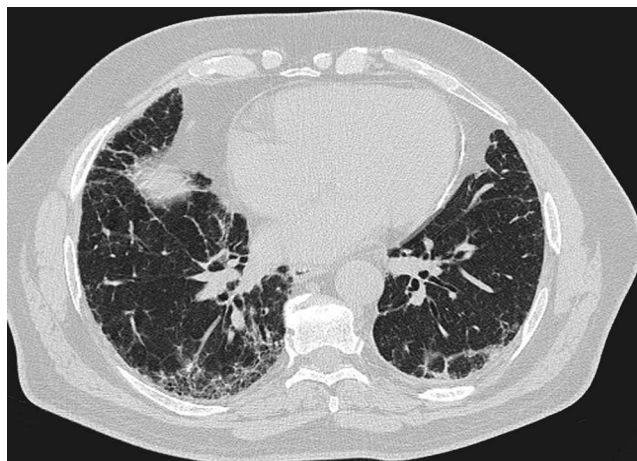


Fig. 1. High-resolution computed tomography of the chest showing subpleural reticular opacities with traction bronchiectasis and subpleural honeycombing images, mainly in the lower lobes. No evaluable air trapping is seen in the sections on expiration. These images suggest a pattern consistent with usual interstitial pneumonia (according to the ATS/ERS/JRS/ALAT consensus criteria on the diagnosis and management of idiopathic pulmonary fibrosis, 2011).

[☆] Please cite this article as: Hernandez-Gonzalez F, Xaubet A, Sellarés J. Hongos queratinolíticos en el relleno de plumas de un sofá: una causa poco frecuente de neumonitis por hipersensibilidad. *Arch Bronconeumol*. 2015;51:474-475.

gen was assumed to be the principal cause of HP and worsening symptoms.

In conclusion, diagnosis was possible in this case due to detection of the source antigen by culture of feathers from the patient's sofa. This experience may be useful in patients with precipitin reactions positive for molds and suspected HP, for whom no other exposure is detected in their case history.

Funding

This study did not receive funding of any type.

Conflict of Interests

The authors state that they have no conflict of interests.

References

1. Selman M, Pardo A, King TE Jr. Hypersensitivity pneumonitis: insights in diagnosis and pathobiology. *Am J Respir Crit Care Med.* 2012;186:314-24.

2. Morell F, Villar A, Montero MA, Munoz X, Colby TV, Pipvath S, et al. Chronic hypersensitivity pneumonitis in patients diagnosed with idiopathic pulmonary fibrosis: a prospective case-cohort study. *Lancet Respir Med.* 2013;1:685-94.
3. Travis WD, Costabel U, Hansell DM, King TE Jr, Lynch DA, Nicholson AG, et al. An official American Thoracic Society/European Respiratory Society statement: update of the international multidisciplinary classification of the idiopathic interstitial pneumonias. *Am J Respir Crit Care Med.* 2013;188:733-48.
4. Kornilowicz-Kowalska T, Bohacz J. Biodegradation of keratin waste: theory and practical aspects. *Waste Manag.* 2011;31:1689-701.
5. Morell F, Roger A, Reyes L, Cruz MJ, Murio C, Munoz X. Bird fancier's lung: a series of 86 patients. *Medicine (Baltim).* 2008;87:110-30.

Fernanda Hernandez-Gonzalez, Antoni Xaubet, Jacobo Sellarés*

Servicio de Neumología, Institut del Tórax, Hospital Clínic, Barcelona, Spain

* Corresponding author.

E-mail address: sellares@clinic.ub.es (J. Sellarés).

Shrinking Lung in Primary Sjögren Syndrome Successfully Treated With Rituximab[☆]



Síndrome del pulmón encogido en el síndrome de Sjögren primario tratado con éxito con rituximab

To the Editor,

Shrinking lung syndrome (SLS) is a rare complication of Sjögren's syndrome. We report the case of a woman diagnosed 5 years previously with primary Sjögren's syndrome (pSS) who presented SLS. She received steroids, azathioprine and cyclophosphamide, with no response, yet showed remarkable clinical and functional improvement after starting treatment with rituximab.

A 47-year-old woman, with a 5-year diagnosis of pSS, was hospitalized for an 8-week history of left pleuritic pain, discomfort in both sides of the chest and dyspnea on medium effort. Initially, she had been given a presumed diagnosis of right lower lobe pneumonia, but did not respond to treatment. On examination, her breathing rate was 22 breaths/minute, and reduced breath sounds were detected in the right lung base. Chest X-ray showed loss of volume in the right hemithorax and computed tomography angiography revealed areas of atelectasis in the right basal subsegment, right hemidiaphragm elevation, minimal left pleural thickening, and no evidence of pulmonary embolism. Lung function tests showed a severe restrictive pattern. Fiberoptic bronchoscopy was performed and no changes were observed. Electromyography of the phrenic nerve showed signs of partial axonotmesis.

SLS was diagnosed and the dose of prednisone was increased to 45 mg/day. Inhaled salbutamol and theophylline were added, but dyspnea and lung function failed to improve after 3 months of treatment. In view of this lack of response, azathioprine and later cyclophosphamide were added, but no clinical or functional response was observed. We then decided to try i.v. administration of anti-CD20 monoclonal antibody (rituximab) 1 g repeated after 2 weeks. Clinical, radiological and functional improvement was achieved (Fig. 1), and the patient remained asymptomatic 2 years later.

Shrinking lung syndrome (SLS) is a complication that has been described in some (0.9%) patients with systemic lupus erythematosus (SLE).¹ It is, however, exceptional in other autoimmune diseases.² It most commonly presents with dyspnea, persistent episodes of chest pain, progressive loss of lung volume, and absence of significant interstitial and/or pleural disease on computed tomography.¹ Its pathogenesis is still a source of controversy, and many hypotheses have been proposed.³ In 1965, Hoffbrand and Beck suggested that microatelectasis and hyaline membranes caused by surfactant deficiency may be involved. Other authors considered SLS to be a form of diaphragmatic myopathy and phrenic nerve neuropathy, but none of these theories could be demonstrated in subsequent studies.³ In our patient, changes in the electromyography consistent with partial axonotmesis were found, and we concluded that right phrenic neuropathy was the probable causative mechanism. Treatment with corticosteroids can reduce symptoms and improve lung function, but other treatments have provided benefit in some patients, including theophylline and immunosuppressive agents, such as cyclophosphamide and azathioprine.¹⁻³ Three cases of good therapeutic response to rituximab have been reported, all in SLE patients.^{4,5} Although SLS can be successfully treated with steroids, salbutamol and theophylline in most cases, it can be a source of significant morbidity and occasionally mortality – in one report, it was impossible to wean the patient from the ventilator.³

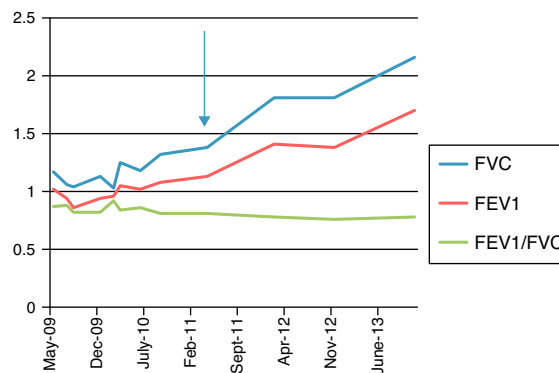


Fig. 1. Lung function tests between May 2009 and June 2013. The arrow indicates start of treatment with rituximab. FEV1: forced expiratory volume in 1 second; FVC: forced vital capacity.

[☆] Please cite this article as: Blanco Pérez JJ, Pérez González A, Guerra Vales JL, Melero Gonzalez R, Pego Reigosa JM. Síndrome del pulmón encogido en el síndrome de Sjögren primario tratado con éxito con rituximab. *Arch Bronconeumol.* 2015;51:475-476.