

typical of *Aspergillus* and growth of these hyphae on culture. However, histological confirmation is not always possible, so diagnosis must be based on a combination of clinical, radiological, microbiological, and immunological findings.^{2,3} Azoles are the primary treatment option in CPA.⁴ Our patient showed disease progression during itraconazole treatment, which may have been a consequence of the temporary interruption of treatment or resistance to that compound. Wild-type resistance to azoles has been reported in *Aspergillus* strains in azole-naïve patients.⁵ Disease progression may also have been caused by sub-therapeutic serum levels of itraconazole during treatment, despite the administration of a higher than recommended dose. Surgical treatment is controversial, since it is associated with significant post-operative complications and disease recurrence, even at distant sites, so should be reserved for selected patients.^{2,3} In our case, surgery did not appear to be the best therapeutic approach, since the patient had bronchiectasis in the contralateral lung, which may have been associated with fungal colonization.⁶ Nevertheless, this option could have been considered if medical intervention had failed. Although the patient showed no evidence of immunosuppression, still undefined immune deficiencies cannot be ruled out.⁷ Consequently, while medical treatment appears to have clear advantages in cases in which it is well tolerated, the long-term outcome is unknown.

References

- Guimaraes MD, Marchiori E, de Souza Portes Meirelles G, Hochegger B, Santana PR, Gross JL, et al. Fungal infection mimicking pulmonary malignancy: clinical and radiological characteristics. *Lung*. 2013;191:655–62.
- Godet C, Philippe B, Laurent F, Cadranel J. Chronic pulmonary aspergillosis: an update on diagnosis and treatment. *Respiration*. 2014;88:162–74.
- Kousha M, Tadi R, Soubani AO. Pulmonary aspergillosis: a clinical review. *Eur Respir Rev*. 2011;20:156–74.
- Limper AH, Knox KS, Sarosi GA, Ampel NM, Bennett JE, Catanzaro A, et al., American Thoracic Society Fungal Working Group. An official American Thoracic Society statement: treatment of fungal infections in adult pulmonary and critical care patients. *Am J Respir Crit Care Med*. 2011;183:96–128.
- Chowdhary A, Kathuria S, Xu J, Meis JF. Emergence of azole-resistant *aspergillus fumigatus* strains due to agricultural azole use creates an increasing threat to human health. *PLoS Pathog*. 2013;9:e1003633.
- King PT, Holdsworth SR, Freezer NJ, Villanueva E, Holmes PW. Microbiologic follow-up study in adult bronchiectasis. *Respir Med*. 2007;101:1633–8.
- Chai LY, Kullberg BJ, Vonk AG, Warris A, Cambi A, Latge JP, et al. Modulation of Toll-like receptor 2 (TLR2) and TLR4 responses by *Aspergillus fumigatus*. *Infect Immun*. 2009;77:2184–92.

Hans Dabó,* Anabela Marinho, Isabel Gomes

Department of Pulmonary Medicine, Centro Hospitalar de São João EPE Alameda Prof. Hernâni Monteiro, Oporto, Portugal

* Corresponding author.

E-mail address: hansdabo@yahoo.com.br (H. Dabó).

Psychogenic Cough: A Rare Cause of Chronic Cough^{*}



Tos psicógena: una rara causa de la tos crónica

To the Editor:

Psychogenic cough is a rare cause of chronic cough in adults. It is typically persistent, disrupts daily activities and causes long-term morbidity. In contrast with cough of organic etiology, there is no clinical or laboratory evidence of disease.^{1,2}

Efforts to make an early diagnosis will reduce morbidity, prevent fixation of symptoms and avoid unnecessary procedures and therapies.²

We report the case of a 45-year-old woman, Caucasian, non-smoker, no habitual medication and no known previous allergies.

The patient consulted her family doctor due to a 9-week history of coughing fits.

The cough started and persisted after an upper respiratory tract infection treated with antibiotics (amoxicillin/clavulanic acid) and antihistamine (hydroxyzine). It was described as violent, nonproductive, occurring every few minutes, disrupting speech, work and daily activities, but not sleep because it disappeared at night.

Physical examination, including ear, nose and throat evaluation was normal, and no noticeable motor tic was observed.

No organic etiology was detected on medical examinations, including chest and sinus X-rays, skin-prick test for allergies, spirometry with bronchial challenge, thyroid ultrasound and chest computed tomography.

Pharmacological therapy with antihistaminic/decongestant (pseudoephedrine+triprolidine), inhaled corticosteroid (budesonide) and bronchodilator (salbutamol) was ineffective. A trial of

acid suppression (omeprazole), prokinetic (metoclopramide) and dietary modification also failed.

During investigation, regular consultations were scheduled. In the course of these consultations, she reported depressive symptoms. She related them to work-related distress, which began 2 months before the coughing fits, when she was moved to a new position. We perceived that cough was always present except when she spoke about her work-related distress. This observation, in association with negative findings on diagnostic tests, lack of response to therapy and the clinical characteristics of the cough, raised the suspicion of a psychogenic etiology.

A plan of weekly cognitive psychotherapy, in addition to antidepressant therapy with sertraline, was initiated. After five weeks, the cough disappeared and depressive symptoms decreased. No relapses were reported in the following twelve months.

In adult patients with chronic cough, doctors should always work toward a clear diagnosis, considering common and rare illnesses.³

Little has been published on diagnostic approaches.^{1,4} However, when extensive evaluation and therapy fail to detect an organic cause, psychogenic cough should be considered.^{1,3,5} Upper respiratory infections, depressive disorders and work distress have been described as precipitating factors.^{3,5} In this case, a psychogenic origin was first suggested by cough absence during sleep and while speaking about work distress.^{1,4}

Non-pharmacological therapies have been reported to be more effective than pharmacological treatments.³ However, there is a lack of randomized, controlled studies comparing different strategies.²

This case highlights the role of an empathic and integrated approach by the family doctor. It made early diagnosis possible, and non-pharmacological and pharmacological treatments could be started immediately, thus avoiding specialist referral and iatrogenic complications.

In conclusion, psychogenic cough is a rare entity, diagnosed after extensive exclusion of organic causes, positive clinical findings and response to specific therapy.

^{*} Please cite this article as: Oliveira R, Martins V, Moreira C. Tos psicógena: una rara causa de la tos crónica. *Arch Bronconeumol*. 2015;51:604–605.

References

1. Irwin RS, Glomb WB, Chang AB. Habit cough, tic cough, and psychogenic cough in adult and pediatric populations: ACCP evidence-based clinical practice guidelines. *Chest*. 2006;129 1 Suppl:174S–9S.
2. Niggemann B. How to diagnose psychogenic and functional breathing disorders in children and adolescents. *Pediatr Allergy Immunol*. 2010;21: 895–9.
3. Haydour Q, Alahdab F, Farah M, Barrionuevo P, Vertigan AE, Newcombe PA, et al. Management and diagnosis of psychogenic cough, habit cough, and tic cough: a systematic review. *Chest*. 2014;146:355–72.
4. Ramanuja S, Kelkar P. Habit cough. *Ann Allergy Asthma Immunol*. 2009;102:91–5.
5. Gay M, Blager F, Bartsch K, Emery CF, Rosenstiel-Gross AK, Spears J. Psychogenic habit cough: review and case reports. *J Clin Psychiatry*. 1987;48: 483–6.

Rui Oliveira,* Vítor Martins, Carla Moreira

USF Infante D. Henrique, Viseu, Portugal

* Corresponding author.

E-mail address: rui.joveira@yahoo.com (R. Oliveira).

Pulmonary manifestation of lymphomatoid granulomatosis[☆]



Granulomatosis linfomatoide: afectación pulmonar

To the Editor,

We report the case of a 57-year-old woman, former smoker, with a history of non-pathological cervical and axillary lymphadenopathies, non-necrotizing granulomatous mastitis and acute dorsal myelopathy. She was admitted for bronchopneumonia, and underwent bronchoscopy with transbronchial biopsies, which were inconclusive, and bronchoalveolar lavage (BAL) showing 65% lymphocytes and a normal CD4/CD8 ratio. The patient was readmitted due to right pleural effusion, categorized as lymphocytic exudate with no malignant cellularity, hepatosplenomegaly, and signs of pulmonary hypertension. Low levels of IgG subclasses were reported and treatment was initiated with prednisone. The patient subsequently developed dyspnea, anorexia and asthenia. Chest computed tomography showed peribronchial pulmonary nodules with undefined borders, air bronchogram sign, and tendency to converge into large masses in the lower lobes. These masses were surrounded by ground glass opacities and mediastinal lymphadenopathies, indicative of lymphomatoid granulomatosis. Ground glass opacities and lymphadenopathies,

however, are not typical of lymphomatoid granulomatosis, and may have been associated with the patient's smoking habit (Fig. 1). Lung function tests showed moderate restriction, with 36% diffusion, and laboratory reports revealed leukopenia due to lymphopenia. A bone marrow biopsy and a second bronchoscopy were performed, from which BAL showed predominant lymphocytes and a normal CD4/CD8 ratio. No additional data could be obtained from biopsy of a paratracheal lymphadenopathy. Culture and cytology were negative. A lung biopsy was obtained, after which the patient showed clinical and radiological worsening.

The result of the bone marrow biopsy suggested a T-cell-rich large-B-cell lymphoma. Chemotherapy was initiated, without improvement. Pathology results from the lung biopsy were inconclusive. The patient continued to worsen rapidly and progressively until she died. Autopsy confirmed diffuse T-cell and histiocytic-rich large-B-cell lymphoma, associated with Epstein-Barr virus (EBV), with perivascular involvement and changes indicative of lymphomatoid granulomatosis.

Lymphomatoid granulomatosis was first described in 1972 by Liebow et al.¹ It occurs primarily in patients aged between 40 and 60 years, and mainly in men (2:1). It is an angiocentric and angiodestructive process, affecting extranodal regions that in 90% of cases involves the lung. This disease of the B-cells is thought to be associated with EBV infection, large-B-cell lymphoma, and immunosuppressive states.² Typical lung involvement is characterized by nodular lesions, with lymphocytic invasion of the blood vessels, that may converge and cavitate.^{2,3} It is diagnosed from histology findings, including polymorphic lymphoid infiltrates, transmural infiltration of the arteries and veins by lymphoid cells, and focal areas of necrosis.⁴

The treatment of lymphomatoid granulomatosis is controversial, and varies according to the histological grade. In the absence of symptoms and if the histological grade is low, the patient should be monitored. Other cases are treated with prednisone and cyclophosphamide, although standard therapy for non-Hodgkin lymphoma has also been attempted.

Satisfactory therapeutic outcomes have recently been achieved with interferon-alfa-2b and rituximab.⁵ The prognosis of lymphomatoid granulomatosis varies: spontaneous remission is observed in 20% of cases, while in others, mean survival is 2 years, with a 5-year mortality of 63%–90%.

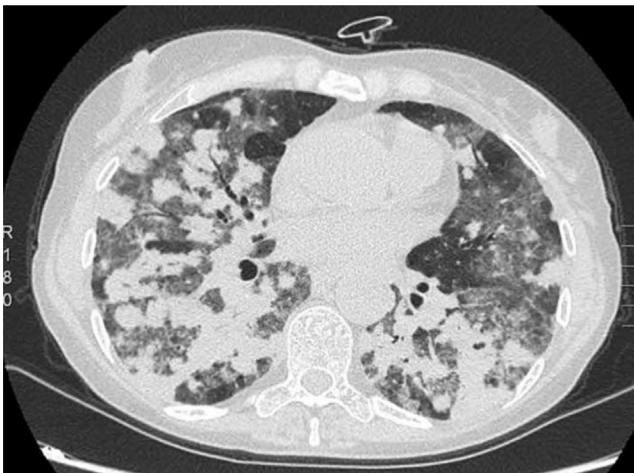


Fig. 1. Chest computed tomography, axial slice. Parenchymal window.

[☆] Please cite this article as: Martínez-Deltoro A, Lara SH, Calle SM. Granulomatosis linfomatoide: afectación pulmonar. *Arch Bronconeumol*. 2015;51:605–606.

References

1. Liebow AA, Carrington CB, Friedman PJ. Lymphomatoid granulomatosis. *Hum Pathol*. 1972;3:457–558.