



Clinical Image

Mycosis Fungoides Involving the Lungs Detected by ^{18}F -FDG PET/CT[☆]Micosis fungoide con localización pulmonar detectada con ^{18}F -FDG PET/TCGiorgio Treglia,^{a,*} Jessica Barizzi,^b Luca Giovanella^a^a Departamento de Medicina Nuclear y Centro PET/TC, Instituto Oncológico de Baja Suiza, Bellinzona, Switzerland^b Instituto de Patología del Cantón Ticino, Locarno, Switzerland

A 72-year-old male patient with a history of cutaneous mycosis fungoides, in clinical remission after treatment, underwent fluorine-18-fluorodeoxyglucose positron emission tomography/computed tomography (^{18}F -FDG PET/CT) for restaging due to the recent appearance of lung nodules on CT. PET/CT images showed multiple areas of increased radiopharmaceutical uptake corresponding to several bilateral pulmonary nodules (Fig. 1A–C).

Subsequently, the patient underwent pulmonary nodule biopsy. Histology showed the presence of interstitial infiltration of small to medium sized lymphoid elements with clear cytoplasm. On

immunohistochemistry, the tumor cells expressed CD3 and CD4 (Fig. 1D–F).

Based on these findings, the final diagnosis was pulmonary involvement of mycosis fungoides (MF) and the patient was referred for chemotherapy.

MF is a rare lymphoproliferative disease but it is the most common form of primary cutaneous T-cell lymphomas. It is characterized by a distinctive long-term course and malignant T-cell proliferation. MF is not easy to diagnose, mainly due to the atypical clinical presentation at an early stage. Visceral involvement of MF is very uncommon.^{1,2}

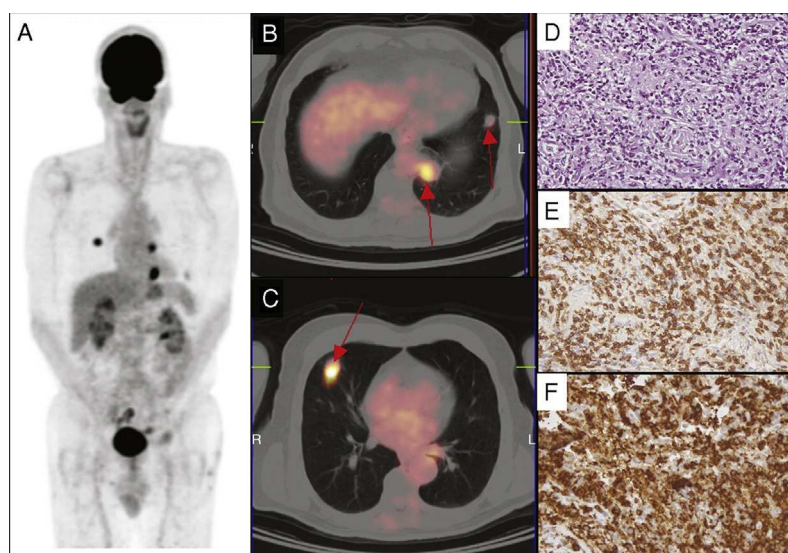


Fig. 1. Whole-body maximum intensity projection (MIP) ^{18}F -FDG PET image (A) and axial fused PET/CT images (B, C) showed several areas of increased ^{18}F -FDG uptake corresponding to bilateral pulmonary nodules (arrows). Histology of a pulmonary nodule showed the presence of interstitial infiltration of small-medium size lymphoid elements with clear cytoplasm (D). By immunohistochemistry the tumor cells expressed CD3 (E) and CD4 (F). The final diagnosis was lung involvement of mycosis fungoides.

[☆] Please cite this article as: Treglia G, Barizzi J, Giovanella L. Micosis fungoide con localización pulmonar detectada con ^{18}F -FDG PET/TC. Arch Bronconeumol. 2015;51:521–522.

* Corresponding author.

E-mail address: giorgio.treglia@eoc.ch (G. Treglia).

In our case, ¹⁸F-FDG PET/CT was very useful in the restaging of an unusual case of MF with lung involvement.

Conflict of Interest

The authors declare that they have no conflicts of interest.

References

1. Jawed SI, Myskowski PL, Horwitz S, Moskowitz A, Querfeld C. Primary cutaneous T-cell lymphoma (mycosis fungoides and Sézary syndrome): Part I. Diagnosis: Clinical and histopathologic features and new molecular and biologic markers. *J Am Acad Dermatol.* 2014;70, 205.e1–16.
2. Jawed SI, Myskowski PL, Horwitz S, Moskowitz A, Querfeld C. Primary cutaneous T-cell lymphoma (mycosis fungoides and Sézary syndrome): Part II. Prognosis, management, and future directions. *J Am Acad Dermatol.* 2014;70, 223.e1–17.