



Case Report

Management of Tracheobronchial Amyloidosis With Therapeutic Bronchoscopic Techniques[☆]

Javier Berraondo,* Laura Novella, Francisco Sanz, Rafael Lluch, Enrique de Casimiro, Tomás Lloret

Servicio de Neumología, Consorcio Hospital General Universitario de Valencia, Valencia, Spain

ARTICLE INFO

Article history:

Received 6 August 2012

Accepted 30 August 2012

Available online 29 March 2013

Keywords:

Amyloidosis

Tracheobronchial amyloidosis

Endoscopic techniques

ABSTRACT

Amyloidosis is a systemic disease caused by abnormal deposition of amyloid material that is detected with Congo red staining and is difficult to diagnose. Involvement of the tracheobronchial tree is rare and is a challenge for pulmonologists because of the wide differential diagnosis of this disease. We present two cases where tracheobronchial affection has been observed: in one of them as a primary disease, and in another as secondary affection. The use of bronchoscopic techniques is essential for the diagnosis of tracheobronchial involvement. In the absence of an effective drug therapy, local management of this disease with endoscopic techniques for bronchial re-permeabilization is able to provide clinical improvement and expand the treatment options and prognosis in this disease.

© 2012 Published by Elsevier España, S.L. on behalf of SEPAR.

Manejo de la amiloidosis traqueobronquial mediante técnicas broncoscópicas terapéuticas

RESUMEN

La amiloidosis es una enfermedad sistémica producida por el depósito anómalo de material amiloide; tiene la peculiaridad de detectarse con la tinción rojo Congo y es de difícil diagnóstico. La afectación del árbol traqueobronquial es muy poco frecuente y constituye un reto para el neumólogo debido al amplio diagnóstico diferencial de esta enfermedad. Se presentan 2 casos en los que se ha objetivado la afectación traqueobronquial: en uno de ellos como enfermedad primaria y en otro como afectación secundaria. El uso de técnicas broncoscópicas es primordial para el diagnóstico de la afectación traqueobronquial. En ausencia de un tratamiento médico eficaz, el manejo local de esta enfermedad con técnicas endoscópicas de re-permeabilización bronquial consigue una mejoría clínica y amplía las opciones terapéuticas y pronósticas en esta enfermedad.

© 2012 Publicado por Elsevier España, S.L. en nombre de SEPAR

Palabras clave:

Amiloidosis

Amiloidosis traqueobronquial

Técnicas endoscópicas

Introduction

Amyloidosis is a systemic disease of unknown origin which is characterized by extracellular deposits of proteins with a specific structural conformation that gives them a characteristic apple-green birefringence when stained with Congo red. They are deposited mainly in the heart, kidneys and liver. Diseases caused by abnormal amyloid deposits can be classified into primary or secondary, local or systemic, based on their distribution. Therefore, pulmonary involvement by amyloidosis can be both secondary

and primary, systemic or localized. It has an estimated incidence of between 5 and 10 cases per million persons/year. However, primary pulmonary involvement is much rarer,¹ and presents a challenge for the pulmonologist, as the use of bronchoscopy techniques is essential for diagnosis and to provide optimal treatment.

Cases

Case 1

A 46-year-old male who attended our clinic due to unproductive cough, moderate effort dyspnea of recent onset and temperature of 38 °C. His only history was that he smoked 45 packs/year, with no symptoms of chronic bronchitis. On physical examination, he had baseline oxygen saturation measured by pulse oximetry (SpO₂) of 93% on room air, and rhonchi in both hemithorax on pulmonary

[☆] Please cite this article as: Berraondo J, et al. Manejo de la amiloidosis traqueobronquial mediante técnicas broncoscópicas terapéuticas. Arch Bronconeumol. 2013;49:207–9.

* Corresponding author.

E-mail address: berraondo@hotmail.com (J. Berraondo).

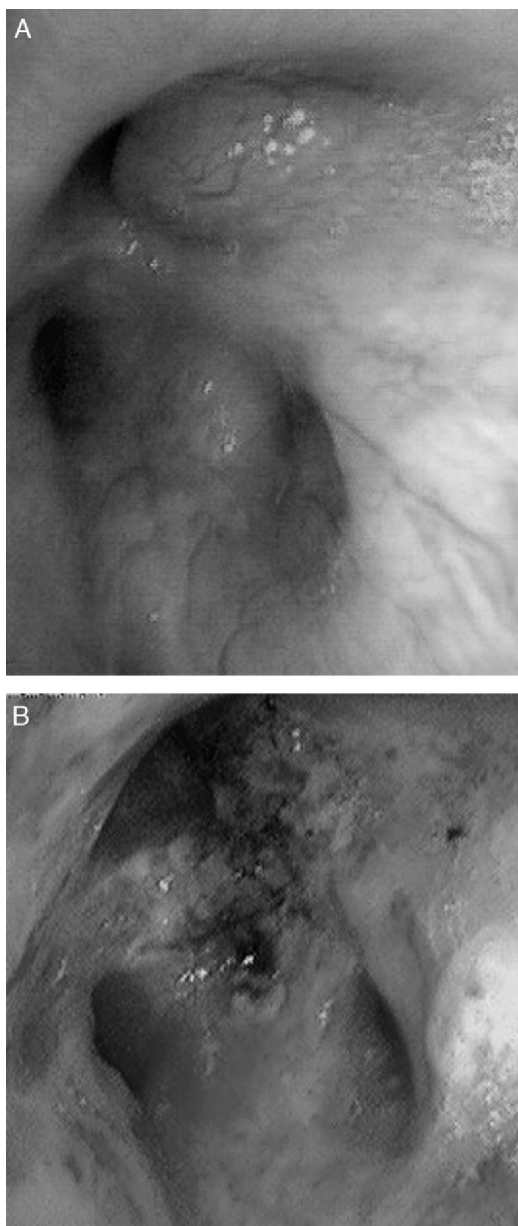


Fig. 1. Infiltration of the submucosa (A) and nodular lesions (B) in the bronchoscopy.

auscultation. Chest X-ray revealed alveolar consolidation in the right base and incipient consolidation in the left apex, and a nodular image on the apical segment of the left lower lobe. Blood tests showed leukocytosis of $17.6 \times 10^9/L$ with neutrophilia 86%, and C-reactive protein 19 mg/dL. Due to suspected pulmonary neoplasia, a chest computed tomography (CT) scan was performed, showing ground glass opacities in the left upper lobe and posterior basal segments of both lower lobes; it also showed multiple nodular (centroacinar) and tree-in-bud images, localized in the apical segment of the left lower lobe and in posterior basal segments with a tendency to cluster, with no nodal formations. Fibrobronchoscopy was performed, revealing an obstruction of >80% of the lumen of bronchi B1-B6D due to infiltration of the submucosa and nodular lesions (Fig. 1A), as well as irregular stenosis of the right basal bronchi. He also had carinal lymph node enlargement and tracheal stenosis in the upper third. The biopsy showed respiratory epithelium with deposits of amyloid material; immunohistochemical techniques with Congo red confirmed the finding as amyloidosis. An extension study was carried out, discarding systemic disease, so the

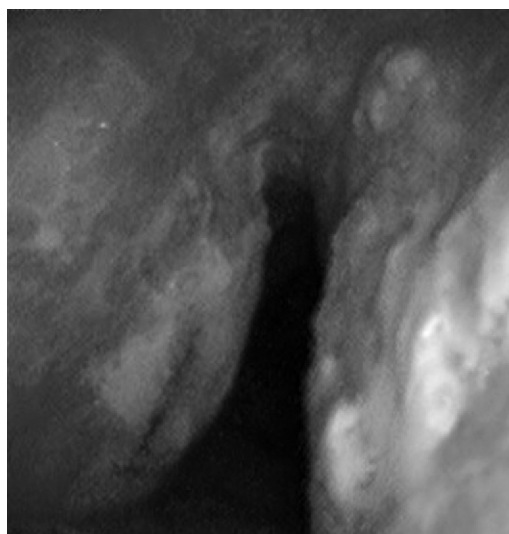


Fig. 2. The bronchoscopy shows nodules on the anterior and posterior sides of the trachea.

diagnosis of localized primary tracheobronchial amyloidosis was established.

Case 2

57-Year-old woman with repeated episodes of hemoptysis with no other symptoms. She had a history of hypertension for which she was on treatment with valsartan, chronic nasal obstruction and no toxic habits. The physical examination was normal, as were additional tests performed: laboratory tests and chest X-ray. A bronchoscopy was carried out, detecting multiple friable, bleeding nodules on the anterior and posterior side of the trachea, one of which was ulcerated (Fig. 2). The histopathology study demonstrated the presence of eosinophilic amorphous material that exhibited birefringence with polarized light, corresponding to amyloid material. An extension study of the disease was carried out, in which amyloid material was also detected in the subcutaneous fat and bone marrow biopsy. The patient was diagnosed with primary systemic amyloidosis with lung and bone marrow involvement.

Discussion

Amyloidosis is a rare disease of unknown etiology characterized by abnormal deposition of fibrillar proteins that typically exhibit apple-green birefringence under polarized light after Congo red staining. Involvement is variable, and there may be primary, secondary or senile disease. It may be systemic or well localized in an organ or tissue.² Pulmonary involvement by amyloid is exceptional, whether it forms part of a systemic disease or is localized. Five forms of primary pulmonary amyloidosis have been described: tracheobronchial, nodular (solitary or multiple), senile pulmonary, mediastinal-hilar and diffuse interstitial.³ Tracheobronchial amyloidosis is the most common presentation,³ and is characterized by amyloid deposits in the tracheobronchial tree only.

Amyloidosis affects mainly males (2:1) and in middle age (50–60 years). The clinical presentation, in the case of systemic disease, varies depending on the organs involved. In the case of pulmonary involvement, cough (74%), audible wheezing (70%), dyspnea (60%), hemoptysis (50%) and stridor (30%) are more common.⁴ More than half of cases may present as obstructive pneumonia, bronchiectases or atelectases,⁴ so its identification poses a major

challenge, even forming part of the differential diagnoses of various conditions such as asthma, recurrent pneumonias and neoplasia.

Several imaging techniques have been used to diagnose the disease, although the most useful is high resolution CT, which enables the form of pulmonary involvement to be distinguished.⁵ Much newer is the use of PET-CT, which shows intense uptake of 18-fluorodeoxyglucose (18-FDG) by the amyloid material. It is used in order to assess activity, and is useful in patient follow-up.⁶

Definitive diagnosis is made through histopathological study of the affected area, making it essential to perform bronchial endoscopic techniques when the airways are affected. Several bronchoscopic patterns have been suggested: nodular, pseudotumor, polypoidal and sub-mucosal,⁷ which together with endobronchial ultrasound (EBUS) (to discard mediastinal involvement) results in a full assessment of the disease by the bronchoscopist. Systemic involvement can be assessed by echocardiography and urinary protein measurements, which evaluate the cardiac and renal involvement, respectively, as these are the two organs most often affected.

No effective medical treatments have been described for pulmonary amyloidosis, although there are therapeutic bronchoscopy techniques which are effective for the management of this disease, with the primary aim of re-permeabilizing the airways. To that end, Nd:YAG laser has been used to treat bronchial obstructions due to amyloid deposits,⁸ while symptomatic improvement has also been achieved in the mid-term with the use of cryotherapy.⁹ The rigid bronchoscope enables both endoscopic resection of an amyloid obstruction and subsequent placement of a Dumon endobronchial stent to maintain the airway permeable for longer.¹⁰ External beam radiation therapy (EBRT) achieves significant clinical improvement,^{11–13} although it requires individualization of treatment, given the possible complications due to the radiation.¹¹

Colchicine treatment has classically been used when there is systemic involvement. Better survival has subsequently been demonstrated with dexamethasone as monotherapy,¹⁴ and especially with the combination of prednisone and melphalan.¹⁵ Autologous stem cell transplant is performed where possible.² When the involvement is localized in the tracheobronchial tree or lung parenchyma, treatment with systemic drugs is not indicated.²

With respect to follow-up of these patients, the highly experienced University of Boston working group suggests serial pulmonary function tests and CT imaging as the best way of assessing the status of the airways and disease progression.¹⁶

The prognosis is related to systemic involvement, with greater mortality in patients with cardiac involvement; its main cause of death is sudden death.¹⁷ In the case of localized pulmonary involvement, the prognosis improves; the main causes of death in these patients are respiratory failure and massive hemoptysis.

The patient in case 1 was treated on two occasions with Nd:YAG laser to re-permeate the airways (Fig. 1B), owing to the stenosis that he presented due to amyloid infiltration, achieving clinical and functional improvement. With respect to the patient in case 2, she received treatment with a combination of prednisone and melphalan, with a good response and partial resolution of the tracheal lesions, with no functional or symptomatic impairment.

Funding

None.

Conflict of Interest

The authors declare that there is no conflict of interest.

References

- Undurraga F, Jadue C, Cáceres R. Amiloidosis endobronquial. *Rev Chil Enf Respir.* 2005;21:193–9.
- Gertz MA. How to manage primary amyloidosis. *Leukemia.* 2012;26:191–8.
- Utz J, Swensen SJ, Gertz MA. Pulmonary amyloidosis. The Mayo Clinic experience from 1980 to 1993. *Ann Intern Med.* 1996;124:407–13.
- Corrin B, Castabel U. Other rare parenchymal lung disorders. In: Gibson J, Geddes DM, Costabel U, Sterk P, Corrin B, editors. *Respiratory medicine.* 3rd ed. London: Saunders; 2003. p. 1689–91.
- Gómez AT, Alonso RM, García MM, Fabbriatore AA, García-Tejedor JL. Thoracic amyloidosis: high-resolution computed tomographic findings in 3 cases. *J Comput Assist Tomogr.* 2008;32:926–8.
- Soussan M, Ouvrier MJ, Pop G, Galas JL, Neuman A, Weinmann P. Tracheobronchial FDG uptake in primary amyloidosis detected by PET/CT. *Clin Nucl Med.* 2011;36:723–4.
- Capizzi SA, Betancourt E, Prakash UB. Tracheobronchial amyloidosis. *Mayo Clin Proc.* 2000;75:1148–52.
- Madden BP, Lee M, Paruchuru P. Successful treatment of endobronchial amyloidosis using Nd:YAG laser therapy as an alternative to lobectomy. *Monaldi Arch Chest Dis.* 2001;56:27–9.
- Maitwand MO, Nath AR, Kamath BSK. Cryosurgery in the treatment of tracheobronchial amyloidosis. *J Bronchol.* 2001;8:95–7.
- Yang S, Chia SY, Chuah KL, Eng P. Tracheobronchial amyloidosis treated with rigid bronchoscopy and stenting. *Surg Endosc.* 2003;17:658–9.
- Neben-Wittich MA, Foote RL, Kalra S. External beam radiation therapy for tracheobronchial amyloidosis. *Chest.* 2007;132:262–7.
- Munroe AT, Walia R, Zlotecki RA, Jantz MA. A case report of successful treatment with external beam radiation therapy. *Chest.* 2004;125:784–9.
- Kurrus JA, Hayes JK, Hoidal JR, Menendez MM, Elstad MR. Radiation therapy for tracheobronchial amyloidosis. *Chest.* 1998;114:1189–92.
- Palladini G, Anesi E, Perfetti V, Obici L, Invernizzi R, Balduini C, et al. A modified high-dose dexamethasone regimen for primary systemic (AL) amyloidosis. *Br J Haematol.* 2001;113:1044–6.
- Palladini G, Russo P, Nuvolone M, Lavatelli F, Perfetti V, Obici L, et al. Treatment with oral melphalan plus dexamethasone produces long-term remissions in AL amyloidosis. *Blood.* 2007;110:787–8.
- O'Regan A, Fenlon HM, Beamis Jr JF, Steele MP, Skinner M, Berk JL. Tracheobronchial amyloidosis. The Boston University experience from 1984 to 1999. *Medicine.* 2000;79:69–79.
- Dispenzieri A, Merlini G, Comenzo RL. Amyloidosis 2008 BMT Tandem Meetings (February 13–17; San Diego). *Biol Blood Marrow Transplant.* 2008;14 Suppl. 1:6–11.