

specific, and the differential diagnosis should include pulmonary tuberculosis, sarcoidosis, histiocytosis X, tumorlets and pulmonary metastases. The definitive diagnosis is established by lung biopsy. In small samples it is particularly difficult to differentiate it from papillary adenoma. The natural history is not clear, but it is unlikely for it to degenerate to malignancy, and the clinical evolution is good although there have been reported episodes of death due to respiratory failure.^{3,5,6}

References

1. Umeoka S, Koyama T, Miki Y, Akai M, Tsutsui K, Togashi K. Pictorial review of tuberous sclerosis in various organs. *Radiographics*. 2008;28:e32.
2. Costello LC, Hartman TE, Ryu JH. High frequency of pulmonary lymphangiomyomatosis in women with tuberous sclerosis complex. *Mayo Clin Proc*. 2000;75:591–4.
3. Franz DN, Brody A, Meyer C, Leonard J, Chuck G, Dabora S, et al. Mutational and radiographic analysis of pulmonary disease consistent with lymphangiomyomatosis and micronodular pneumocyte hyperplasia in women with tuberous sclerosis. *Am J Respir Crit Care Med*. 2001;164:661–8.

4. Popper HH, Juettner-Smolle FM, Pongratz MG. Micronodular hyperplasia of type II pneumocytes: a new lung lesion associated with tuberous sclerosis. *Histopathology*. 1991;18:347–54.
5. Kobashi Y, Sugiu T, Mouri K, Irei T, Nakata M, Oka M. Clinicopathological analysis of multifocal micronodular pneumocyte hyperplasia associated with tuberous sclerosis in Japan. *Respirology*. 2008;13:1076–81.
6. Ristagno R, Biddinger P, Pina E, Mever C. Multifocal micronodular pneumocyte hyperplasia in tuberous sclerosis. *AJR Am J Roentgenol*. 2005;184: S37–9.

Luis Miravet Sorribes,^{a,*} Nuria Mancheño Franch,^b
Laura Batalla Bautista^a

^a *Sección de Neumología, Hospital de la Plana, Vila-real, Castellón, Spain*

^b *Servicio de Anatomía Patológica, Hospital La Fe, Valencia, Spain*

* Corresponding author.

E-mail address: miravet.lui@gva.es (L. Miravet Sorribes).

Diagnosis of Pulmonary Adenocarcinoma Due to Hip Bone Metastasis[☆]

Diagnóstico de adenocarcinoma pulmonar por metástasis ósea en cadera

Dear Editor,

The fact that the first symptom of a primary tumor is bone metastasis is not uncommon and should be part of the differential diagnosis in patients with history of risk. Lung cancer has a predilection for bones, and metastases generally settle in the proximal femur.

We present the case report of a 56-year-old woman, with no personal history of interest other than being a pack-a-day smoker, who came to our consultation due to pain in the trochanteric region that had been evolving over the past 2 months. It was treated as trochanteric bursitis, with poor response to non-steroid anti-inflammatory medication. Given the lack of improvement and poor-quality radiographies, magnetic resonance imaging tests (MRI) were ordered, which revealed a central, expansive image with aggressive characteristics located at the major trochanter of the right hip (Fig. 1). With the suspicion of primary or metastatic malignant tumor, an extension study was done with thoraco-abdominal computed tomography, which revealed a left suprahilar lung mass measuring 20 × 23 mm that infiltrated the aortopulmonary window, with homolateral mediastinal lymphadenopathies and an osteolytic image in the right intertrochanteric femoral neck, measuring 45 mm with soft tissue mass. Bronchoscopy demonstrated inflammatory mucosa in the left upper lobe. Bronchial aspiration with no neoplastic cells. PET/CT: left perihilar mass 20 × 25 mm (SUV 16), lytic lesion with soft tissue mass in the trochanteric area of the right femur (SUV 8.7). Analysis: hemogram, 3750 leukocytes; hemoglobin, 8.5 g/dl; platelets, 164,000. Biochemistry: albumin, 3 g/dl; alkaline phosphatase, 113 U; lactate dehydrogenase, 130 U; the remainder was normal. Ions and coagulation, normal. Carcinoembryonic antigen, 127 ng/ml; Ca15.3, 37 U/ml; Ca 125 and Ca 19.9, normal. We carried out percutaneous biopsy of the trochanteric region, guided by

radioscopy, which was reported to be compatible with metastasis of lung adenocarcinoma.

With said diagnosis, and given the immobility of the patient, we opted for complete resection of the trochanteric metastasis and substitution of the defect by implanting a megaprosthesis. Post-op was adequate, and the patient was up and walking on the 5th day with a walker, and with the use of a cane one month later.

Evolution

Systemic chemotherapy was begun with cisplatin and vinorelbine, competing 6 cycles with no incidences and an acceptable quality of life for the patient. After 7 months, the patient was hospitalized due to a process of deterioration and disorientation, and cerebral MRI diagnosed cerebral metastases. Holocranial radiotherapy was begun, but one month later the patient started to have generalized bone pain, dysphagia and progressive dyspnea secondary to the progression of the disease in the lungs and mediastinum. The patient died 13 months after the diagnosis.

Discussion

It is important to include tumor pathology within the differential diagnoses of muscular-skeletal pain, especially in patients who have risk factors like smoking.¹ Clinically, it is difficult to diagnose

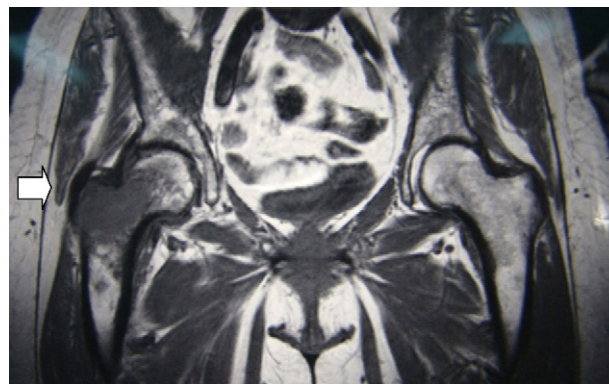


Fig. 1. Magnetic resonance imaging in T1 showing a central and expansive image with aggressive characteristics located at the major trochanter and neck of the right hip (arrow).

[☆] Please cite this article as: Puertas García-Sandoval JP, et al. Diagnóstico de adenocarcinoma pulmonar por metástasis ósea en cadera. *Arch Bronconeumol*. 2012;49:37–8.

primary bone tumor or metastasis, but it should be suspected when the pain is continuous, even at rest, and there is no improvement with analgesic therapy. When given pain with these characteristics, simple radiography should be taken of the affected region, as it is a test that provides much information. At middle age, and mainly over the age of 60, the differential diagnosis initially includes a metastatic origin, and then a primary tumor such as giant-cell tumor or osteosarcoma. Among the lung tumor types, non-small-cell lung cancer most frequently presents bone metastasis, most of which (66%) are detected at the time of the initial diagnosis.² When these lesions are metastatic, their management varies depending on possibilities for survival. Even though the prognosis is very poor, surgery of the area, especially if the hip is involved, provides the patient with much better mobility and a high quality of life. The best surgical option is complete resection of the metastasis, especially when it is a single metastasis, and substitution of the bone defect by implanting a megaprosthesis. The components are generally cemented for fast bone incorporation and to be able to rapidly make the patient mobile.^{3,4}

Funding

The authors declare having received no source of funding.

Conflict of Interests

The authors declare having no conflict of interests regarding this paper.

References

1. Clarke HD, Damron TA, Sim FH. Head and neck replacement endoprotheses for pathologic proximal femoral lesion. *Clin Orthop*. 1998;353:210-7.
2. Al Husaini H, Wheatley P, Clemons M, Frances A. Prevention and management of bone metastases in lung cancer: a review. *J Thorac Oncol*. 2009;4:251-9.
3. Mankin HJ, Francis J. Total femur replacement procedures in tumor treatment. *Clin Orthop*. 2005;438:60-4.
4. Shinichiro N, Katsuyuki K. More than 10 years of follow-up of two patients after total femur replacement for malignant bone tumor. *Int Orthop*. 2000;24:176-8.

Jose Pablo Puertas García-Sandoval, Antonio Valcárcel Díaz,*
Jose Andrés Calatayud Mora

Unidad de Tumores, Servicio de Cirugía Ortopédica y Traumatología, Hospital Universitario Virgen de la Arrixaca, El Palmar, Murcia, Spain

* Corresponding author.

E-mail address: AVD1981@HOTMAIL.COM (A. Valcárcel Díaz).

Thyroid Cyst Diagnosed by Endobronchial Ultrasound-guided Transbronchial Needle Aspiration in a Patient With Lung Cancer[☆]

Diagnóstico de quiste tiroideo mediante ultrasonografía endobronquial sectorial con punción-aspiración en un paciente con cáncer de pulmón

Dear Editor,

We present the case of a 69-year-old patient, ex-smoker, diabetic and dyslipidemic, who was referred from another center with the diagnosis of pulmonary adenocarcinoma obtained with bronchoscopy that demonstrated a tumor in the orifice of the anterior segmental bronchus of the right upper lobe. Positron-emission tomography CT (PET-CT) confirmed a paramediastinal mass with increased uptake (SUVmax. 15 g/ml) in the RUL compatible with a malignant tumor, right lower paratracheal lymphadenopathy with a fatty center with no FDG uptake and a right upper paratracheal lesion measuring 8 mm, which was discretely hypermetabolic (Fig. 1A and B) and interpreted as a lymphadenopathy. Given these findings, the mass was staged as T3NxM0. As the patient was a candidate for radical surgical treatment, it was considered necessary to obtain samples in order to rule out N2 affection.

Sectorial endobronchial ultrasound (Olympus BF-UC 180F, Olympus, Tokyo, Japan) revealed a right lower paratracheal lymphadenopathy measuring 13 mm × 10 mm with a fatty center (Fig. 1C) that was aspirated and resulted negative for malignant cells; in addition, there was a hypoechoic nodule in the upper right paratracheal region (practically subglottic), measuring 8 mm × 7 mm (Fig. 1D), which Doppler ruled out as a possible blood

vessel. The ultrasound characteristics of said lesion were suggestive of a cyst, and needle aspiration obtained a liquid that the pathological analysis demonstrated to have follicular cells in plaques and groups, abundant macrophages and hemosiderophages on a background of colloid material, all of which were compatible with a thyroid cyst.

The existence of false positives from PET-CT in the mediastinal staging of lung cancer requires cytohistologic confirmation based on minimally invasive techniques such as ultrasound bronchoscopy. In this direction, recently published studies report a negative predictive value of PET-CT of 95%.¹

Most thyroid nodules detected in patients with pulmonary neoplasm are usually benign lesions. Nonetheless, thyroid metastases in lung cancer have been described by some authors.² It is for this reason that cytological confirmation is essential when given a patient with malignant lung disease.

Thyroid cysts are nodules with liquid content, located in the thyroid and differentiated from the rest of the parenchyma. Some papers have been published about the clinical implications and recommended management in neoplastic patients in whom uptake is detected by PET in the thyroid. The prevalence of this finding ranges between 1.2% and 4.3% of cases. The risk for malignancy of these lesions can reach 33%, corresponding with thyroid carcinomas (medullar or papillary), and in no case was it a metastasis of a primary neoplasm. In addition, the value of the SUVmax is not useful in order to differentiate between the benign or malignant nature of these lesions; therefore, cytohistologic confirmation is highly recommended.^{3,4}

After reviewing the literature to date, we have only identified one single case published in a patient with small-cell lung cancer.⁵

We would like to emphasize the importance of confirming positive PET-CT findings in the mediastinum in patients with lung cancer, as well as the usefulness of sectorial endobronchial ultrasonography for the identification and complication-free needle-aspiration of thyroid cysts.

[☆] Please cite this article as: Sánchez-Font A, et al. Diagnóstico de quiste tiroideo mediante ultrasonografía endobronquial sectorial con punción-aspiración en un paciente con cáncer de pulmón. *Arch Bronconeumol*. 2012;49:38-9.