



Original Article

Treatment of Airway Complications Following Lung Transplantation

Sebastián Fernández-Bussy, ^{a,b,*} Adnan Majid, ^c Iván Caviedes, ^b Olufemi Akindipe, ^a Maher Baz, ^a Michael Jantz ^a

^aDivisión de Neumología Intervencional, Shands at University of Florida, Gainesville, USA

^bDivisión de Neumología Intervencional, Clínica Alemana de Santiago, Chile

^cDivisión de Neumología Intervencional, Beth Israel Deaconess Medical Center, Boston, USA

ARTICLE INFO

Article history:

Received October 12, 2010

Accepted October 24, 2010

Keywords:

Bronchoscopy

Stent

Stenosis

Bronchomalacia

Lung transplantation

Airway complications

Dehiscence

Balloon dilatation

Argon plasma coagulation

ABSTRACT

Objective: To describe our experience in airway complications following lung transplantation and to suggest a management strategy using different interventional bronchoscopic techniques.

Method: Retrospective analysis of all airway complications following lung transplantation from January 1999 to July 2007.

Results: During this period, 223 patients underwent lung transplantation, with a total of 345 airway anastomoses. In 70 (20.23%), there were complications requiring endoscopic intervention. A total of 631 procedures were carried out in 52 patients. Thirty-three patients presented a combination of bronchial stenosis and bronchomalacia, 18 patients had bronchial stenosis alone and 1 patient presented dehiscence of the anastomosis. In most cases, pneumatic balloon dilatation was effective, although temporarily, and ultimately 47 patients required endobronchial stent placement. The most common complication associated with the use of stents was granulation tissue formation, seen in 57.3% of patients. After stent placement, forced expiratory volume in one second (FEV₁) improved significantly.

Conclusion: Airway complications after lung transplantation are frequent. Balloon dilatation was effective in only a few patients with bronchial stenosis, requiring stent placement in most. Airway permeabilization after endobronchial stent placement improved FEV₁ in these patients. Based on our experience, we propose a management strategy for airway complications after lung transplantation.

© 2010 SEPAR. Published by Elsevier España, S.L. All rights reserved.

Tratamiento de complicaciones en la vía aérea postrasplante pulmonar

RESUMEN

Propósito: Describir nuestra experiencia en las complicaciones de la vía aérea después del trasplante pulmonar y sugerir un esquema de tratamiento, utilizando diferentes técnicas de broncoscopia intervencionista.

Método: Análisis retrospectivo de todas las complicaciones en la vía aérea postrasplante pulmonar desde enero de 1999 hasta julio de 2007.

Resultados: Durante este periodo, en 223 pacientes se realizó trasplante pulmonar, un total de 345 anastomosis en la vía aérea. En 70 de ellas (20,23%) hubo complicaciones, requiriendo de intervención endoscópica. Se realizó un total de 631 procedimientos en 52 pacientes. Treinta y tres pacientes presentaron la combinación de estenosis bronquial con broncomalacia, 18 pacientes presentaron solo estenosis bronquial y 1 paciente presentó dehiscencia de la anastomosis. En la mayoría de los casos, la dilatación neumática por balón tuvo efectividad transitoria, 47 pacientes requirieron de la instalación de un stent endobronquial. La complicación más común asociada con la utilización de stents fue el tejido de granulación en el 57,3% de los pacientes. Luego de la colocación de stents, el volumen espiratorio forzado en el primer segundo (FEV₁) mejoró significativamente.

Palabras clave:

Broncoscopia

Stent

Estenosis

Broncomalacia

Trasplante de pulmón

Complicaciones de la vía aérea

Dehiscencia

Dilatación neumática

Coagulación con Argón plasma

* Corresponding author.

E-mail address: bussysf@medicine.ufl.edu (S. Fernández-Bussy).

Conclusiones: Las complicaciones de la vía aérea después del trasplante pulmonar son frecuentes. En pocos pacientes con estenosis de la vía aérea hubo resolución definitiva con dilatación bronquial neumática, requiriendo la mayoría de la colocación de stents endobronquiales. La permeabilización de la vía aérea por stents endobronquiales demostró mejorar el FEV₁ en estos pacientes. Sobre nuestra experiencia, proponemos un esquema de manejo de las complicaciones de la vía aérea postrasplante pulmonar.

© 2010 SEPAR. Publicado por Elsevier España, S.L. Todos los derechos reservados.

Introduction

Airway complications, especially during the process of anastomotic healing, are still an important source of morbidity and mortality after lung transplantation. The incidence of complications in the airway varies between 16 and 33%,¹ depending on the series. In this context, most centers have a variable incidence, ranging from 7 to 18%, with a related mortality of 2 to 4%.²⁻¹³ These differences in percentage can be explained by the lack of a classification system that is conventionally accepted by all centers.¹

Within the solid organ transplantations, lung transplantations have special characteristics that make them unique while conferring them greater susceptibility to anastomotic complications. In the immediate post-transplantation period, the anastomoses are vulnerable to ischemia as the circulation of the bronchial arteries are usually not restored; thus, perfusion depends on the retrograde flow coming from the pulmonary artery until collateral flow is developed, which is constituted 2 to 4 weeks after transplantation.¹⁴ Moreover, the surgical technique used^{6,7} and the colonization of the area of the anastomosis by bacteria are also involved in the genesis of airway complications.⁵⁻¹¹

The series of 223 patients that we present, with a total of 345 anastomoses, provides information that can be useful for treating airway complications and for defining the best therapeutic strategy. Our intention has been to describe the most frequent airway complications after lung transplant, and to suggest treatment guidelines for these complications using different bronchoscopic intervention techniques.

Patients and Methods

Ours is a retrospective study of lung transplant patients at a reference university hospital (Shands Hospital at the University of Florida), from January 1999 until July 2007. A total of 223 patients (128 men and 95 women) underwent lung transplantation, 30 of whom required re-transplantation (table 1). The total number of anastomoses was 345. Patients evolution was followed over the course of 14 months (until October, 2008) in order to evaluate the airway complications and the need for bronchoscopic procedures. The study was authorized by the research committee of the institution.

One hundred twenty-seven patients needed single lung transplant while 92 patients required bilateral lung transplant, 4 patients heart-lung transplant and 30 patients required retransplant (table 2).

Airway complications were categorized in the following manner: a) bronchial stenosis, defined when the granulation or scar tissue produced a decrease in the bronchial lumen of more than 50%; b) bronchomalacia, defined when bronchoscopy demonstrated a dynamic collapse greater than 50% of the bronchial lumen on expiration; c) bronchial stenosis associated with bronchomalacia, defined when the presence of both entities was confirmed; and d) anastomotic dehiscence, defined when loss in the continuity of the suture line was observed.

Airway complications were diagnosed by video-assisted bronchoscopy performed immediately after the surgery, and between days 2 and 7 of the post-operative period. Later bronchoscopic follow-up studies and transbronchial control biopsies were carried

Table 1

General characteristics of the patients with and without airway complications

Characteristics	Number of patients
Without complications	171
Males/females	94/77
Age	55 ± 13
Type of transplant	
Bilateral	64
Single	103
Heart/lung (Retransplant)	4 (17)
With complications	52
Males/females	34/18
Age	52 ± 11
Type of transplant	
Bilateral	28
Single	24
Heart/lung (Retransplant)	- (13)

out 1, 3, 6 and 12 months after transplantation. When the patients presented dyspnea, spirometric deterioration or new opacities on chest radiography, video-assisted bronchoscopy was also performed.

The bronchoscopic techniques used were: 1) resection with electrocauterization (Gold Probe Catheter, Boston Scientific Corporation, Natick, MA); 2) coagulation with argon plasma (ERBE USA Inc, Atlanta, GA); 3) balloon dilatation (CRE Balloon Dilator Boston Scientific Corporation); and 4) stent placement: Ultraflex (Boston Scientific Corporation, Natick, MA), hybrid Aero (Merit Endotek) and Palmaz (Palmaz stent).

The total number of procedures carried out was 631. Information was registered and analyzed in the following manner: a) type of airway complication (bronchial stenosis, bronchomalacia, combination of stenosis and malacia, dehiscence of the anastomosis); b) type of therapeutic procedure; c) period of time between the lung transplantation and the different endoscopic procedures completed; d) complications of the procedure (severe bleeding, respiratory insufficiency); and e) complications related with the stents (formation of granulation tissue, migration, stent fracture and formation of mucus plugs).

In addition, spirometry was carried out before and after stent placement in those patients whose clinical condition was adequate. Spirometry was done the same day as the stent implantation and was redone two weeks later. The changes in expiratory volume in one second (FEV₁) and in forced vital capacity (FVC) were compared by paired t-test for differences. P < 0.05 was considered significant.

Results

During the period analyzed, 223 patients underwent lung transplantation, while 30 were later retransplanted; 52 patients required endoscopic treatment (23.3%). Out of the 345 anastomoses, 70 (20.2%) required endoscopic treatment. Thirty-three patients (63.5%) presented a combination of bronchial stenosis with bronchomalacia, 18 (34.6%) had bronchial stenosis and 1 patient (1.9%) presented dehiscence of the anastomosis.

Table 2
Indications for lung transplantation, with and without airway complications

Indication	Without complications (N/%)	With complications (N/%)
Idiopathic lung fibrosis	68/39.8	15/28.9
Chronic obstructive pulmonary disease	48/28.1	14/26.9
Cystic fibrosis	19/11.1	7/13.5
Retransplant	17/9.9	13/25
Alpha 1 antitrypsin deficiency	12/7.0	2/3.9
Interstitial lung disease (non-idiopathic lung fibrosis)	10/5.9	7/13.5
Congenital heart disease	6/3.5	-
Bronchiectasis (no cystic fibrosis)	3/1.8	4/7.7
Pulmonary hypertension	3/1.8	7/13.5
Lymphangiomyomatosis	1/0.6	3/5.8
Pulmonary veno-occlusive disease	1/0.6	-

Table 3
Therapeutic procedures of interventional bronchoscopy

Type of procedure	N of patients (N/%)
Electrocauterization/APC	4/7.7
Balloon dilatation and electrocauterization/APC	1/1.9
Stent placement, single procedure	6/11.5
Balloon dilatation and stent	3/5.8
Electrocauterization/APC and stent	5/9.6
Balloon dilatation, electrocauterization/APC and stent	33/63.5

APC: argon plasma coagulation.

Table 4
Complications related to stent placement

Complication	Type of stent ^a	
	Ultraflex (N/%)	Aero (N/%)
Granulation tissue with obstruction > 50%	56/62.9	17/44.7
Mucus plugs	5/5.6	3/7.9
Stent migration	3/3.4	8/21.1
Stent fracture	5/5.6	2/5.3

^aThe register of the Palmaz stents was not available.

A total of 47 patients (90.4%) required stent placement at some point of their follow-up, with a total of 135 stents (89 Ultraflex, 38 Aero and 8 Palmaz). Out of these patients, 13 were initially treated with bronchial dilatation using pneumatic balloons, thermal treatment with electrocauterization or coagulation with argon plasma. The mean number of endoscopic procedures before stent placement was 3 procedures.

The Palmaz stents were implanted from 1999-2000, and the register of the complications involving these stents was not available to us. The total number of procedures done is shown in table 3. Only one patient presented partial dehiscence of the anastomosis and was successfully treated with the implantation of a stent. We registered no cases of severe bleeding, respiratory insufficiency or death.

The most common complication was the formation of granulation tissue (57.3%). Other complications were: formation of mucus plugs (6.3%), stent migration (8.6%) and stent fracture (5.5%) (table 4). In the group of retransplanted patients, the incidence of airway complications was higher (table 2).

Table 5
Spirometry before and after the placement of the first stent in 27 patients

Parameter	Prior to stent	After stent	p value
Forced vital capacity (L)	2.58 ± 0.84	2.68 ± 0.80	0.80
Forced expiratory volume in one second (L)	1.44 ± 0.52	1.81 ± 0.60	< 0.005

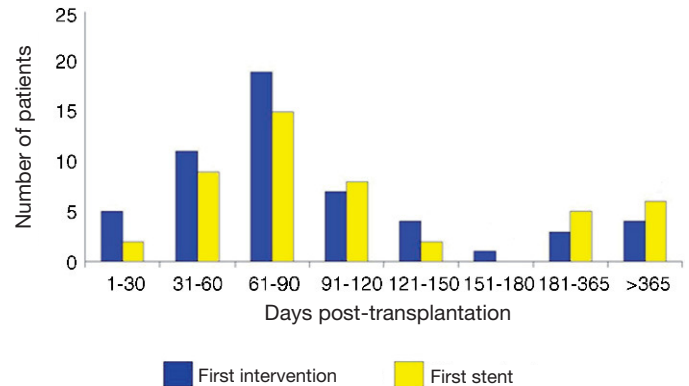


Figure 1. Period of time elapsed from the lung transplantation until the first bronchoscopic procedure and the placement of the first stent.

The average time elapsed between the transplantation and the first intervention was 132 days (range 13-911). The mean time elapsed between the transplantation and the placement of the first stent was 176 days (range 13-870) (fig. 1).

If we analyze the group of retransplanted patients, we see that there is a greater incidence of airway complications: 13/52 (25%) versus 17/171 (9.9%), which represents the group of retransplanted patients without airway complications. In 27 out of the 47 patients requiring stent placement, spirometry was able to be performed the day of the implantation and 2 week later. Improvement in FVC was demonstrated in 11 of the 27 patients, and improvement in FEV₁ in 17 of the 27 patients (table 5).

Discussion

Lung transplants are unique among the other solid organ transplants because the arterial circulation is not restored during surgery. For this reason, complications of the anastomosis have been attributed to the ischemia of the bronchus of the donor lung.¹⁵ Other factors, such as rejection,¹⁶ immunosuppressant therapy,¹⁷ infections¹⁸ or inadequate organ preservation,¹⁵ have mainly been associated with the alterations in the healing of the suture line. Other independent factors that have been identified as being associated

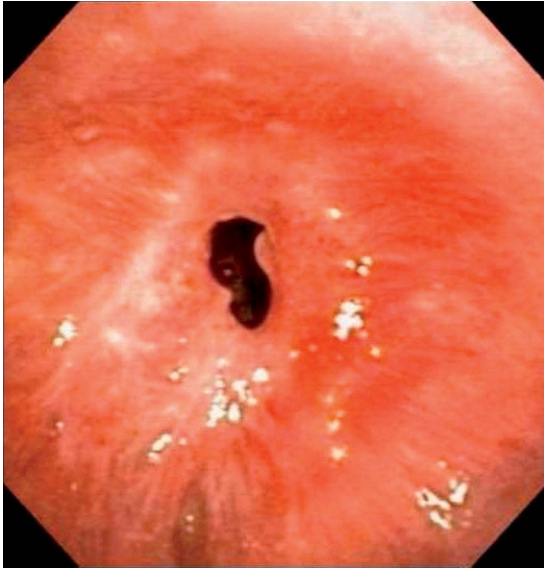


Figure 2. Stenosis of the anastomosis.

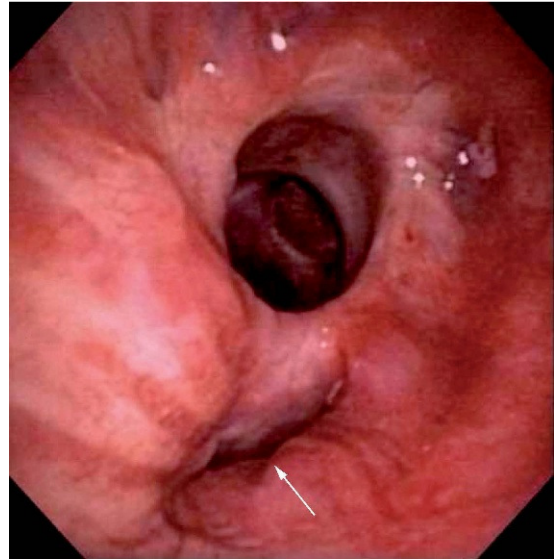


Figure 4. Partial anastomotic dehiscence.

with airway complications are severe reperfusion edema and early rejection episodes.¹⁹

In reviewing the literature, we have detected that our series constitutes one of the largest that has been reported. Two-thirds presented the combination of bronchial stenosis (fig. 2) and bronchomalacia. Pneumatic balloon dilatation was a transitory solution, requiring the placement of stents (fig. 3) in most patients (90.4%). Erasmus et al.²⁰ have also reported the need for stent implantation in the majority of their patients. In the report by Moreno et al.,²¹ they describe that balloon dilatation was often associated with the implantation of a stent. In contrast, De Gracia et al.²² affirm that balloon dilatation was effective and sufficient in 50% of their patients, but the number treated was merely 10.

In our sample, the placement of stents in the airway was associated with the formation of granulation tissue, mucus plugs, stent fracture and migration. The formation of granulation tissue was more common in non-removable metallic stents. Migration and mucus plugs were more frequent in removable hybrid stents.

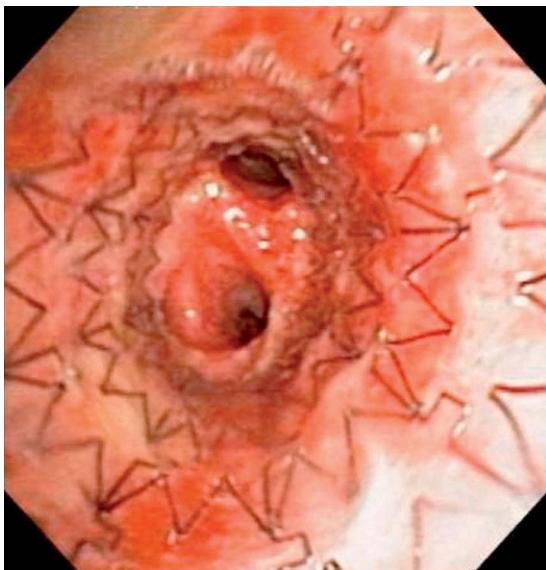

Figure 3. Endobronchial stent.

Granulation tissue represented a significant problem, as 57.3% of the patients presented granulation with an obstruction of more than 50% of the bronchial lumen. In analyzing the group of retransplanted patients in particular, there is a clear tendency towards a greater incidence of airway complications. We consider that the high incidence of granulation tissue may be related with the placement of stents in early stages and near the transplant, where the bronchial mucus does not present defined fibrotic tissue. On the other hand, stent placement showed a tendency towards improving FVC and was demonstrated to improve FEV₁ in a statistically significant range.

Anastomotic dehiscence is more frequent in the early postoperative period, presenting high morbidity (fig. 4). Its presentation may include respiratory insufficiency, bronchopleural fistulas, pneumothorax and hemodynamic collapse. Thoracic tomography can be used as the initial diagnostic exam; however, the findings should be confirmed by bronchoscopy, which is also a therapeutic instrument. Different surgical techniques have been used to prevent dehiscence, such as shortening the donor bronchus, reinforcing the anastomosis with a pedicle of vascularized tissue (omentum or intercostal muscle), bronchial intussusception and reanastomosis of the bronchial arteries. Despite these attempts, dehiscence and other complications of the airway are still common.

Based on our experience, we suggest the following strategy (fig. 5) for treating airway complications after lung transplantation:

1. For significant bronchial stenosis and for mixed lesions with associated bronchomalacia and predominant stenotic component, we propose attempting balloon dilatation as the primary intervention. This measure can improve the symptoms in the short-term, but stenotic lesions frequently reoccur, requiring periodic dilatations. We believe that stents should be used in recurring lesions that have not responded to 3-4 balloon dilatations, and particularly when the stenoses are fibrotic. For this reason, we recommend avoiding the placement of stents in the first few weeks post-transplant. We also suggest the placement of removable stents (silicone or hybrids),²³ keeping in mind that an ideal stent does not exist as they all present varying degrees of complications.
2. When granulation tissue forms, we recommend thermal therapy with electrocauterization, coagulation with argon plasma or cryotherapy.

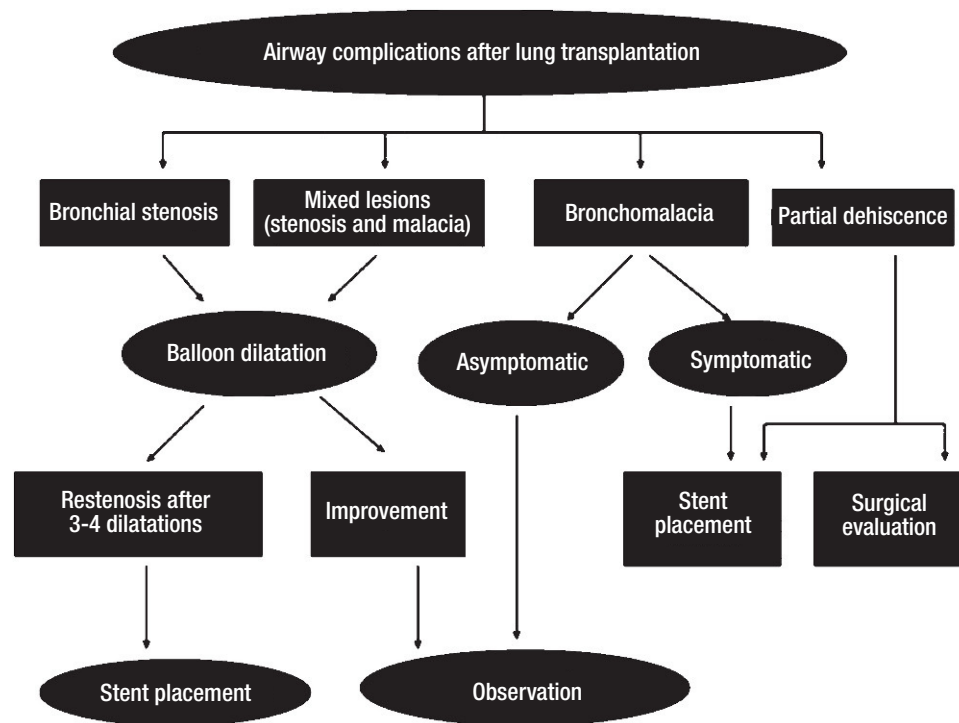


Figure 5. Management flowchart.

- In cases of bronchomalacia, in asymptomatic patients we suggest a conservative, wait-and-see approach, with periodic follow-up of symptoms and spirometry every 3 months. In the cases of moderate-to-severe bronchomalacia, and if the patient presents dyspnea or recurring infections, stent placement should be considered.
- In cases of partial dehiscence, resolution with stents can be attempted with a periodic weekly controls for one month; nevertheless, in such cases we always recommend a group evaluation with the surgical team.

Airway complications after lung transplantation are common. A limited number of cases of airway stenosis can be resolved with pneumatic balloon dilatation alone. The majority of patients require the placement of stents to maintain airway permeability. Stents present frequent complications in the mid and long term, the most common being the formation of granulation tissue.²⁴

Our current approach is conservative, using stents only in cases of fibrotic bronchial stenosis recurring after 3-4 balloon dilatations, with later removal of the stents after 3 to 6 months and airway re-evaluation. In cases of symptomatic bronchomalacia, we also consider the implantation of stents. In general, we use removable stents, these being silicone²⁵ as well as hybrid.

A multi-center study design is necessary to evaluate the long-term success of interventional pulmonology procedures in the treatment of airway complications after lung transplantation.

Conflict of Interest

The authors declare having no conflict of interest.

Acknowledgments

We would like to thank Dr. Liliana Fernández from the Fundación Valle de Lili for her valuable contribution to this manuscript.

References

- Santacruz JF, Mehta AC. Airway complications and management after lung transplantation: ischemia, dehiscence, and stenosis. *Proc Am Thorac Soc.* 2009;6:79-93.
- Schmid RA, Boehler A, Speich R, Frey HR, Russi EW, Weder W. Bronchial anastomotic complications following lung transplantation: still a major cause of morbidity? *Eur Respir J.* 1997;10:2872-5.
- Van De Wauwer C, Van Raemdonck D, Verleden GM, Dupont L, De Leyn P, Coosemans W, et al. Risk factors for airway complications within the first year after lung transplantation. *Eur J Cardiothorac Surg.* 2007;31:703-10.
- Kapoor BS, May B, Panu N, Kowalik K, Hunter DW. Endobronchial stent placement for the management of airway complications after lung transplantation. *J Vasc Interv Radiol.* 2007;18:629-32.
- Mulligan MS. Endoscopic management of airway complications after lung transplantation. *Chest Surg Clin N Am.* 2001;11:907-15.
- Murthy SC, Blackstone EH, Gildea TR, Gonzalez-Stawinski GV, Feng J, Budev M, et al. Impact of anastomotic airway complications after lung transplantation. *Ann Thorac Surg.* 2007;84:401-9.
- Date H, Trulock EP, Arcidi JM, Sundaresan S, Cooper JD, Patterson GA. Improved airway healing after lung transplantation: an analysis of 348 bronchial anastomoses. *J Thorac Cardiovasc Surg.* 1995;110:1424-32.
- Saad CP, Ghamande SA, Minai OA, Murthy S, Pettersson G, DeCamp M, et al. The role of self-expandable metallic stents for the treatment of airway complications after lung transplantation. *Transplantation.* 2003;75:1532-8.
- Garfein ES, McGregor CC, Galantowicz ME, Schulman LL. Deleterious effects of telescoped bronchial anastomosis in single and bilateral lung transplantation. *Ann Transplant.* 2000;5:5-11.
- Folch E, Mehta AC. Airway interventions in the tracheobronchial tree. *Semin Respir Crit Care Med.* 2008;29:441-52.
- Herrera JM, McNeil KD, Higgins RS, Coulters RA, Flower CD, Nashef SA, et al. Airway complications after lung transplantation: treatment and long-term outcome. *Ann Thorac Surg.* 2001;71:989-93.
- Ruttman E, Ulmer H, Marchese M, Dunst K, Geltner C, Margreiter R, et al. Evaluation of factors damaging the bronchial wall in lung transplantation. *J Heart Lung Transplant.* 2005;24:275-81.
- Chhajed PN, Malouf MA, Tamm M, Spratt P, Glanville AR. Interventional bronchoscopy for the management of airway complications following lung transplantation. *Chest.* 2001;120:1894-9.
- Hyytinen TA, Heikkilä LJ, Verkkala KA, Sipponen JT, Vainikka TL, Halme M, et al. Bronchial artery revascularization improves tracheal anastomotic healing after lung transplantation. *Scand Cardiovasc J.* 2000;34:213-8.
- Shennib H, Massard G. Airway complications in lung transplantation. *Ann Thorac Surg.* 1994;57:506-11.
- Takao M, Katayama Y, Onoda K, Tanabe H, Hiraiwa T, Mizutani T, et al. Significance of bronchial mucosal blood flow for the monitoring of acute rejection in lung transplantation. *J Heart Lung Transplant.* 1991;10:956-66.

17. Lima O, Cooper JD, Peters WJ, Ayabe H, Townsend E, Luk SC, et al. Effects of methylprednisolone and azathioprine on bronchial healing following lung autotransplantation. *J Thorac Cardiovasc Surg.* 1981;82:211-5.
18. Kshetry VR, Kroshus TJ, Hertz MI, Hunter DW, Shumway SJ, Bolman S RM. Early and late airway complications after lung transplantation: incidence and management. *Ann Thorac Surg.* 1997;63:1576-83.
19. Ruttman E, Ulmer H, Marchese M, Dunst K, Geltner C, Margreiter R, et al. Evaluation of factors damaging the bronchial wall in lung transplantation. *J Heart Lung Transplant.* 2005;24:275-81.
20. Erasmus D, Keller C, Alvarez F. Large airway complications in 150 consecutive lung transplant recipients. *Journal of Bronchology.* 2008;15:152-7.
21. Moreno P, Alvarez A, Algar FJ, Cano JR, Espinosa D, Cerezo F, et al. Incidence, management and clinical outcomes of patients with airway complications following lung transplantation. *Eur J Cardiothoracic Surg.* 2008;34:1198-205.
22. De Gracia J, Culebras M, Alvarez A, Catalán E, De la Rosa D, Maestre J, et al. Bronchoscopic balloon dilatation in the management of bronchial stenosis following lung transplantation. *Respir Med.* 2007;101:27-33.
23. Fernandez-Bussy S, Akindipe O, Kulkarni V, Swafford W, Baz M, Jantz MA. Clinical experience with a new removable tracheobronchial stent in the management of airway complications after lung transplantation. *J Heart Lung Transplant.* 2009;28:683-8.
24. Gottlieb J, Fuehner T, Dierich M, Wiesner O, Simon AR, Welte T. Are metallic stents really safe? A long-term analysis in lung transplant recipients. *Eur Respir J.* 2009;34:1417-22.
25. Dutau H, Cavailles A, Sakr L, Badier M, Gaubert JY, Boniface S, et al. A retrospective study of silicone stent placement for management of anastomotic airway complications in lung transplant recipients: short-and long-term outcomes. *J Heart Lung Transplant.* 2010;29:658-64.