

present heart failure and pulmonary hypertension. The anomalous vein on occasion can be seen on simple radiography, confirming the diagnosis by CT and MRI, and resorting to cardiac catheterization when given the suspicion of pulmonary hypertension.

## References

1. Morcel K, Camborieux L. Programme de recherches sur les aplasies müllériennes (PRAM) and Guerrier D. Mayer-Rokitansky-Küster-Hauser syndrome. *Orphanet J Rare Dis.* 2007;2:13.
2. Strübbe EH, Cremers CW, Wilemsen WN, Rolland R, Thijn CJ. The Mayer-Rokitansky-Küster-Hauser (MRKH) syndrome without and with associated features: two separate entities? *Clin Dysmorphol.* 1994;3:192-9.
3. Vasquez JC, De la Rosa J, Montesinos E, Rosales E, Duenas R, Rotta A, et al. Total anomalous pulmonary venous return and Mayer-Rokitansky-Küster-Hauser syndrome. *Int J Cardiol.* 2008;128:e104-6.

4. Ación P, Galan F, Manchón I, Ruiz E, Ación M, Alcaraz L. Hereditary renal adysplasia, pulmonary hypoplasia and Mayer-Rokitansky-Küster-Hauser (MRKH) syndrome: a case report. *Orphanet J Rare Dis.* 2010;5:6.

Vanessa Zorrilla-Lorenzo,\* Francisco Javier Ribas-Solis, Laura Tomás-López

*Servicio de Neumología, Hospital Txagorritxu, Vitoria-Gasteiz, Álava, Spain*

\* Corresponding author.

E-mail address: [vanessa.zorrillalorenzo@osakidetza.net](mailto:vanessa.zorrillalorenzo@osakidetza.net) (V. Zorrilla-Lorenzo).

doi:10.1016/j.arbr.2011.05.007

## Diffuse Pulmonary Lymphangiomas With Mediastinal Affection<sup>☆</sup>

### *Linfangiomas pulmonar difusa con afectación mediastínica*

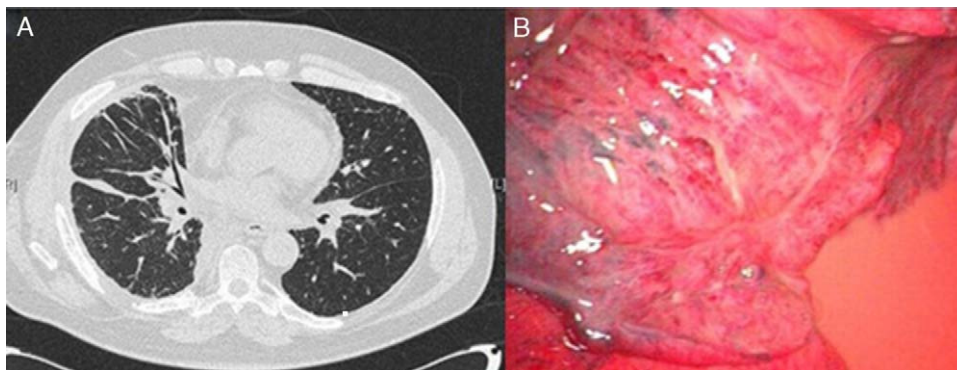
Dear Editor:

Lymphangiomas is an uncommon systemic disease characterized by a marked proliferation and dilatation of the lymphatic vessels.<sup>1</sup> It can appear as either localized or diffuse affection, in which case it is known as diffuse pulmonary lymphangiomas (DPL). It may affect newborns and young adults. Although it is a benign disease of unknown etiology and pathogeny, it presents a high rate of relapse and a poor prognosis.

We present the clinical case of a 55-year-old male patient, ex-smoker with a history of hypertension, dyslipidemia and COPD with bronchodilator treatment. He came to the emergency unit due to dyspnea with minimal exertion that had been evolving over the period of a month. The basic analytical data were normal; chest radiograph revealed basal bronchiectasis, and spirometry presented an obstructive pattern. On computed tomography (CT), multiple mediastinal lymphadenopathies were observed as well as perihilar interstitial affection (Fig. 1A) and pericardial effusion. Bronchoscopy revealed diffuse thickening of the bronchial mucosa and widening of the main and bronchial carinas. The mediastinal affection was studied using mediastinoscopy, where anthracotic-looking lymphadenopathies and fatty nodules were observed; their

biopsies presented lymphorrhea. The study of the liquid drained from the mediastinum confirmed that it was chylous with no malignant cellularity; the microscopic study of the lymphadenopathies was not conclusive. Afterwards, a lympho-gammagraphy was performed, where adequate lymphatic migration was seen without signs of leakage at the level of the thoracic duct. Given the lack of diagnosis and persistence of the dyspnea, pulmonary and mediastinal biopsies were taken by means of video-assisted thoracoscopy. The anatomopathologic study revealed proliferation of dilated capillary vessels in the pleura and septa and mediastinal adipose tissue with proliferation of anastomosed lymphatic vessels and lymphoid accumulations, leading to the definitive diagnosis of DPL. After successive episodes of dyspnea with minimal exertion secondary to pleural effusion (chylothorax), surgical treatment was indicated. Video-assisted thoracoscopy showed evidence of the characteristic proliferation and dilation of the lymphatic vessels and lymphorrhea in the lung parenchyma and mediastinum (Fig. 1B). Ligation of the thoracic duct and pleurodesis was carried out. Post-operative evolution was favorable, and the patient was discharged 10 days later.

DPL is an uncommon lymphatic alteration that appears in children and young adults, while it is quite exceptional in patients over the age of 40.<sup>1</sup> The most frequent symptom is dyspnea. It may be erroneously diagnosed as asthma responding to bronchodilator treatment, which was the reason for the late diagnosis in our case, previously diagnosed with COPD with bronchodilator treatment. It is associated with pleural effusions, other lymphatic abnormal-



**Fig. 1.** (A) Perihilar interstitial affection and mediastinal adenomegalies; (B) thoracoscopic image showing the dilatation of the subpleural lymphatic vessels, lymphorrhea and the resulting chylothorax.

<sup>☆</sup> Please cite this article as: Caballero Y, et al. Linfangiomas pulmonar difusa con afectación mediastínica. *Arch Bronconeumol.* 2011;47:474-5.

ities and in 75% of cases with bone alterations. The coexistence of chylothorax and lytic bone lesions may direct the diagnosis.<sup>1</sup> The definitive diagnosis should be histological, as the evidence on radiological images coincide with other alterations of the lymphatic system,<sup>2</sup> and mediastinal affectation is rare. In the case of recurring chylothorax, drainage and pleurodesis are indicated, with the option of thoracic duct ligation<sup>3</sup> to prevent complications such as malnutrition, pulmonary fibrosis and deteriorated respiratory function. In our case, we opted for ligation using a video-assisted thoracoscopic approach, which has not previously been reported in the literature in this pathology. Other treatments described are: radiotherapy, which causes sclerosis and fibrosis of the dilated lymphatic vessels, with good results<sup>4</sup>; INTalpha2b<sup>5</sup>; and bilateral lung transplantation.<sup>6</sup> It is a progressive disease with a high rate of relapse and poor prognosis, and the main cause of death is lung function deterioration secondary to infection or pleuropericardial effusion.

The case presented is especially unusual due to the age at which it debuted, which is the highest seen in the literature. It is also uncommon due to its clinical expression, with mediastinal lymphadenopathies and pleuroparenchymal affectation from its onset, unlike the majority of the published cases. Minimally invasive surgery was used for the diagnosis as well as for the treatment with positive results, and it has been shown to be an effective technique with minimal morbidity and mortality. Despite the poor prognosis of the disease, 5 years after the treatment the patient has not presented new episodes of pleuropericardial effusions, nor has he required hospitalization for other symptoms, currently presenting only exertional dyspnea.

## Acknowledgement

Dr. J. López, Pulmonology Department, for his collaboration and help.

## References

1. Faul JL, Berry GJ, Colby TV, Ruoss SJ, Walter MB, Rosen GD, et al. Thoracic lymphangiomas, lymphangiectasis, lymphangiomatosis, and lymphatic dysplasia syndrome. *Am J Respir Crit Care Med.* 2000;161:1037-46.
2. Raman S, Pipavath S, Raghu G, Schmidt R, Godwin J. Imaging of thoracic lymphatic diseases. *AJR Am J Roentgenol.* 2009;193:1501-13.
3. Rostom AY. Treatment of thoracic lymphangiomatosis. *Arch Dis Child.* 2000;83:138-9.
4. Bermejo EJ, Mongil R, Arrabal R, Fernández A, Benitez A, Fernández JL. Lymphangiomatosis torácica difusa: diagnóstico y tratamiento. *Arch Bronconeumol.* 2004;40:599-601.
5. Ozeki M, Funato M, Kanda K. Clinical improvement of diffuse lymphangiomatosis with pegylated interferon alfa-2b therapy: case report and review of the literature. *Pediatr Hematol Oncol.* 2007;24:513-24.
6. Kinnier CV, Eu JPC, Davis RD, Howell DN, Sheets J, Palmer SM. Successful bilateral lung transplantation for lymphangiomatosis. *Am J Transplant.* 2008;8:1946-50.

Y. Caballero,\* D. Pérez, J.R. Cano

*Sección de Cirugía Torácica, Servicio Cirugía General y del Aparato Digestivo*

\* Corresponding author.

*E-mail address:* [yure\\_hop@hotmail.com](mailto:yure_hop@hotmail.com) (Y. Caballero).

doi:10.1016/j.arbr.2011.06.005

## Bronchial Stenosis After Lung Transplantation<sup>☆</sup>

### *Estenosis bronquial postrasplante pulmonar*

*To the Editor:*

We have read with great interest the article recently published by Dr. Fernández-Bussy *et al.*<sup>1</sup> about the treatment of airway complications after lung transplantation. The authors describe their experience over the course of 8 years and suggest a treatment algorithm to follow. In our opinion, the study deals with a topic that is currently of great relevance since, first of all, there has been an important growth in lung transplantation activity and, secondly, the possible airway complications that may occur in these patients are not always treated in centers that are specialized in such airway affectations.

As the authors report, given stenosis of the bronchial anastomosis, endoscopic therapy using balloon dilation can be the first option for treatment, requiring the implantation of an endobronchial stent when, after 3 or 4 sessions, definitive results are not obtained. In our group, the most severe stenoses are treated with pneumatic dilation after previously performing radial cuts with electrocauterization in the fibrotic area of the stenosis, followed by the implantation of a stent in selected cases. In previous papers, our group has suggested that the local use of topical mitomycin C, after radial cuts with electrocautery and high-pressure balloon dilation, can avoid this latter measure in a selected sub-

group of patients.<sup>2,3</sup> The product is an anti-neoplastic agent that inhibits fibroblastic proliferation and has been widely used in locations other than the tracheobronchial tree.<sup>4,5</sup>

In our experience, since the beginning of the lung transplantation program in our center in October 1993, 335 lung transplantations have been carried out with 537 sutures at risk. A total of 45 airway complications have been detected in 34 patients (10.1% of the total of transplanted patients), the majority of these being in bilateral lung transplantations (60%).

During this period, 37 bronchial stenoses were registered in 28 patients, most of which were circumferential, and in 7 cases they were bilateral. We observed 22 stenoses with affectation only of the segment that encompassed the suture, 10 stenoses with affectation that was distal from the suture and prolonged up until the first- and second-order bronchi, and 5 combined both types. Regarding the therapeutic approach, 6 cases were mild stenoses in which we opted for a series of endoscopic follow-up studies, while 26 required mechanical dilatation and 5 patients were treated with laser-electrocauterization. As for the stenoses that progressed or relapsed after the first endoscopic treatment (n=18), 10 cases required the temporary placement of endoprostheses, while in 8 patients pneumatic dilation was combined with the endobronchial application of laser or electrocautery. In 2 of these cases, we added the local application of mitomycin C given the persistence of endoscopic treatments (Fig. 1). The requirement for this procedure was that at least 3 months had passed since the date of the transplantation. With this interval, the risk is avoided of suture dehiscence with this anti-fibrotic drug. Both cases evolved favorably with stabilization of the bronchial stenosis.

<sup>☆</sup> Please cite this article as: Arenas-De Larriva M, et al. Estenosis bronquial postrasplante pulmonar. *Arch Bronconeumol.* 2011;47:475-6.