

Case Report

**Paraneoplastic Thrombocytopenic Purpura Secondary to Pulmonary Squamous Cell Carcinoma**



Ignacio Boira Enrique\*, Cristina Senent Español, Anastasiya Torba Kordyukova, Eusebi Chiner Vives

*Pneumology Department, University Hospital of Saint John of Alicante, Spain*

We report the case of a 76-year-old patient who came to the emergency department for haemoptysis and oral bleeding of 3 days evolution associated with extensive facial hematoma. Examination revealed a stony hematoma at facial level that limited the opening of the oral cavity (Fig. 1a), petechiae in the lower limbs, right supraclavicular adenopathy and a palpable mass in the antero-superior region of the right hemithorax. Pulmonary auscultation showed abolition of vesicular murmur in the anterior region of the right hemithorax. Laboratory tests revealed leukocytosis with

neutrophilia, anemia (hemoglobin 11.1 g/dL) and a severe thrombopenia  $5 \times 10^9/L$ . Covid-19 antigen and PCR (polymerase chain reaction) were negative.

Chest X-ray manifested a mass in the anterior segment of the right upper lobe (Fig. 1b). On admission, blood tests were negative for autoimmunity, viral serology (HIV, hepatitis B and hepatitis C) and peripheral blood morphology confirmed thrombopenia without the presence of schistocytes. Treatment was started with systemic corticosteroids (1 mg/kg/day), transfusion of platelets and

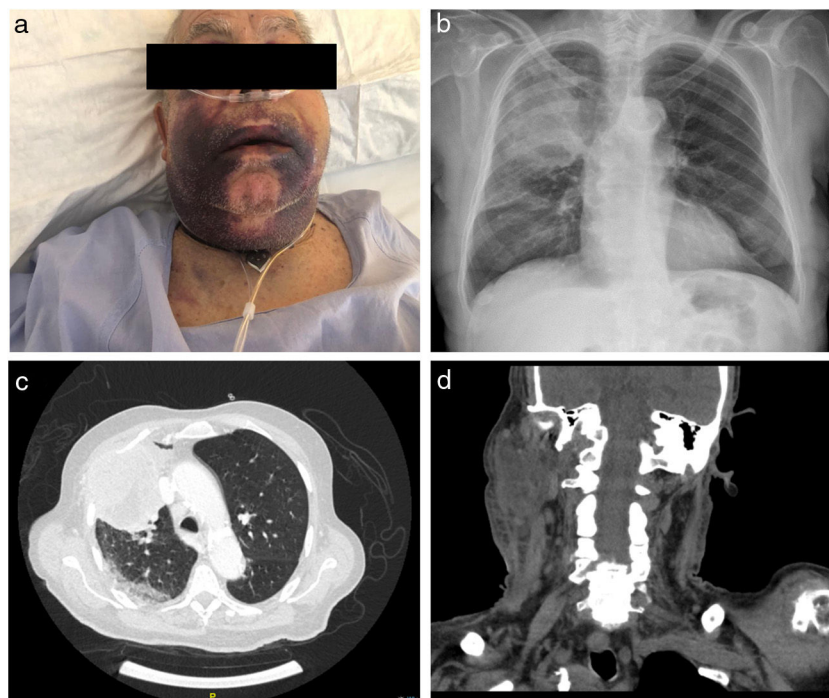


Fig. 1.

\* Corresponding author.  
E-mail address: [nachoboiraenrique@hotmail.es](mailto:nachoboiraenrique@hotmail.es) (I. Boira Enrique).

red blood cells and a cranial and cervicothoracic CT scan was requested. Chest CT (Fig. 1c) proved a mass in the anterior segment of the right upper lobe, with invasion of the anterior chest wall and lysis of the right 2nd costal arch, mediastinal and right hilar adenopathies. The cervicothoracic CT scan showed extensive haematic suffusion with diffuse haemifacial and bilateral cervical edema (Fig. 1d) and obliteration of the air lumen at the level of the oropharynx, at C1–C2. In view of the findings, admission to the Intensive Care Unit with nasotracheal intubation was decided, without initially performing a tracheostomy due to thrombopenia. Given the worsening of the thrombopenia, immunoglobulins 120 g/24 h intravenous for 48 h were started, after which platelet counts were corrected with marked improvement in haematomas with conservative treatment, and a transcutaneous ultrasound-guided biopsy of the lung mass was performed with the result of squamous cell carcinoma with negative immunohistochemistry for PD-L1.

Thrombocytopenia has been described mainly in lymphoproliferative syndromes and is rarely associated with solid tumors. The most frequent cause in cancer patients is bone marrow aplasia due to chemotherapy or radiotherapy. Other etiologies include marrow infiltration by the tumor, secondary to drugs or in relation to disseminated intravascular coagulation.<sup>1</sup>

Paraneoplastic syndromes occur in 10% of lung cancer patients and are associated with poor prognosis. Syndrome of inappropriate antidiuretic hormone secretion is most frequently associated with small cell carcinoma and hypercalcemia with non-small cell carcinoma.<sup>2</sup>

Hematological paraneoplastic syndromes are unusual in lung cancer manifesting as granulocytosis, eosinophilia, thrombocytosis and coagulopathy.<sup>3</sup>

Thrombocytopenic purpura consists of accelerated destruction and inadequate platelet production and is a diagnosis of exclusion.<sup>4</sup> It is described as a paraneoplastic pulmonary syndrome in few publications and is secondary to chemotherapy, small cell carcinoma

or adenocarcinoma. Treatment consists of systemic steroids and intravenous immunoglobulins with platelet transfusion support in case of severe hemorrhage. In severe cases, splenectomy can be performed.<sup>5</sup>

To our knowledge, we present the first clinical case described in the literature of paraneoplastic immune thrombocytopenic purpura secondary to pulmonary squamous cell carcinoma.

### Informed consent

The authors confirm that written consent has been obtained from patient.

### Funding

This work has not received funding of any kind.

### Conflict of interests

The authors state that they have no conflict of interests.

### References

1. Krauth MT, Puthenparambil J, Lechner K. Paraneoplastic autoimmune thrombocytopenia in solid tumors. *Crit Rev Oncol Hematol*. 2012;81:75–81, <http://dx.doi.org/10.1016/j.critrevonc.2011.02.004>.
2. Kanaji N, Watanabe N, Kita N, Bandoh S, Tadokoro A, Ishii T, et al. Paraneoplastic syndromes associated with lung cancer. *World J Clin Oncol*. 2014;5:197–223, <http://dx.doi.org/10.5306/wjco.v5.i3.197>.
3. Kasuga I, Makino S, Kiyokawa H, Katoh H, Ebihara Y, Ohyashiki K. Tumor-related leukocytosis is linked with poor prognosis in patients with lung carcinoma. *Cancer*. 2001;92:2399–405, [http://dx.doi.org/10.1002/1097-0142\(20011101\)92:9<2399::aid-cncr1588>3.0.co;2-w](http://dx.doi.org/10.1002/1097-0142(20011101)92:9<2399::aid-cncr1588>3.0.co;2-w).
4. Noor A, Rehan A, Desai A, Iorgoveanu C, Lee JC. Secondary immune thrombocytopenic purpura in renal cell cancer: a paraneoplastic syndrome. *Cureus*. 2019;11:e4398, <http://dx.doi.org/10.7759/cureus.4398>.
5. Zoppoli G, Balleari E, Bruzzone A, Mastracci L, Ghio R. Purpura as the initial presentation for small-cell lung cancer. *Onkologie*. 2009;32:277–9, <http://dx.doi.org/10.1159/000209318>.