

Clinical Image

A Silent Pulmonary Agenesis

Manuel David Viñuales-Aranda^{a,*}, Jorge Rodríguez-Sanz^a,
Ricardo Ignacio Gómez-Miranda^b

^a Department of Pulmology, Hospital Universitario Miguel Servet, Zaragoza, Spain

^b Department of Radiology, Hospital Universitario Miguel Servet, Zaragoza, Spain

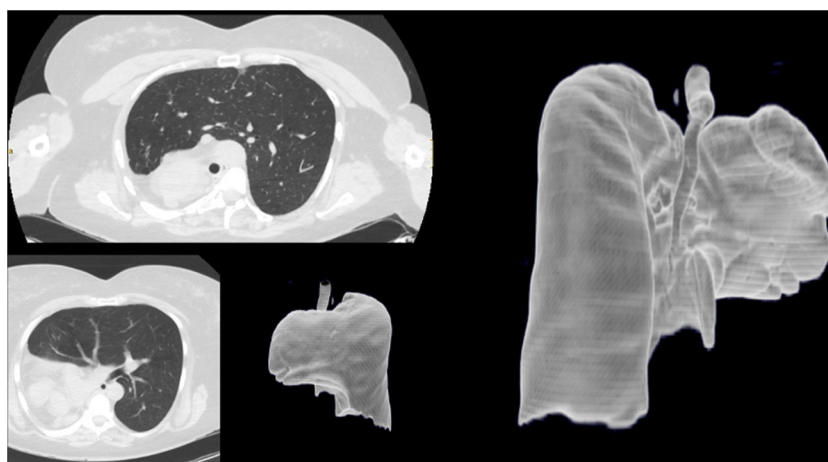


Fig. 1. Computed tomography revealed complete agenesis of the right lung with compensatory hyperinflation of the left lung.

Description

The term «agenesia» is interpreted as complete lack of lung formation.¹ Pulmonary agenesis can be very rarely diagnosed in adults and it is usually associated with infectious or respiratory symptoms. In addition, right lung agenesis has a worse prognosis.²

We present a 49-year-old woman with exposure to 2 pack-years of cigarette smoking, asthma and scoliosis.

She was referred to us to assess that condition. Her clinical presentation had always been typical of a healthy individual, without breathlessness, wheezing nor any signs of bronchial obstruction or respiratory insufficiency.

The computed tomography reported a complete agenesis of the right lung and right pulmonary veins, and right main artery stump is observed. There is a compensatory hyperinflation of the left lung which herniates through the anterior mediastinum (Fig. 1).

She has undergone many diagnostic procedures; the patient has a 71% of diffusing capacity of the lungs for carbon monoxide, which when is related to ventilation rises up to 103%, again, suitable for a healthy individual. The performance of stress tests, nevertheless, has revealed a slightly impaired ventilatory and cardiac performance to exercise, with a fast recovery.

References

1. Field CE. Pulmonary agenesis and hypoplasia. *Arch Dis Child*. 1946;21:61–75.
2. Cherian SV, Kumar A, Ocazonez D, Estrada-Y-Martin RM, Restrepo CS. Developmental lung anomalies in adults: a pictorial review. *Respir Med*. 2019;155:86–96.

* Corresponding author.

E-mail address: manuel.vinuales@hotmail.com (M.D. Viñuales-Aranda).