

Clinical Image

[Translated article] Multiple Solid Nodules at Post-COVID-19  
Follow-Up After Mild Pneumonia

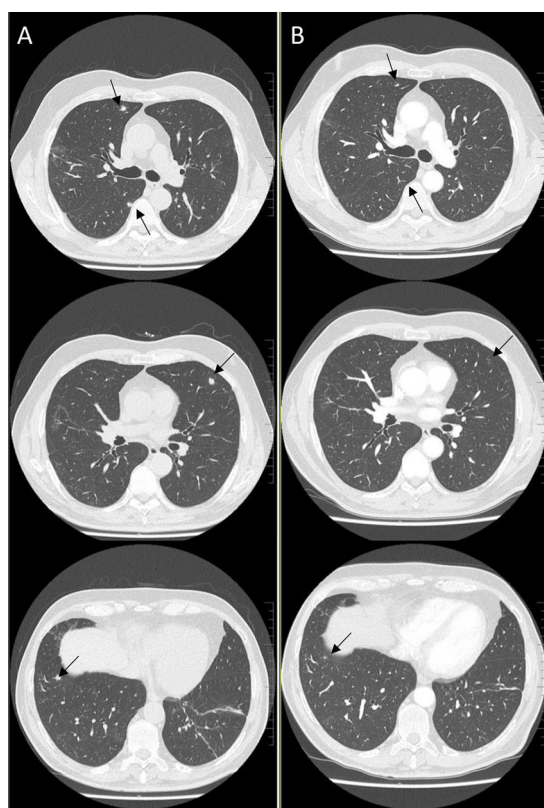


Múltiples nódulos sólidos en el seguimiento post-COVID-19 tras neumonía leve

Jaume Bordas-Martinez<sup>a</sup>, Belén del Río<sup>b</sup>, Maria Molina-Molina<sup>a,\*</sup>

<sup>a</sup> Unidad Funcional de Intersticio Pulmonar (UFIP), Departamento de Neumología, Hospital Universitario de Bellvitge, Instituto de Investigación Biomédica de Bellvitge (IDIBELL), Universidad de Barcelona, Hospitalet de Llobregat, Barcelona, Spain

<sup>b</sup> Departamento de Radiología, Hospital Universitario de Bellvitge, Instituto de Investigación Biomédica de Bellvitge (IDIBELL), Universidad de Barcelona, Hospitalet de Llobregat, Barcelona, Spain



**Fig. 1.** High-resolution computed tomography (A) showing multiple pulmonary nodules measuring less than 1 cm (black arrows) with partial resolution at 3 months (B).

Our patient was a 67-year-old man who had quit smoking 25 years previously (cumulative dose: 20 pack-years), with no other significant history. He was admitted for mild COVID-19 pneumonia (oxygen therapy 2–3 l/min) and treated with remdesivir and dexamethasone 8 mg/day for 10 days, and discharged with a protocolized tapering prednisone regimen. A high-resolution chest CT scan at 2 months (Fig. 1A) showed multiple solid bilateral pulmonary nodules measuring less than 1 cm and some atelectasis and fibrosis.

Multiple nodules observed on high-resolution computed tomography in patients with COVID-19 has been described previously.<sup>1</sup> However, the delayed appearance of multiple solid nodules of mild COVID-19 pneumonias without other inflammatory findings is atypical, and requires a differential diagnosis with neoproliferative and infectious processes. However, due to the patient's satisfactory clinical recovery and lack of reason for concern, we decided to prescribe prednisone 5 mg/day and repeat a high-resolution chest CT scan at 3 months (Fig. 1B), which showed progressive resolution of nodules. Although no pathology study was available, given the radiological progress and the clinical context, the diagnosis was organizing foci, which is an uncommon radiological presentation of organizing pneumonia.<sup>2</sup>

#### Funding

Research grants from ISCIII, PI21/01287 (co-funded by the European Regional Development Fund, EDF, a way to build Europe).

#### References

- Han X, Fan Y, Alwalid O, Li N, Jia X, Yuan M, et al. Six-month follow-up chest CT findings after severe COVID-19 pneumonia. *Radiology*. 2021;299:E177–86.
- Baque-Juston M, Pellegrin A, Leroy S, Marquette CH, Padovani B. Organizing pneumonia: What is it? A conceptual approach and pictorial review. *Diagn Interv Imaging*. 2014;95:771–7.

DOI of original article: <https://doi.org/10.1016/j.arbres.2021.06.017>

\* Corresponding author.

E-mail address: [mariamolinamolina@hotmail.com](mailto:mariamolinamolina@hotmail.com) (M. Molina-Molina).