

Clinical Image

## Cavitary *Mycobacterium avium* Complex Lung Disease Developed After Immunotherapy



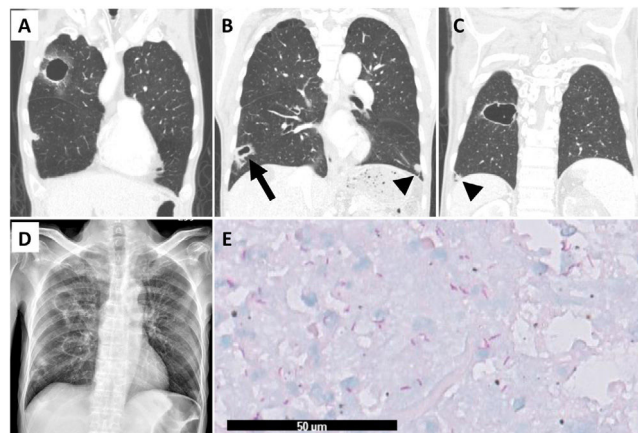
### Enfermedad pulmonar cavitaria por complejo *Mycobacterium avium* desarrollada tras inmunoterapia

Chien-Yeh Chi<sup>a</sup>, Yi-Chen Yeh<sup>b</sup>, Sheng-Wei Pan<sup>a,c,\*</sup>

<sup>a</sup> Department of Chest Medicine, Taipei Veterans General Hospital, Taipei, Taiwan

<sup>b</sup> Department of Pathology and Laboratory Medicine, Taipei Veterans General Hospital, Taipei, Taiwan

<sup>c</sup> School of Medicine, National Yang Ming Chiao Tung University, Taipei, Taiwan



**Fig. 1.** (A–C) The computed tomography revealed newly developed cavitary lesions in right upper and right lower lobes and pre-existing unchanged nodules (arrowheads). (D) The chest radiography showed corresponding cavitary lesions in right lung field. (E) The histopathologic finding in the wedged lung tissue (arrow in B) was extensive tissue necrosis with the presence of numerous acid-fast bacilli but no granuloma.

A 58-year-old man had renal cell carcinoma with liver metastases and started pembrolizumab, a programmed death-1 immune checkpoint inhibitor, plus axitinib. Six months later, after 8 doses of pembrolizumab, he developed productive cough. A chest radiography and computed tomography disclosed multiple cavitary lesions formation in right upper and right lower lobes without change in size of pre-existing nodules (Fig. 1A–D). The sputa were smear-positive for acid-fast bacilli and culture-positive for nontuberculous mycobacteria (NTM) isolates, which were identified as *Mycobacterium avium* complex (MAC) through genotyping method.

He received a thoroscopic wedge resection for cavitary lesion in right lower lobe to rule out lung metastasis. The histopathologic findings were acute and chronic inflammation with necrosis and the presence of acid-fast bacilli without granuloma (Fig. 1E). A diagnosis of cavitary MAC-pulmonary disease (PD) was made.

He initiated antibiotics treatment but discontinued 4 months later due to intolerance and drug-drug interaction. His sputa remained culture-positive for MAC.

Immunotherapies using immune-checkpoint inhibitors have improved outcomes in patients with cancers. However, a drug monitoring survey and case series reported development of NTM-PD after immunotherapy.<sup>1,2</sup> Although the impact of immunotherapy on mycobacterial infection remains uncertain, physicians should be aware of NTM-PD in patients receiving immunotherapy.

#### Conflicts of interest

The authors do not have any conflicts of interest.

#### References

1. Anand K, Sahu G, Burns E, Ensor A, Ensor J, Pingali SR, et al. Mycobacterial infections due to PD-1 and PD-L1 checkpoint inhibitors. *ESMO Open*. 2020;5:e000866.
2. Fujita K, Yamamoto Y, Kanai O, Okamura M, Nakatani K, Mio T. Development of *Mycobacterium avium* complex lung disease in patients with lung cancer on immune checkpoint inhibitors. *Open Forum Infect Dis*. 2020;7, ofaa067.

\* Corresponding author.  
E-mail address: [sanweipan@gmail.com](mailto:sanweipan@gmail.com) (S.-W. Pan).