

Clinical Image

A 'Pseudochylopleurothorax' at Presentation of Mesothelioma
Un 'pseudoquilonemotórax' como presentación de un mesotelioma

Maged Hassan^{a,b,*}, Cyrus Daneshvar^a, John P. Corcoran^a

^a Respiratory Medicine Department, University Hospitals Plymouth NHS Trust, Plymouth, UK

^b Chest Diseases Department, Alexandria University Faculty of Medicine, Alexandria, Egypt

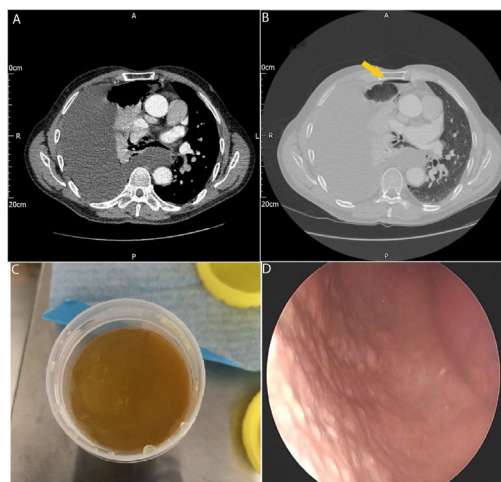


Fig. 1. Panels A and B show the chest computed tomography scan demonstrating a large pleural effusion with a small apical pneumothorax (arrow) with no evidence of pleural thickening. Panel C shows the opaque deep yellow pleural aspirate. Panel D shows thoracoscopic view of diffuse micro nodularity of the parietal pleura.

A 59 year-old male patient presented to the emergency department with progressive breathlessness. He worked as a ship builder. A chest radiograph revealed a large right-sided pleural effusion and a computed tomography (CT) scan (panel A and B) showed in addition to the effusion a small pneumothorax (arrow in panel B). Thoracentesis revealed an opaque deep yellow fluid that exhibited glossy whorls (panel C) suggesting a possible pseudochylopleurothorax. Fluid biochemistry showed an exudate with triglyceride 18 mg/dL and cholesterol 182 mg/dL and cytology was negative for malignant cells. At medical thoracoscopy diffuse micro-nodularity of the parietal pleura was noted (panel D) and pleural biopsies showed infiltration by poorly differentiated epithelioid cells. The immunohistochemistry was positive for calretinin and WT1 and negative for TTF1, CEA and BERP4 confirming a diagnosis of epithelioid malignant pleural mesothelioma.

Pseudochylopleurothorax describes effusions rich in cholesterol crystals. It usually has a milky appearance similar to chylopleurothorax but it occasionally exhibits a deep yellow 'opalescent' appearance which is likened to 'motor oil'.¹ A fluid cholesterol: triglyceride ratio >1 has the highest sensitivity for diagnosis.¹ Common causes for pseudochylopleurothorax are rheumatoid and tuberculous pleuritis

but a few cases of pleural adenocarcinoma manifesting with pseudochylopleurothorax exist in literature.¹ Spontaneous pneumothorax has been documented as an initial presentation of mesothelioma in adults above 40 years old.² To our knowledge, pseudochylopleurothorax in mesothelioma has not been previously reported. The pathological alteration in the structure of the pleura infiltrated by mesothelioma is possibly responsible for this presentation.

Authors' contribution

All authors treated the patient and collected the imaging. MH wrote the draft of the manuscript. CD and JPC critically revised the manuscript. All authors reviewed and approved the final manuscript.

Conflict of interest

No conflict of interest to declare.

References

- Madani Y, Fowler RW, Corcoran JP. An opalescent pleural effusion. J Bronchol Intervent Pulmonol. 2019;26:e16–7, <http://dx.doi.org/10.1097/LBR.0000000000000544>.
- Sheard JD, Taylor W, Soorae A, Pearson MG. Pneumothorax and malignant mesothelioma in patients over the age of 40. Thorax. 1991;46:584–5, <http://dx.doi.org/10.1136/thx.46.8.584>.

* Corresponding author.

E-mail address: magedhmf@gmail.com (M. Hassan).