

- with pharmacy refill records. *J Investig Allergol Clin Immunol*. 2019; <http://dx.doi.org/10.18176/jiaci.0461>.
2. Plaza V, Fernandez-Rodriguez C, Melero C, Cosio BG, Entrenas LM, de Llano LP, et al. Validation of the Test of the Adherence to Inhalers' (TAI) for asthma and COPD patients. *J Aerosol Med Pulm Drug Deliv*. 2016;29:142–52. <http://dx.doi.org/10.1089/jamp.2015.1212>.
 3. Makela MJ, Backer V, Hedegaard M, Larsson K. Adherence to inhaled therapies, health outcomes and costs in patients with asthma and COPD. *Respir Med*. 2013;107:1481–90. <http://dx.doi.org/10.1016/j.rmed.2013.04.005>.
 4. Rau JL. Determinants of patient adherence to an aerosol regimen. *Respir Care*. 2005;50:1346–56, discussion 1357–1359.
 5. Dekhuijzen R, Lavorini F, Usmani OS, van Boven JFM. Addressing the impact and unmet needs of nonadherence in asthma and chronic obstructive pulmonary disease: Where do we go from here? *J Allergy Clin Immunol Pract*. 2018;6:785–93. <http://dx.doi.org/10.1016/j.jaip.2017.11.027>.
 6. Klijn SL, Hilgsmann M, Evers S, Roman-Rodriguez M, van der Molen T, van Boven JFM. Effectiveness and success factors of educational inhaler technique interventions in asthma & COPD patients: A systematic review. *NPJ Prim Care Respir Med*. 2017;27:24. <http://dx.doi.org/10.1038/s41533-017-0022-1>.
 7. Tommelein E, Mehuys E, van Hees T, Adriaens E, van Bortel L, Christiaens T, et al. Effectiveness of pharmaceutical care for patients with chronic obstructive pulmonary disease (PHARMACOP): A randomized controlled trial. *Br J Clin Pharmacol*. 2014;77:756–66. <http://dx.doi.org/10.1111/bcp.12242>.
 8. Leiva-Fernandez J, Leiva-Fernandez F, Garcia-Ruiz A, Prados-Torres D, Barnestein-Fonseca P. Efficacy of a multifactorial intervention on therapeutic adherence in patients with chronic obstructive pulmonary disease (COPD): A randomized controlled trial. *BMC Pulm Med*. 2014;14:70. <http://dx.doi.org/10.1186/1471-2466-14-70>.
 9. Van Boven JF, Ryan D, Eakin MN, Canonica GW, Barot A, Foster JM. Enhancing respiratory medication adherence: The role of health care professionals and cost-effectiveness considerations. *J Allergy Clin Immunol Pract*. 2016;4:835–46. <http://dx.doi.org/10.1016/j.jaip.2016.03.007>.
 10. Global Strategy for the Diagnosis, Management and Prevention of COPD, Global Initiative for Chronic Obstructive Lung Disease (GOLD). 2020 [consultado 20 Ene 2020]. Disponible en: <https://goldcopd.org/wp-content/uploads/2019/12/GOLD-2020-FINAL-ver1.2-03Dec19.WMV.pdf>.
 11. Miravittles M, Soler-Cataluna JJ, Calle M, Molina J, Almagro P, Quintano JA, et al. Spanish Guidelines for Management of Chronic Obstructive Pulmonary Disease (GesEPOC) 2017. Pharmacological treatment of stable phase. *Arch Bronconeumol*. 2017;53:324–35. <http://dx.doi.org/10.1016/j.arbres.2017.03.018>.
 12. Plaza V, Giner J, Rodrigo GJ, Dolovich MB, Sanchis J. Errors in the use of inhalers by health care professionals: A systematic review. *J Allergy Clin Immunol Pract*. 2018;6:987–95. <http://dx.doi.org/10.1016/j.jaip.2017.12.032>.
 13. Plaza V, Lopez-Vina A, Entrenas LM, Fernandez-Rodriguez C, Melero C, Perez-Llano L, et al. Differences in adherence and non-adherence behaviour patterns to inhaler devices between COPD and asthma patients. *COPD*. 2016;13:547–54. <http://dx.doi.org/10.3109/15412555.2015.1118449>.

Vicente Plaza^{a,*}, Carmen Fernández^a, Elena Curto^a,
M. Beln Alonso-Ortiz^b, Miren Itxaso Orue^c,
José María Vega^d, Borja G. Cosío^e y Jordi Giner^a

^a Servicio de Neumología y Alergia, Hospital de la Santa Creu i Sant Pau, Institut d'Investigació Biomèdica Sant Pau (IIB Sant Pau), Universitat Autònoma de Barcelona, Barcelona, España

^b Hospital Universitario de Gran Canaria Doctor Negrín, Las Palmas de Gran Canaria, España

^c Centro de Salud Javier Sáenz de Buruaga, Bilbao, España

^d Hospital Regional Universitario de Málaga, Málaga, España

^e Hospital Universitario Son Espases-IDISBa y CIBERES, Palma de Mallorca, España

* Autor para correspondencia.

Correo electrónico: vplaza@santpau.cat

(V. Plaza).

<https://doi.org/10.1016/j.arbres.2020.09.001>

0300-2896/© 2020 SEPAR. Publicado por Elsevier España, S.L.U. Todos los derechos reservados.

Massive Pulmonary Thrombosis Following Haemoptysis in Type IV Ehlers–Danlos Syndrome



Trombosis pulmonar masiva tras hemoptisis en el Síndrome de Ehlers–Danlos tipo IV

Dear Editor:

Ehlers–Danlos syndromes (EDS) are a group of rare genetic disorders that affect connective tissue, characterized by joint hypermobility, skin hyperextensibility, and tissue fragility. The majority of the currently recognized 13 EDS subtypes¹ are due to gene variants leading to impaired synthesis or structural abnormalities of different collagen types. Type IV or vascular EDS (EDS-IV) is an autosomal dominant multisystem disease caused by defects in type III collagen, encoded by the *COL3A1* gene, in chromosome 2 (2q32.2).¹ Type III collagen is a major constituent of the interstitial matrix in many tissues, including blood vessels. Accordingly, aneurysms and rupture of large arteries, spontaneous bowel perforation and uterine rupture during pregnancy are life-threatening complications of EDS-IV. EDS-IV is the most severe form of EDS, with most individuals dying before the 5th decade.¹ Pulmonary involvement may occur without extrathoracic manifestations,^{2–6} and the diagnosis of such cases may be made only at post-mortem examination.⁵ Spontaneous pneumothorax or haemopneumothorax are the most frequent complications, but cavitory lesions, haemoptysis and pulmonary haemorrhage have also been reported.^{2–6}

Herein, we report the occurrence of severe haemoptysis associated with massive pulmonary thrombosis, with a fatal outcome, in a young adult male with EDS-IV. The patient's diagnosis was

established by genetic testing in mid-adolescence, as soon as the family's pathogenic *COL3A1* (c.3517_3519del/p.(Gly1173del)) variant was identified. The patient had been free of significant EDS-related complications until the age of 17 years. The patient's father and one maternal aunt died from spontaneous aortic dissection/rupture, early in the 4th decade of life.

Our patient had a first hospital admission for haemoptysis at the age of 17. At the time, small areas of ground-glass opacities suggestive of alveolar haemorrhage were observed on chest computed tomography (CT). Over the next two years, he had occasional episodes of small-volume haemoptysis, often preceded by a tingling sensation in the head and neck.

At age 19, the patient needed hospitalization for large-volume haemoptysis. In the previous days, he had intermittent episodes of small-volume haemoptysis preceded by what he described as a “clicking” sensation in the head and, right-sided paraesthesia and mild motor weakness. The chest CT scan (late arterial phase) showed multiple bilateral ground-glass opacities suggestive of diffuse alveolar haemorrhage and large fluid-filled cavities with air-fluid levels suggestive of haemorrhagic cavitation (Fig. 1A/B). Brain and cervical magnetic resonance (MR) imaging, MR angiography of the carotid and vertebral basilar circulations, including the supra-aortic arches, and electroencephalogram were unremarkable. Despite the decrease in the haemoglobin level relative to baseline (respectively 15.3 g/dL and 13.8 g/dL), the patient remained hemodynamically stable without respiratory failure. Cough suppressive and antifibrinolytic therapies were initiated. Since the patient did not have any bronchial artery hypertrophy on CT scan and due to the high risk of vascular manipulation, bronchial arteriography was not performed. The surgical risk was also very high; therefore, the patient was not a candidate for thoracic surgery at that time.

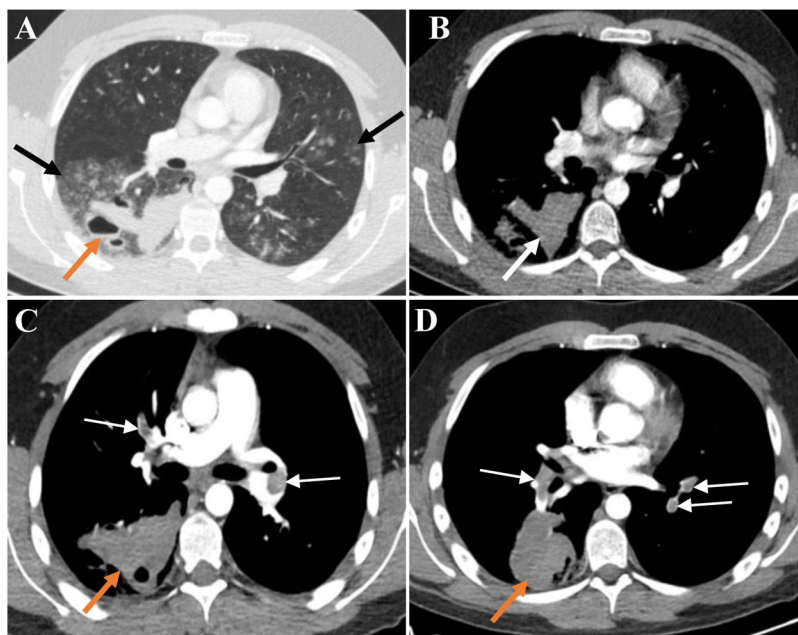


Fig. 1. (A) Late arterial phase chest CT depicts bilateral peribronchovascular groundglass opacities (GGO), especially in the right lower lobe (black arrows). In the right lower lobe thick-walled cavitory lesions with air–blood levels are also seen (orange arrow). The high density of blood-containing cavities is illustrated in B (white arrow). The GGO translate diffuse alveolar haemorrhage and the cavitory lesions result from the spontaneous rupture of the lung. There was no evidence of haemothorax or pneumothorax. (C and D) CT pulmonary angiographic study shows bilateral pulmonary thromboembolism (white arrows) and enlarged haemorrhagic cavity in the right lower lobe (orange arrows). No signs of pulmonary hypertension or right ventricular strain were present.

A pulmonary CT angiography obtained on day 7 of hospital stay showed extensive bilateral thrombosis and an enlargement of the haemorrhagic parenchymal cavitation, but no actively bleeding arteries (Fig. 1C/D). There were no signs of deep vein thrombosis on Doppler ultrasound examination of the lower limbs. Despite the striking radiological signs, the patient remained asymptomatic. Transthoracic echocardiogram did not show any signs of right ventricular dysfunction, and the Pulmonary Embolism Severity Index (PESI) score was 29 (class I), translating into a low mortality risk.⁷ Given the high bleeding risk and the low overall risk stratification, hypocoagulation was not prescribed.

Two days later, the patient was admitted to the intensive care unit, following a syncope episode with echocardiographic evidence of right ventricular dysfunction. Anticoagulation with unfractionated heparin and inotropic support were instituted. After about 24 h of clinical stability, his haemodynamic condition suddenly deteriorated due to supraventricular tachycardia, followed by cardiac arrest that did not respond to advanced life support measures and thrombolysis. Autopsy was not performed.

To our knowledge, this is the first report of massive pulmonary thrombosis in a patient with EDS-IV seeking medical attention for recurrent haemoptysis. Arterial bleeding complications are typical of EDS-IV and several cases of severe haemoptysis, including with fatal outcomes, have been described.^{2,4,6} Platelet dysfunction may additionally aggravate the constitutional haemorrhagic propensity.⁸ Contrastingly, thrombotic events seem to be exceedingly rare in patients with EDS,⁹ but have been reported in EDS-IV^{10–12} and other EDS subtypes.^{9,13} In one of the EDS-IV cases, the patient had renal infarctions caused by emboli from a thrombotic renal artery aneurysm, and hypocoagulation was not prescribed either, with a favourable outcome.¹²

Major treatment decisions taken in our patient were based on validated risk stratification algorithms for pulmonary embolism/thrombosis⁷ and current clinical approaches to the management of haemoptysis.¹⁴ The delay in starting anticoagulation and the antifibrinolytic therapy might have facilitated the thrombotic event. Furthermore, haemostatic abnormalities were not screened, such as coexisting prothrombotic conditions or vitamin-D deficiency, which have been suggested as prognostic modulators in EDS-IV.^{8,11,15} However, taking into consideration the enlarging haemorrhagic cavitory lesion, the haemorrhagic propensity and the possibility of platelet dysfunction, the bleeding risk seemed to prevail when we decided not to initiate hypocoagulation therapy.

Despite the comprehensive neuroradiological and electroencephalographic evaluation, the aetiology of the neurological symptoms in close temporal association with the episodes of haemoptysis remained elusive, which is in line with previous observations in EDS-IV patients.^{3,4} In this case, a post-mortem examination could have been useful to characterize the lung pathology,^{4,6} as well as to elucidate the aetiology of the pulmonary embolism/thrombosis, but could not be carried out.

With this report, we aim to call the attention of respiratory physicians to this rare disorder, since haemoptysis, pneumothorax and pulmonary substance loss with cavitation can be the presenting manifestation of EDS-IV. Our patient illustrates the complexity of the pulmonary involvement in EDS-IV and the challenge of managing its haemorrhagic complications since the excessive vascular and tissue friability restricts diagnostic and therapeutic options. As in other rare, multisystem disorders, specific evidence-based treatment guidelines are not available, and patient care by multidisciplinary care teams is highly recommended.¹

As in other rare, multisystem disorders, specific evidence-based treatment guidelines are not available, and patient care by multidisciplinary care teams is highly recommended.¹

Bibliografía

- Malfait F, Castori M, Francomano CA, Giunta C, Kosho T, Byers PH, et al. The Ehlers–Danlos syndromes. *Nat Rev Dis Primers*. 2020;6:64. <http://dx.doi.org/10.1038/s41572-020-0194-9>.
- Downton SB, Pincott S, Demmer L. Respiratory complications of Ehlers–Danlos syndrome type IV. *Clin Genet*. 1996;510–4. <http://dx.doi.org/10.1111/j.1399-0004.1996.tb02724.x>.

3. Watanabe A, Kawabata Y, Okada O, Tanabe N, Kimura H, Hatamochi A, et al. Ehlers-Danlos syndrome type IV with few extrathoracic findings: a newly recognized point mutation in the COL3A1 gene. *Eur Respir J*. 2002;19:195–8, <http://dx.doi.org/10.1183/09031936.02.00219202>.
4. Yost BA, Vogelsang JP, Lic JT. Fatal hemoptysis in Ehlers-Danlos syndrome: old malady with a new course. *Chest*. 1995;107:1465–7, <http://dx.doi.org/10.1378/chest.107.5.1465>.
5. Herman TE, McAlister WH. Cavitory pulmonary lesions in type IV Ehlers-Danlos syndrome. *Pediatr Radiol*. 1994;24:263–5, <http://dx.doi.org/10.1007/BF02015451>.
6. Hatake K, Morimura Y, Kudo R, Kawashima W, Kasuda S, Kuniyasu H. Respiratory complications of Ehlers-Danlos syndrome type IV. *Leg Med*. 2013;15:23–7, <http://dx.doi.org/10.1016/j.legalmed.2012.07.005>.
7. Konstantinides SV, Meyer G, Bueno H, Galie N, Gibbs JSR, Agno W, et al., 2019 ESC Guidelines for the diagnosis and management of acute pulmonary embolism developed in collaboration with the European respiratory society (ERS). *Eur Heart J*. 2020;41:543–603, <http://dx.doi.org/10.1093/eurheartj/ehz405>.
8. Busch A, Hoffjan S, Bergmann F, Hartung B, Jung H, Hanel D, et al. Vascular type Ehlers-Danlos syndrome is associated with platelet dysfunction and low Vitamin D serum concentration. *Orphanet J Rare Dis*. 2016;11:1–8, <http://dx.doi.org/10.1186/s13023-016-0491-2>.
9. D'hondt S, Van Damme T, Malfait F. Vascular phenotypes in nonvascular subtypes of the Ehlers-Danlos syndrome: a systematic review. *Genet Med*. 2018;20:562–73, <http://dx.doi.org/10.1038/gim.2017.138>.
10. Gilchrist D, Schwarze U, Shields K, MacLaren L, Bridge PJ, Byers PH. Large kindred with Ehlers-Danlos syndrome type IV due to a point mutation (G571S) in the COL3A1 gene of type III procollagen: low risk of pregnancy complications and unexpected longevity in some affected relatives. *Am J Med Genet*. 1999;82:305–11. PMID: 10051163.
11. Refaat M, Hotaït M, Winston B. Homozygous factor V Leiden mutation in type IV Ehlers-Danlos patient. *World J Clin Cases*. 2014;2:75, <http://dx.doi.org/10.12998/wjcc.v2.i3.75>.
12. Yigal A, Tal H, Nurit H, Tova CS, Hershcovici T. Thromboembolic renal infarction due to a renal artery aneurysm in a patient with Ehlers-Danlos syndrome type IV. *Eur J Intern Med*. 2006 Aug;17:377–9, <http://dx.doi.org/10.1016/j.ejim.2006.02.008>.
13. Jiménez-Encarnación E, Vilá LM. Recurrent venous thrombosis in Ehlers-Danlos syndrome type III: an atypical manifestation. *BMJ Case Rep*. 2013;1–3, <http://dx.doi.org/10.1136/bcr-2013-008922>.
14. Cordovilla R, Bollo de Miguel A, Nuñez Ares A, Cosano Povedano FJ, Herráez Ortega I, Jiménez Merchán R, et al. Diagnóstico y tratamiento de la hemoptisis. *Arch Bronconeumol*. 2016;52:368–77, <http://dx.doi.org/10.1016/j.arbr.2016.05.010>.
15. Artoni A, Bassotti A, Abbattista M, Marinelli B, Lecchi A, Gianniello F, et al. Hemostatic abnormalities in patients with Ehlers-Danlos syndrome. *J Thromb Haemost*. 2018;16:2425–31, <http://dx.doi.org/10.1111/jth.14310>.

Leonor Mendonça Almeida^{a,*}, Célia Sousa^b,
Paulo Vilares Morgado^b, Pedro Fernandes^c, José Amado^d,
José Artur Paiva^{d,e}, Anabela Marinho^a, João Paulo Oliveira^{f,g,h}

^a Pulmonology Department, Centro Hospitalar e Universitário São João, Porto, Portugal

^b Radiology Department, Centro Hospitalar e Universitário São João, Porto, Portugal

^c Cardiothoracic Surgery Department, Centro Hospitalar e Universitário São João, Porto, Portugal

^d Intensive Care Medicine Department, Centro Hospitalar e Universitário São João, Porto, Portugal

^e Internal Medicine Department, Faculty of Medicine of University of Porto, Portugal

^f Medical Genetics Department, Centro Hospitalar e Universitário São João, Porto, Portugal

^g Unit of Genetics, Department of Pathology, Faculty of Medicine of University of Porto, Portugal

^h i3S – Institute for Research and Innovation in Health/Instituto de Investigação e Inovação em Saúde da Universidade do Porto, Portugal

* Corresponding author.

E-mail address: leonor.fma@gmail.com

(L. Mendonça Almeida).

<https://doi.org/10.1016/j.arbres.2020.12.020>

0300-2896/© 2020 SEPAR. Published by Elsevier España, S.L.U. All rights reserved.

PD-1 Inhibitor for a Non-Small-Cell Lung Cancer Patient With Paraneoplastic Nephropathy



Tratamiento con un inhibidor de la PD-1 para un paciente con cáncer de pulmón no microcítico con nefropatía paraneoplásica

Dear Editor,

Paraneoplastic syndromes are clinical manifestations of spontaneous antitumor immune responses against antigen proteins

expressed on tumor cells. The most common paraneoplastic nephropathy associated with solid tumors is membranous nephropathy (MN), and the estimated prevalence of tumors in patients with MN is around 10%.¹ And the majority of tumors related to MN are lung cancer.^{1,2}

The advent of an immune checkpoint inhibitor dramatically changed the treatment of various tumors. In metastatic non-small cell lung cancer (NSCLC), the inhibitors of programmed death 1 (PD-1) or programmed death-ligand 1 (PD-L1) significantly prolonged overall survival compared with that of chemotherapy and

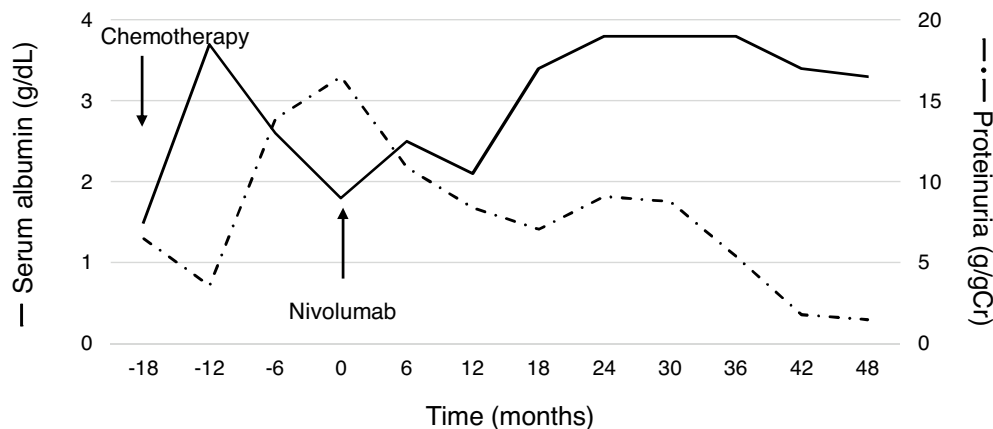


Fig. 1. Laboratory data related to nephrotic syndrome. The values of proteinuria were calculated by urine protein-to-creatinine ratio.