

Clinical Image

Bilothorax: A Rare Complication of Gallstone Disease

Biliorax: Una complicación rara de los cálculos biliares

Narat Srivali^{a,b,*}, Federica De Giacomi^{a,b}

^a Division of Pulmonary Medicine (NS), St. Agnes Hospital, Baltimore, MD 21229, USA

^b Respiratory Unit (FG), Cremona Hospital, Cremona, Italy

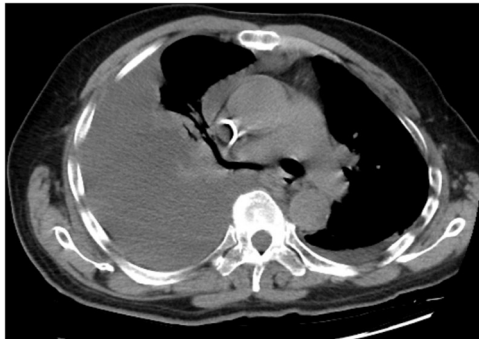


Fig. 1A. Computed tomography of the chest revealed Large right pleural effusion nearly fills the right thoracic cavity.



Fig. 1B. Dark green "Bilothorax" pleural fluid.

A 74-year-old man presented with right upper quadrant abdominal pain along with dyspnea for 1 day. Computed tomography of the chest, abdomen, and pelvis demonstrated right-sided pleural effusion (Fig. 1A) and Acute gallstone cholecystitis. Thoracentesis showed dark green pleural effusion (Fig. 1B). Analysis of the fluid revealed pleural bilirubin was 9.5 mg/dl compared with serum bilirubin of 4.7 mg/dl and a diagnosis of bilothorax was made. Cytology was benign and bacterial cultures were negative. The patient underwent chest tube drainage and cholecystectomy. Postoperatively, the patient recovered well and no evidence of recurrent pleural effusion.

Bilothorax is a rare cause of pleural effusion.¹ The most common etiologies are biliary obstruction as in our case, diaphragmatic trauma, and iatrogenic complication of percutaneous hepatobiliary drain insertion.² Most cases of bilothorax are located on right side, in extremely rare case, bilothorax can represent as bilateral pleural effusion.³ The pleural fluid to serum (PF/S) bilirubin ratio greater than one is highly suggestive of bilothorax, with higher ratios making the diagnosis more likely. Almost half of the bilious pleural effusions are infected and require immediate drainage of the effusion along with early administration of antibiotics to prevent

empyema and fibropurulent effusions.¹ Patients with bilothorax require either direct surgical approach, percutaneous drainage of the biliary tree, or endoscopic retrograde cholangiopancreatography to alleviate biliary obstruction.²

Funding

None.

Conflict of interest

None for all authors.

References

1. Frampton AE, Williams A, Wilkerson PM, Paterson IM. Thoracobilia: a rare complication of gallstone disease. *Ann R Coll Surg Engl.* 2010;92:e1-3. <http://dx.doi.org/10.1308/147870810X12659688851951>.
2. Jenkinson MR, Campbell W, Taylor MA. Bilothorax as a rare sign of intra-abdominal bile leak in a patient without peritonitis. *Ann R Coll Surg Engl.* 2013;95:e12-3. <http://dx.doi.org/10.1308/003588413X13629960047678>.
3. Shah K, Ravikumar N, Uddin QK, McGee W, Farmer MJS. Bilateral bilothorax: an unusual cause of bilateral exudative pleural effusion. *Cureus.* 2019;11:e5185. <http://dx.doi.org/10.7759/cureus.5185>.

* Corresponding author.

E-mail address: nsrivali@gmail.com (N. Srivali).