

Clinical Image

Coughing Up a Tumor – Renal Clear Cell Carcinoma Metastasis

Expectorando un tumor: una metástasis de carcinoma renal de células claras

Yahua Li, Jianzhuang Ren, Xinwei Han*

Department of Interventional Radiology, The First Affiliated Hospital of Zhengzhou University, Zhengzhou 450052, PR China

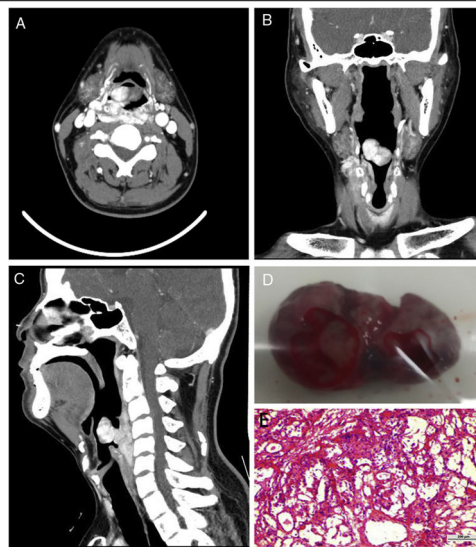


Fig. 1.

A 39-year-old man was admitted to our department with a 2-months history of foreign body sensation in the throat and aggravated 1 week. He complained of intermittent cough. No dyspnoea and dysphagia. Contrast-enhanced computed tomography revealed a strikingly enhancing tumor located the pharyngoesophageal junction with a mass protruding into the laryngeal vestibule. Images from transverse (Panel A), coronal (Panel B) and sagittal (Panel C) planes showed a bilateral hypopharynx and pharyngoesophageal junction enhancing mass. The tumor was extending outward through the cricothyroid space and indistinguishable from the right upper pole of the thyroid. A surgical resection of the tumor was planned. However, he suddenly coughed up a tumor mass with a small amount of bleeding and blood clot on the second night after hospitalization. The size of the coughed up tumor mass is 2 cm × 3 cm × 1 cm (Panel D). The pathological result suggested that the coughed tumor is hemangiomatous polyp (Panel E). Considering the risk of massive bleeding, transarterial embolization was performed for the remaining polypoid lesion and

the tumor located at the hypopharynx and pharyngoesophageal junction. The final pathological result of the surgical sample indicated that the tumor was renal clear cell carcinoma metastasis. The left renal mass was confirmed on US and CT after the diagnosis. Subramanyam et al.¹ reported one similar case (Fig. 1).

Informed consent

Informed consent was obtained from the patient for the publication of their information and imaging.

Funding

Not applicable.

Conflicts of interest

The authors declare no conflicts of interest in this work.

Reference

1. Subramanyam NS, Fendley H, Freeman WH. Coughing up of metastatic tumor as the initial clinical manifestation of renal cell carcinoma. *J Ark Med Soc.* 1991;88:86–7.

* Corresponding author.
E-mail address: fcchanxw@zzu.edu.cn (X. Han).