

Clinical Image

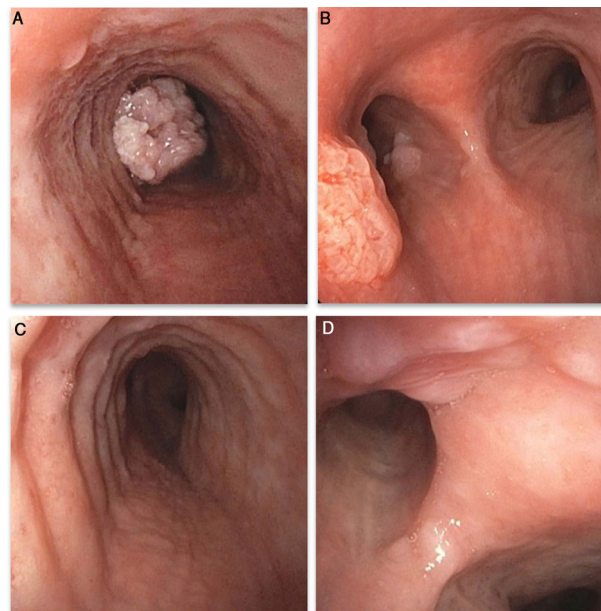
Endobronchial Papillomatosis of the Central Airways

Papillomatosis endobronquial de las vías aéreas centrales

Vicente Espinosa<sup>a</sup>, Ilaria Bologna<sup>b,\*</sup>, Maurizio Bernasconi<sup>a</sup>

<sup>a</sup> Division of Pulmonology, Department of Medicine, Hospital of Bellinzona, Switzerland

<sup>b</sup> Division of Internal Medicine, Department of Medicine, Hospital of Bellinzona, Switzerland



**Fig. 1.** A (left main bronchus) and B (distal trachea): endobronchial papillomatous lesion as seen before debulking; C and D: final result 18 months after initial presentation and first debulking.

We present the case of a 47-year-old male known for COPD who developed an 8-month history of nonproductive cough and dyspnea. CT scan showed a mass on the distal trachea and left main bronchus projecting into the lumen, thus resulting in a partial atelectasis of the left lower lobe. Bronchoscopy revealed an exophytic lesion arising from the mucosa of the distal trachea and the left main bronchus almost completely occluding the latter. Rigid bronchoscopy was performed for debulking and allowed complete recanalization of the left main bronchus. Pathology and microbiology results were compatible with endoluminal papillomatosis caused by human papilloma virus 11 (HPV11). At 3 months' follow up, recurrence was visible; intralesional injection of cidofovir was therefore performed, allowing substantial regression of the lesions at 18 months' follow up (Fig. 1).

The term recurrent respiratory papillomatosis (RRP) describes the presence of papillomas involving the respiratory epithelium.<sup>1,2</sup> Although benign, disease course is often characterized by recurrence of lesions and risk for airway compromise. No curative therapy is available; surgery therefore remains the mainstay for treatment. However, adjunctive pharmacological treatment, in particular with intralesional cidofovir, can decrease the need for repeated surgical intervention and has even demonstrated complete regression of papillomas.<sup>1</sup>

**References**

- Ivanic R, Iqbal H, de Silva B, Pan Q, Matrkka L. Current and future management of recurrent respiratory papillomatosis. *Laryngoscope Invest Otorlaryngol.* 2018;3:22–34.
- Lee JH, Smith RJ. Recurrent respiratory papillomatosis: pathogenesis to treatment. *Curr Opin Otolaryngol Head Neck Surg.* 2005:354–9.

\* Corresponding author.

E-mail addresses: ilabologna@yahoo.it, ilaria.bologna@eoc.ch (I. Bologna).