

Clinical Image

Hair in the bronchus

Pelo en el bronquio

Saurabh Mittal*, Karan Madan, Pawan Tiwari

Department of Pulmonary, Critical Care and Sleep Medicine All India Institute of Medical Sciences (AIIMS), New Delhi, India



A 27-years-old male presented with streaky hemoptysis for last 7 years. For the last two years he started having strands of hair along with blood in his sputum. There was no history of associated constitutional symptoms. There was no significant past history and he was a lifelong never smoker. A general physical and systemic examination (including the genital examination) was unremarkable. CT scan of the thorax demonstrated an anterior mediastinal mass with peripheral calcification. A flexible bronchoscopic examination was performed subsequently which revealed a growth in the lateral segment of the right middle lobe with overlying hair strands which were removed using forceps (Fig. 1, Video 1). A diagnosis of

a mediastinal cystic teratoma with bronchial communication was made. The patient underwent mediastinal mass excision along with right middle lobectomy.

Teratomas arise from pluripotent stem cells and usually contain structures originating from all three germinal layers.¹ They commonly occur in ovary, testis and mediastinum. Within the mediastinum the most common location of the cystic teratoma is the anterior mediastinum. Most common type of benign mediastinal germ tumor cell is cystic teratoma. Mediastinal teratoma rarely present with communication to adjacent structures such as bronchial tree or lung parenchyma. Trichoptysis is a rare symptom but is considered pathognomonic of teratoma with bronchial communication.²

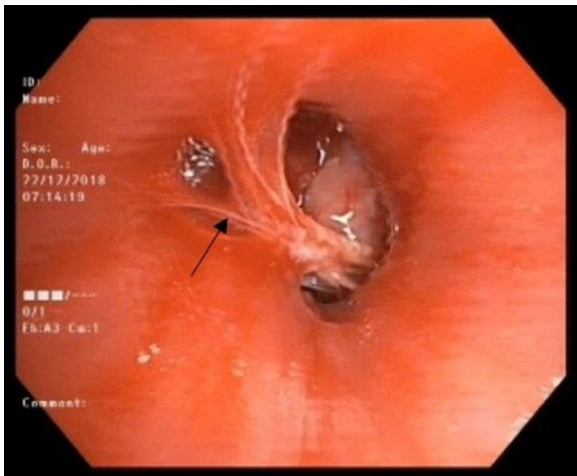


Fig. 1. Bronchoscopic view demonstrating growth in middle lobe with white hair strands seen overlying the growth.

Funding

None.

Conflict of interest

None of the authors have any conflict of interest.

Appendix A. Supplementary data

Supplementary data associated with this article can be found, in the online version, at [doi:10.1016/j.arbres.2020.07.010](https://doi.org/10.1016/j.arbres.2020.07.010).

References

1. Makarawo TP, Finnikin S, Woolley S, Bishay E. Trichoptysis: a hairy presentation of a rare tumour. *Interact Cardiovasc Thorac Surg.* 2009;9:733–5.
2. Agarwal R, Srinivas R, Saxena AK. Trichoptysis Due to an Intrapulmonary Teratoma. *Respir CARE.* 2007;52:3.

* Corresponding author.

E-mail address: Saurabh.kgmu@yahoo.co.in (S. Mittal).