

Hasta el momento, la técnica utilizada para la toma de muestras de estas lesiones es la punción-aspiración con aguja fina (PAAF) guiada por ecografía, o la cirugía en caso de inaccesibilidad. No obstante, en los últimos años, se han descrito casos donde la PATB-USEB se ha convertido en una buena alternativa para el diagnóstico citohistológico mínimamente invasivo para aquellas lesiones no accesibles o en pacientes con un elevado riesgo quirúrgico. Los resultados son prometedores e incluso en un futuro la PATB-USEB podría llegar a ser la técnica diagnóstica de elección¹¹⁻¹⁴.

Bibliografía

- Darling GE, Maziak DE, Incelet RI, Gulenchyn KY, Driedger AA, Ung YC, et al. Positron emission tomography-computed tomography compared with invasive mediastinal staging in non-small cell lung cancer: Results of mediastinal staging in the early lung positron emission tomography trial. *J Thorac Oncol*. 2011;6:1367–72.
- Katz SC, Shaha A. PET-associated incidental neoplasms of the thyroid. *J Am Coll Surg*. 2008;207:259–64.
- Casal RF, Phan MN, Keshava K, Garcia JM, Grosu H, Lazarus DR, et al. The use of endobronchial ultrasound-guided transbronchial needle aspiration in the diagnosis of thyroid lesions. *BMC Endocr Disord*. 2014;14:88.
- Barrio M, Czernin J, Yeh MW, Palma Diaz MF, Gupta P, Allen-Auerbach M, et al. The incidence of thyroid cancer in focal hypermetabolic thyroid lesions: An 18F-FDG PET/CT study in more than 6000 patients. *Nucl Med Commun*. 2016;37:1290–6.
- Haugen BR, Alexander EK, Bible KC, Doherty GM, Mandel SJ, Nikiforov YE, et al. 2015 American Thyroid Association Management guidelines for adult patients with thyroid nodules and differentiated thyroid cancer: The American Thyroid Association Guidelines Task Force on Thyroid Nodules and Differentiated Thyroid Cancer. *Thyroid*. 2016;26:1–133.
- Navani N, Nankivell M, Lawrence DR, Lock S, Makker H, Baldwin DR, et al. Lung cancer diagnosis and staging with endobronchial ultrasound-guided transbronchial needle aspiration compared with conventional approaches: An open-label, pragmatic, randomised controlled trial. *Lancet Respir Med*. 2015;3:282–9.
- Thiryayi SA, Rana DN, Narine N, Najib M, Bailey S. Establishment of an endobronchial ultrasound-guided transbronchial fine needle aspiration service with rapid on-site evaluation: 2 years experience of a single UK centre. *Cytopathology*. 2016;27:335–43.
- Kumar A, Mohan A, Dhillon SS, Harris K. Substernal thyroid biopsy using endobronchial ultrasound-guided transbronchial needle aspiration. *J Vis Exp*. 2014:1–9.

- Chow A, Oki M, Saka H, Moritani S, Usami N. Metastatic mediastinal lymph node from an unidentified primary papillary thyroid carcinoma diagnosed by endobronchial ultrasound-guided transbronchial needle aspiration. *Intern Med*. 2009;48:1293–6.
- Sánchez-Font A, Peralta S, Curull V. Diagnóstico de quiste tiroideo mediante ultrasonografía endobronquial sectorial con punción-aspiración en un paciente con cáncer de pulmón. *Arch Bronconeumol*. 2012;49:38–9.
- Steinfurt DP, Irving LB. Endobronchial ultrasound staging of thyroid lesion in small cell lung carcinoma. *Thorac Cardiovasc Surg*. 2010;58:128–9.
- Chalhoub M, Harris K. Endobronchial ultrasonography with transbronchial needle aspiration to sample a solitary substernal thyroid nodule: A new approach. *Hear Lung Circ*. 2012;21:761–2.
- Li P, Zheng W, Liu H, Zhang Z, Zhao L. Endobronchial ultrasound-guided transbronchial needle aspiration for thyroid cyst therapy: A case report. *Exp Ther Med*. 2017;13:1944–7.
- Filippi N, Prisciandaro E, Guarize J, Donghi SM, Sedda G, Spaggiari L. One-shot diagnosis: EBUS-TBNA as a single procedure for thyroid, pulmonary and lymph nodal lesions. *Adv Respir Med*. 2019;87:194–5.

Salomé Bellido-Calduch^a, Clara Martín-Ontiyuelo^{a,b},
Lara Pijuan^c, Jaume Puig de Dou^d, Marina Suárez-Piñera^e,
Víctor Curull^{a,b} y Albert Sánchez-Font^{a,b,*}

^a Servei de Pneumologia, Hospital del Mar-Parc de Salut Mar, UAB, CIBERES, ISCIII, Barcelona, España

^b IMIM, Hospital del Mar Medical Research Institute, Barcelona, España

^c Servei d'Anatomia Patològica, Hospital del Mar-Parc de Salut Mar, Barcelona, España

^d Servei d'Endocrinologia i Nutrició, Hospital del Mar-Parc de Salut Mar, Barcelona, España

^e Servei de Medicina Nuclear i Diagnòstic per Imatge, Hospital del Mar-Parc de Salut Mar, Barcelona, España

* Autor para correspondencia.

Correo electrónico: asanchezf@parcdesalutmar.cat
(A. Sánchez-Font).

<https://doi.org/10.1016/j.arbres.2019.11.005>

0300-2896/ © 2020 Published by Elsevier España, S.L.U. on behalf of SEPAR.

Sarcoidosis Presenting With Multiple Bone Lesions and Its Regression With Infliximab



Sarcoidosis que se presenta con múltiples lesiones óseas y su regresión con infliximab

Dear Editor,

Sarcoidosis is a systemic granulomatous disorder of unknown etiology. Though pulmonary involvement is reported in the majority of sarcoidosis patients, extrapulmonary disease is seen in up to 50%. Patients may be asymptomatic, present with insidious symptoms such as malaise, fever, and dyspnea or organ-specific involvement (most commonly skin, eye, liver, heart and osteoarticular system).¹ It is a disease described in every ethnic group with a varying incidence of female preponderance. The northern European countries and black Americans have the highest incidence (50–60 and 35.5 per 100,000 people, respectively).²

The diagnosis is established by the combination of a suggestive clinical syndrome such as the Löfgren's syndrome (arthritis, erythema nodosum and bilateral hilar lymph nodes) and radiologic findings, supported by histologic identification of noncaseating granulomas.³

Bone involvement is reported in up to 13% of sarcoidosis patients, but may be underdiagnosed as specific studies are not routinely performed. Historically, it affects more frequently appen-

dicular bones and joints of the hands and feet, but axial disease has been rarely described. Bone lesions are typically described as cystic with cortical bone involvement, although sclerotic and lytic have also been reported.⁴

In this report, the authors describe a case of systemic sarcoidosis presenting as vertebral lytic fracture and discuss clinical, diagnosis and therapeutic approaches, namely the importance of biological therapy in refractory cases.

A 59-year-old healthy female was admitted for investigation of a lumbar fracture (L2) after a low energy trauma. She presented with one year of gradually worsening generalized bone pain, fatigue, and mild dyspnea. She was a non-smoker and had no previous infections, environmental exposure or significant travel history. No significant family history was determined. Apart from lower back non-radiating pain, physical examination was unremarkable, with no skin lesions or palpable lymph nodes.

Laboratory testing showed mild hypocalcemia of 8.4 mg/dL, erythrocyte sedimentation rate of 34 mm/h and gamma monoclonal band on serum protein electrophoresis (19.8 g/dL). Computed tomography (CT) scan of the lumbar spine revealed L2 fracture and L3, S2 and S3 lytic lesions.

Etiological investigation was initiated with a CT scan that further revealed multiple lytic lesions of the skull (Fig. 1C), sternum, ribs, hip bone and cervical and thoracic vertebrae, associated with cervical, mediastinal, hilar, abdominal and pelvic lymph nodes (<2 cm) as well as nodular infiltration of the lungs and liver (<1 cm).

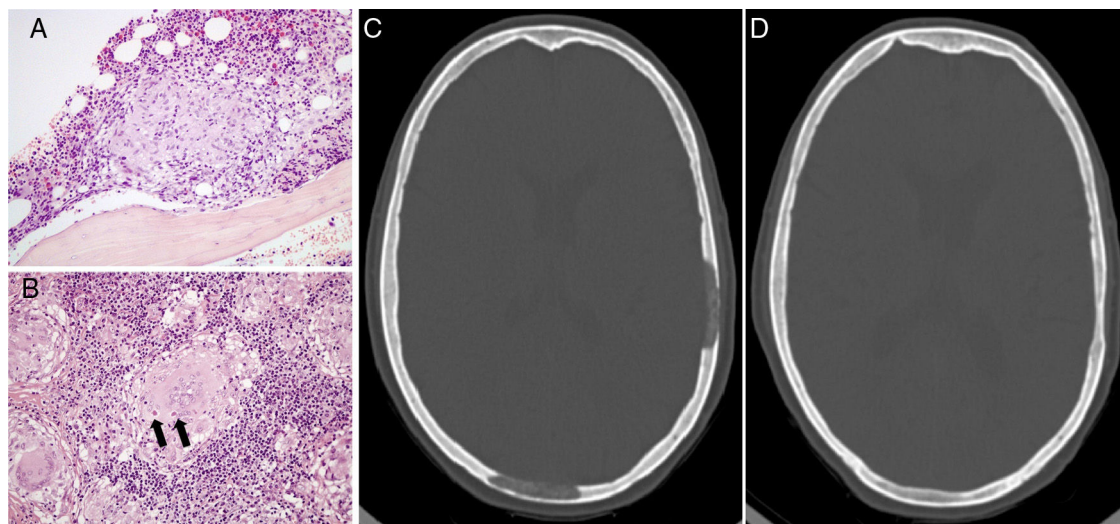


Fig. 1. (A) An epithelioid granuloma is observable next to a bone trabecula of the iliac crest, amidst the hematopoietic medullary tissue. (B) A multinucleated giant cell is shown (granuloma) in the tonsil tissue, with two dense concretions suggestive of Schaumann bodies within its cytoplasm. (C) Lytic lesions of the skull before treatment. (D) Total regression of the lytic lesions after treatment with Infliximab.

Neoplastic etiology was excluded after colonoscopy, endoscopy, mammogram, thyroid ultrasound and complete gynecological and dermatological evaluation. Biopsies of cervical lymph nodes, nasopharyngeal airway, tonsils and hip bone showed chronic inflammatory tissue with granulomas (Fig. 1A), some of which with caseum. There were remnants of an asteroid body and a multinucleated giant cell with two dense concretions suggestive of Schaumann bodies within its cytoplasm in the tonsil tissue (Fig. 1B).

Blood cultures, infectious and autoimmune serologies excluded other causes of systemic granulomatous disease. Bronchoalveolar lavage (BAL) revealed high lymphocytes (19%) in cellular analysis with technically indeterminate CD4/CD8 ratio. The diagnosis of tuberculosis suggested by caseating granulomas was refuted by negative Interferon Gamma Release Assay and mycobacterial and microbiological cultures of the BAL. The final diagnosis came to be sarcoidosis with important bone and lymph node involvement.

Her respiratory function tests were normal and her six-minute walk test was unremarkable, apart from the initial and final modified dyspnea Borg scale (1 very slight and 2 slight, respectively).

Treatment was started with 40 mg of prednisone and, after 5 months of treatment, there were no clinical or radiological improvements. It was then associated methotrexate 15 mg weekly and after 3 months the patient showed better physical tolerance and less generalized bone pain. In spite of clinical improvement, she was proposed to start treatment with Infliximab due to the growth of the lytic bone lesions combined with rising of angiotensin-converting enzyme value (58–92 U/L). After 11 months of biological therapy, the patient became asymptomatic and had regression of most lytic bone lesions (Fig. 1D), mediastinal lymph nodes and lung nodules. She maintains treatment with increasing radiological improvements and no adverse reactions were recorded.

Involvement of vertebrae and skull in sarcoidosis has been rarely reported and vertebral fracture after a low energy trauma was never described as the first manifestation of sarcoidosis.

The rarity of axial involvement may be explained by the fact that bone sarcoidosis is usually asymptomatic. Its diagnosis may be suggested by radiologic techniques such as magnetic resonance imaging (MRI) and positron emission tomography/computed tomography (PET/CT), which may not be easily available. Furthermore, these studies still lack specificity in distinguishing sarcoidosis from other diagnosis, mainly metastatic disease.⁵ In

our patient, the generalized lymph nodes and lytic bone lesions demanded, therefore, histological confirmation.

Sarcoidosis is frequently a chronic disease with multiple available treatments yet steroids are still the main treatment. In severe cases, the use of cytotoxic agents has been shown to be beneficial, such as methotrexate, azathioprine, cyclophosphamide and hydroxychloroquine.

It has been described that patients with bone sarcoidosis are frequently associated with multi-organ disease and poor prognosis, usually with decreased response to steroid treatment, as seen in our patient.⁶

In recent studies, there has been an increase in evidence of the efficacy of tumor necrosis factor (TNF)- α antagonists in the treatment of patients with pulmonary and extrapulmonary sarcoidosis, such as Infliximab and Adalimumab. They stop granulomatous inflammation, by acting against the macrophages of patients with sarcoidosis that release TNF- α , which is believed to be involved in the development of granulomas. The use of TNF- α antagonists is important by allowing the reduction of steroid effective dose, its cumulative toxicity and side-effects. They have also been proven to be effective in refractory cases, that are associated with higher levels of TNF- α in BAL.⁷

In our patient, the use of Infliximab was essential in clinical and organ involvement improvement, mainly the axial bone lesions, such as the skull and vertebrae, validating its efficacy in severe refractory cases.

Acknowledgements

We would like to express our sincere gratitude to Dr. Rita Luís for her help in the interpretation of the histological images.

Bibliografía

1. Baughman RP, Teirstein AS, Judson MA, Rossman MD, Yeager H Jr, Bresnitz EA, et al. Clinical characteristics of patients in a case control study of sarcoidosis. *Am J Respir Crit Care Med.* 2001;164 Pt 1:1885–9.
2. Rybicki BA, Major M, Popovich J Jr, Maliangk MJ, Iannuzzi MC. Racial differences in sarcoidosis incidence: a 5-year study in a health maintenance organization. *Am J Epidemiol.* 1997;145:234–41.
3. Iannuzzi MC, Rybicki BA, Teirstein AS. Sarcoidosis. *N Engl J Med.* 2007;357:2153–65.
4. Bargagli E, Prasse A. Sarcoidosis: a review for the internist. *Intern Emerg Med.* 2018;13:325–31.

5. Zhou Y, Lower EE, Li H, Farhey Y, Baughman RP. Clinical characteristics of patients with bone sarcoidosis. *Semin Arthritis Rheum*. 2017;143–8.
6. Fernández-Ruiz M, Guerra-Vales JM, Castelbón-Fernández FJ, Llenas-García J, Rodríguez-Peralto JL, López-Lancho R, et al. Sarcoidosis presenting as an osteolytic skull lesion: a case report and review of literature on skull sarcoidosis. *Clin Rheumatol*. 2007;1745–8.
7. Judson MA, Baughman RP, Costabel U, Flavin S, Lo KH, Kavuru MS, et al. Efficacy of infliximab in extrapulmonary sarcoidosis: results from a randomised trial. *Eur Respir J*. 2008;1189–96.

Andrea Lopes Machado^{a,*}, Nuno Jacinto^b, Dúlio Teixeira Passos^b, Leonardo Ferreira^a

^a Serviço de Pneumologia – Departamento do Tórax do Centro Hospitalar Universitário Lisboa Norte, Lisboa, Portugal
^b Serviço de Medicina 2, Hospital de Santa Maria – Centro Hospitalar Universitário Lisboa Norte, Lisboa, Portugal

* Corresponding author.

E-mail address: astl.machado@gmail.com (A. Lopes Machado).

<https://doi.org/10.1016/j.arbres.2019.11.022>

0300-2896/© 2020 Published by Elsevier España, S.L.U. on behalf of SEPAR.

***Mycobacterium peregrinum*: micobacteria atípica e infrecuente. Reporte de un caso**



***Mycobacterium peregrinum*: An Atypical and Uncommon *Mycobacterium*. A Case Report**

Estimado Director:

Las micobacterias no tuberculosas (MNT), también llamadas atípicas o ambientales, se encuentran ampliamente distribuidas en el agua y el suelo¹, pero su potencial patogénico fue subestimado durante mucho tiempo.

Con la pandemia VIH/sida y la mayor sobrevida alcanzada por pacientes con enfermedades respiratorias crónicas y otras enfermedades debilitantes, como neoplasias, diabetes, enfermedades autoinmunes, trasplantes y tratamientos inmunosupresores, las MNT han ganado interés y existe un creciente número de casos y nuevas especies reconocidas^{1,2}.

Entre las MNT *Mycobacterium peregrinum* es una especie de presentación infrecuente, con muy pocos casos reportados a nivel mundial, por lo que su significado clínico y el tratamiento óptimo no están bien establecidos³.

En este contexto, el reporte de casos es de gran valor para ampliar el conocimiento del tema.

Presentamos el caso de una mujer de 40 años que asistió a la consulta de neumología por presentar tos con escasa expectoración mucosa de 2 meses de evolución, sin otros síntomas asociados. Había recibido tratamiento empírico con amoxicilina y, dada la persistencia de la tos, se había indicado salbutamol sin obtener mejoría.

Como antecedentes de interés presentaba uveítis autoinmune, por lo que recibía micofenolato 2 g/día desde 3 años previos a la consulta, y se su profesión era la de técnica extraccionista en el laboratorio de nuestro hospital.

En el examen físico no se evidenciaron hallazgos relevantes.

Entre los estudios complementarios realizados se menciona: hematocrito 32%, hemoglobina 9,9 g/dl, discreta anisocromía con hipocromía. Recuento leucocitario 10.670/mm³ (neutrófilos 64%, linfocitos 22%, monocitos 11%, eosinófilos 2%, basófilos 0,5%), eritrosedimentación 54 mm/h; hepatograma, función renal, glucemia y proteinograma con valores dentro de los límites de referencia. Prueba cutánea de la tuberculina: 2 mm.

La espirometría mostraba valores normales (FVC 4,05 l [122% del teórico], FEV₁ 3,27 l [119% del teórico], FEV₁/FVC 81%), sin respuesta significativa a los broncodilatadores.

La tomografía simple de tórax evidenció un infiltrado hiperdenso con bronquiectasias en el segmento posterior del lóbulo inferior izquierdo (fig. 1).

Ante la sospecha de enfermedad infecciosa se solicitó baciloscopia de esputo que resultó positiva, con desarrollo en el cultivo de *M. peregrinum* (en 2 muestras de esputo distintas), identificado por el método molecular de análisis de los productos de restricción de amplicones de 439 pb del gen hsp65, amplificados por PCR. La sensibilidad a claritromicina, ciprofloxacino, amikacina y linezolid, fue demostrada por la prueba de determinación de la concentración inhibitoria mínima por el método de microdilución, de acuerdo a las normas CLSI.

Tras verificar una función auditiva y electrocardiograma normales se inició tratamiento con ciprofloxacino 500 mg/12 horas y claritromicina 500 mg/12 horas. A los 30 días de iniciar los antibióticos había cedido la tos y la expectoración, por lo que no fue posible obtener nuevas muestras de esputo para su examen microbiológico, y había normalizado el hemograma y la eritrosedimentación.

Tras 6 meses de tratamiento con buena tolerancia y sin eventos adversos significativos, se repitió la tomografía de tórax, que resultó normal, y se le otorgó el alta.

Las MNT se clasifican según sus características de crecimiento y los pigmentos que elaboran⁴. En el grupo de crecimiento lento (más de 7 días) se destacan *M. kansasii* y *M. avium complex*, y dentro de las de crecimiento rápido se encuentran *M. fortuitum*, *M. chelonae* y *M. abscessus*.

Estas especies presentan gran variabilidad en su distribución geográfica, su potencial patológico y su presentación, incluso dentro de una misma región^{1,4,5}. La gran mayoría de las enfermedades clínicamente detectables se debe a micobacterias de crecimiento lento (alrededor del 82% de los casos), siendo mucho menos frecuente el reporte de infecciones por micobacterias de crecimiento rápido.

M. peregrinum se ubica entre de las de rápido crecimiento, dentro del grupo *Mycobacterium fortuitum*, en el que se encuentran *M. fortuitum* (la más común de estas, conocida por causar infecciones oportunistas), y otras 8 especies que comparten características como ausencia de pigmentación y susceptibilidad a polimixina B, sulfonamidas y nuevas fluoroquinolonas^{3,6}.

En un estudio ambiental realizado en distintas fuentes de agua en Bahía Blanca, Buenos Aires, Argentina, se aislaron MNT en el 51,6% de las muestras de agua de dique y de grifo (64/124), de las cuales el 11% correspondía a *M. peregrinum*⁷.

Más allá de su amplia distribución, *M. peregrinum* es muy raro como patógeno para los humanos⁸ y se estima que representan del 1% a 2% de las infecciones por micobacterias de crecimiento rápido³. La prevalencia de las infecciones respiratorias por este germen se desconoce.