

Bibliografía

1. World Health Organization. Vaccines against influenza WHO position paper – November 2012. Wkly Epidemiol Rec. 2012;87:461–76.
2. World Health Organization. Pneumococcal vaccines WHO position paper—2012. Wkly Epidemiol Rec. 2012;87:129–44.
3. European Centre for Disease Prevention and Control. Invasive pneumococcal disease. In: ECDC. Annual epidemiological report for 2016. Stockholm: ECDC; 2018.
4. Tomczyk S, Bennett NM, Stoecker C, Gierke R, Moore MR, Whitney CG, et al., Centers for Disease Control and Prevention (CDC). Use of 13-valent pneumococcal conjugate vaccine and 23-valent pneumococcal polysaccharide vaccine among adults aged ≥ 65 years: recommendations of the Advisory Committee on Immunization Practices (ACIP). MMWR Morb Mortal Wkly Rep. 2014;63:822–5.
5. European Centre for Disease Prevention and Control. Seasonal influenza vaccination in Europe. Vaccination recommendations and coverage rates in the EU Member States for eight influenza seasons: 2007–2008 to 2014–2015. Stockholm: ECDC; 2017.

Rebeca Martins Natal^{a,*}, Luís Vaz Rodrigues^{a,b}

^a Sousa Martins Hospital, Local Health Unit, Guarda, Portugal

^b Faculty of Health Sciences, University of Beira Interior, Covilhã, Portugal

* Corresponding author.

E-mail address: rebecanatal@gmail.com (R. Martins Natal).

<https://doi.org/10.1016/j.arbres.2018.11.018>
0300-2896/

© 2018 SEPAR. Published by Elsevier España, S.L.U. All rights reserved.

Acute Respiratory Distress Syndrome Secondary to Histoplasmosis-induced Hemophagocytic Lymphohistiocytosis



Síndrome de distrés respiratorio agudo secundario a linfohistiocitosis hemofagocítica inducida por histoplasmosis

Dear Editor:

Acute respiratory distress syndrome (ARDS) is a condition that carries high mortality and can be caused by sepsis or pneumonia.¹ Histoplasmosis can cause a lung infection varying from mild pneumonitis to ARDS.² This endemic mycosis can also cause disseminated infection and is catastrophic in immunocompromised patients.³ In transplant populations, it has an incidence of 1–3 cases per 1000 patients and is more prevalent in hepatic and renal transplants.^{4–6} Hemophagocytic lymphohistiocytosis (HLH) is characterized by immune derangement of defective natural killer cells and macrophage overactivation. HLH is a rare complication of histoplasmosis but carries a mortality of up to 50%. Optimal treatment of infection-associated HLH is controversial and data is limited.^{7,8} Some physicians advocate for the use immunosuppression in addition to antifungal therapy, whereas others will only treat the underlying infection. Notably, current evidence suggests that this latter approach has less mortality.^{3,9–11}

We present a case of a 46-year-old Korean male who underwent a deceased donor kidney transplant in 2014 secondary to diabetic nephropathy. He presented with vomiting, diarrhea and fever and was initially treated for viral gastroenteritis. Chest X-ray (CXR) on admission showed bibasilar linear infiltrates (Fig. 1A). His clinical status rapidly deteriorated and he was admitted to the intensive care unit and was started on low-dose vasopressors. Patient's hemodynamics continued to worsen with respiratory failure requiring high-flow nasal cannula due to hypoxemia. He rapidly developed ARDS and required intubation with low-tidal volume ventilation and paralytics. Chest X-ray revealed diffuse bilateral alveolar infiltrates with air bronchogram (Fig. 1B) and chest computed tomography revealed tree-in-bud infiltrates and splenomegaly. Laboratory data was notable for pancytopenia, transaminitis, ferritin of 16,624 ng/mL, elevated LDH, normal triglycerides and a positive urine and serum *Histoplasma* antigen. He had several environmental and animal exposures including bats, rats, animal droppings and mold along subway tunnels. Work-up including acid-fast Bacilli smear and culture, hepatitis panel, *Bartonella*, *Human Immunodeficiency Virus (HIV)*, *Legionella*, *Cryptococcus*, *Parvovirus*, *Human Herpes Virus 6*, *Adenovirus*, *Epstein-barr Virus* and *Cytomegalovirus* polymerase chain reaction tests were negative. Bronchoalveolar lavage revealed numerous fungal organisms

in the form of budding yeasts without evidence of pseudohyphae, consistent with *Histoplasma Capsulatum*. Culture data confirmed the diagnosis. The patient rapidly improved and was successfully extubated after starting amphotericin B, followed by itraconazole. Soluble IL-2 receptor came back elevated (14,150 pg/mL) a few days later. Tacrolimus and mofetil mycophenolate had been initially stopped due to worsening renal function but were restarted before discharge. The patient was fully recovered at 6-month follow up.

This case highlights that patients with significant immunosuppression can develop severe ARDS secondary to histoplasmosis.² This has mainly been described in patients with HIV who can also develop HLH as a rare complication.³ The current treatment of primary HLH is based on immunosuppression¹² but there is not consensus on the treatment of infection-associated HLH.⁸ Moreover, the literature in organ transplants patients is limited. One study reported less mortality in patients who do not receive additional immunosuppression, although only a small number of patients were included in that study.³ Our patient met five criteria for HLH, including fever, splenomegaly, pancytopenia, high ferritin level and elevated IL2 soluble receptor. He had an excellent response to treatment targeting histoplasmosis without the use of steroids or further immunosuppression. In the largest case series of 11 cases of patients with histoplasmosis-induced HLH, the mortality was 46% at 30 days and 63% at 90 days, with increased mortality up to 80% in the group who received immunosuppression.³ The study included nine patients with HIV and two with renal transplants.³ Further evidence of HLH and histoplasmosis in kidney transplant is scarce. Nieto et al. report two cases, one successfully treated with antifungals alone and one with a fatal outcome after receiving increased immunosuppression.⁹ Similarly, Contreras et al. report a renal transplant patient who successfully responded to antifungal therapy alone.¹⁰ Lo et al. describe a successful experience of two kidney transplant patients who received only dual antifungal therapy with amphotericin and itraconazole.¹¹ Notably, there were no acute rejections in spite of decreased immunosuppression. Therefore, it should be highlighted that limiting immunosuppression may be necessary if patients are refractory to antifungal therapy to ensure complete resolution of Histoplasmosis infection. In our patient, we held immunosuppression on admission and he did not experience any complications. Limitations related to the small number of patients and the possibility of treatment bias in patients who were sicker should be considered. Prospective treatment studies would be ideal, but they are unlikely given the rarity of this disease. In conclusion, our case adds to the limited literature that suggests that treatment of an underlying infection in HLH alone could lead to rapid resolution of this otherwise lethal disorder. Further data is needed to define the role of immunosuppression in treating this condition.

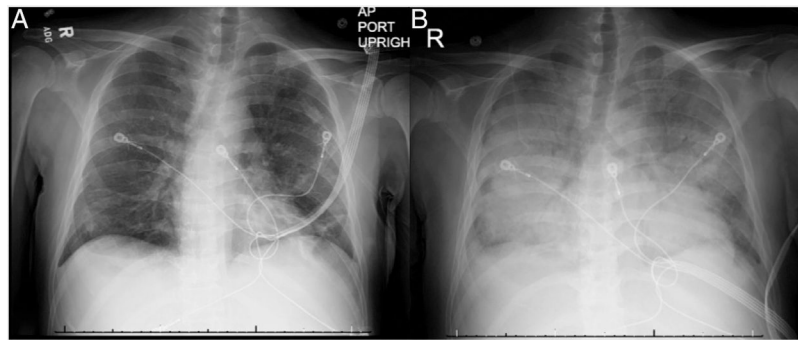


Fig. 1. Chest X-ray on admission and at 12-h follow-up. (A) Bibasilar linear infiltrates seen on admission. (B) Diffuse bilateral alveolar infiltrates with air bronchogram seen 12 h after admission.

Bibliografía

- Thompson BT, Chambers RC, Liu KD. Acute respiratory distress syndrome. *N. Engl. J. Med.* 2017;377:562–72.
- Kauffman CA. Histoplasmosis: a clinical and laboratory update. *Clin. Microbiol. Rev.* 2007;20:115–32.
- Townsend JL, Shanbhag S, Hancock J, Bowman K, Nijhawan AE. Histoplasmosis-induced hemophagocytic syndrome: a case series and review of the literature. *Open Forum Infect Dis.* 2015;2.
- Cuellar-Rodríguez J, Avery RK, Lard M, Budev M, Gordon SM, Shrestha NK, et al. Histoplasmosis in solid organ transplant recipients: 10 years of experience at a large transplant center in an endemic area. *Clin. Infect. Dis.* 2009;49:710–6.
- Freifeld AG, Wheat LJ, Kaul DR. Histoplasmosis in solid organ transplant recipients: early diagnosis and treatment. *Curr Opin Organ Transplant.* 2009;14:601–5.
- Gajurel K, Dhakal R, Deresinski S. Diagnosis and treatment of histoplasmosis in solid organ transplant patients. *Curr Opin Infect Dis.* 2018;31:301–8.
- Untanu RV, Akbar S, Graziano S, Vajpayee N. Histoplasmosis-induced hemophagocytic lymphohistiocytosis in an adult patient: a case report and review of the literature. *Case Rep Infect Dis.* 2016;2016:5.
- Schram AM, Berliner N. How I treat hemophagocytic lymphohistiocytosis in the adult patient. *Blood.* 2015;125:2908–14.
- Nieto-Ríos JF, Aristizabal-Alzate A, Ocampo C, Serrano-Gayubo AK, Serna-Higuera LM, Zuluaga-Valencia G. Disseminated histoplasmosis and haemophagocytic syndrome in two kidney transplant patients. *Nefrología.* 2012;32:683–4.
- Contreras K, García P, Pinto J, Rodríguez P, González C, Brochero MJV. Histoplasmosis diseminada y síndrome hemofagocítico en trasplante renal. *Rev Colomb Nefrol.* 2017;4:93–8.
- Lo MM, Mo JQ, Dixon BP, Czech KA. Disseminated histoplasmosis associated with hemophagocytic lymphohistiocytosis in kidney transplant recipients. *Am. J. Transplant.* 2010;10:687–91.
- Trottestam H, Horne AC, Aricò M, Egeler RM, Filipovich AH, Gardner H, et al. Chemotherapy for hemophagocytic lymphohistiocytosis: long-term results of the HLH-94 treatment protocol. *Blood.* 2011;118:4577–84.

Julio Arturo Huapaya^{a,*}, Elizabeth Yogiaveetil^b,
Syed Qamer^a, Mary Sidawy^c, Eric Anderson^b

^a Division of Internal Medicine, Medstar Georgetown University Hospital, Washington, DC, United States

^b Division of Pulmonary and Critical Care Medicine, Medstar Georgetown University Hospital, Washington, DC, United States

^c Department of Pathology, Medstar Georgetown University Hospital, Washington, DC, United States

* Corresponding author.

E-mail address: julioarturo30@gmail.com (J.A. Huapaya).

<https://doi.org/10.1016/j.arbres.2018.12.011>
0300-2896/

© 2019 SEPAR. Published by Elsevier España, S.L.U. All rights reserved.

Social Determinants of Community-acquired Pneumonia: Differences by Age Groups



Determinantes sociales de la neumonía adquirida en la comunidad: diferencias en función de los grupos de edad

Dear Editor,

Social determinants of health are the circumstances in which people get born, grow, live, work and age. These circumstances are related with the distribution of money and resources; they determine differences in the exposure to health risk factors and in morbi-mortality.¹ Respiratory diseases such as chronic obstructive pulmonary disease have shown a strong social gradient,² but social determinants of health have not been studied in the case of community acquired pneumonia (CAP). In order to design and implement effective strategies for CAP prevention, knowledge of these risk factors would be useful and of great relevance. We aimed to assess social risk factors for pneumonia in adults and to evaluate if these risk factors are different in younger and older people from data of a large population-based, case-control study conducted in an extensive area of the eastern coast of Spain. Details of the study protocol

have been previously reported.³ All cases of CAP confirmed by new radiologic findings of pulmonary infiltrate occurring in the study population during 1 year were recruited. Patients with macro aspiration pneumonia (defined as a pneumonic episode involving loss of consciousness or a witnessed aspiration, and radiographic evidence of an infiltrate in the posterior segments of the upper lobe or the apical or basal segments of the lower lobes),⁴ active pulmonary tuberculosis, nosocomial pneumonia, and health care related pneumonia or patients infected by the HIV were excluded. Controls were randomly selected every 3 months from the list of subjects assigned to 64 primary care centres participating in the study. Controls were matched with cases by sex, age (± 5 years) and primary care centre. A questionnaire on CAP risk factors was administered by trained physicians or nurses at home. This questionnaire included standardized information related to health habits and lifestyles, clinical conditions or co-morbidities and regular treatments during the last year. Social risk factors considered included education level, civil status, overcrowding (defined as living with more than 10 persons at home), profession, and life conditions such as daily contact with children or pets at home. Odds ratio (OR) was used as a measure of the association between risk factors and the occurrence of CAP and was estimated by conditional logistic regression. Analysis was