

## Clinical Image

### “Needle Aspiration” as an Occupational Injury

#### La “aspiración con aguja” como accidente laboral

Sebastian Fernandez-Bussy<sup>a,\*</sup>, Gonzalo Labarca<sup>b,c</sup>, Erik Folch<sup>d</sup>

<sup>a</sup> Division of Pulmonary and Critical Care Medicine, Mayo Clinic, Jacksonville, FL, United States

<sup>b</sup> Facultad de Medicina, Universidad San Sebastian, Concepcion, Chile

<sup>c</sup> Complejo Asistencial Dr. Victor Rios Ruiz, Los Angeles, Chile

<sup>d</sup> Division of Pulmonary and Critical Care Medicine, Massachusetts General Hospital, Boston, United States



A 31-year old man was seen in the emergency department after reporting aspiration of a sharp object at work. He felt a mild stabbing pain, but no shortness of breath or cough.

His job consists of injecting CO<sub>2</sub> gas into impermeable packages that contain chicken. This technique of “modified atmosphere packaging” is used to prolong shelf-life over traditional ice packing and vacuum packaging. Immediately prior to the aspiration event, he recalled placing the needle in his lips and blow in an attempt to unplug it.

Physical exam and laboratory values were strictly normal. The chest-X-ray showed a radiopaque straight object in the upper trachea (Fig. 1a). Rigid bronchoscopy demonstrated a sharp metal

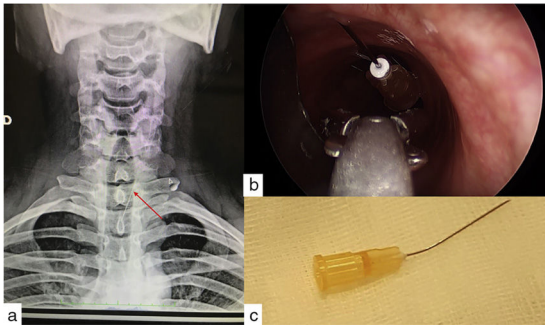
object piercing the left lateral aspect of the upper trachea, which was removed using rigid forceps through rigid bronchoscopy (Fig. 1b and Video). This foreign body was a 25-gauge needle (Fig. 1c). The patient was discharged two hours after the procedure without complications. Sharp foreign body aspiration may be considered an occupational risk for workers who use needles, nails or pins.<sup>1,2</sup> Bronchoscopy is the cornerstone of the diagnosis and treatment of foreign body aspiration, and rigid bronchoscopy is most of the times needed in order to retrieve the foreign body and reduce complications.<sup>1,3</sup>

#### Appendix A. Supplementary data

Supplementary data associated with this article can be found, in the online version, at [doi:10.1016/j.arbres.2018.08.002](https://doi.org/10.1016/j.arbres.2018.08.002)

#### References

1. Folch E, Mehta AC. Foreign body aspiration and flexible bronchoscopy. In: Wang K, Mehta AC, Turner JF, editors. Flexible bronchoscopy. Blackwell; 2012. <http://dx.doi.org/10.1002/9781444346428.ch17>
2. Holck AL, Pettersen MK, Moen MH, Sorheim O. Prolonged shelf life and reduced drip loss of chicken filets by the use of carbon dioxide emitters and modified atmosphere packaging. *J Food Protect*. 2014;77:1133–41.
3. Swanson KL, Edell ES. Tracheobronchial foreign bodies. *Chest Surg Clin N Am*. 2001 Nov;11:861–72.



**Fig. 1.** (a) Chest Rx showed a radiopaque needle foreign body. (b) Bronchoscopy showed a sharp metal object in upper airway and (c) 25 gauges needle removed after rigid bronchoscopy.

\* Corresponding author.

E-mail address: [fernandez-bussy.sebastian@mayo.edu](mailto:fernandez-bussy.sebastian@mayo.edu) (S. Fernandez-Bussy).