

Clinical Image

## Dark Airway Pigmentation in a Copper Miner

### Pigmentación oscura de la vía aérea en un minero del cobre

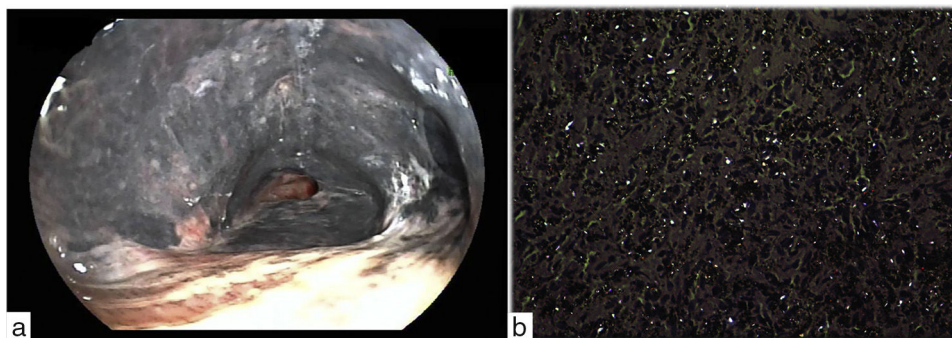
Sebastian Fernandez-Bussy<sup>a,\*</sup>, Gonzalo Labarca<sup>b,c</sup>, Adnan Majid<sup>d</sup>

<sup>a</sup> Unit of Interventional Pulmonology, Clinica Alemana – Universidad del Desarrollo, Santiago, Chile

<sup>b</sup> Department of Internal Medicine, Facultad de Medicina, Universidad San Sebastian, Concepcion, Chile

<sup>c</sup> Complejo Asistencial Dr. Victor Rios Ruiz, Los Angeles, Chile

<sup>d</sup> Division of Thoracic Surgery and Interventional Pulmonology, Beth Israel Deaconess Medical Center, Boston, United States



**Fig. 1.** (a) Flexible bronchoscopy shows extensive dark airway pigmentation with bronchial obliteration of both upper lobes. (b) Bronchial mucosa biopsy demonstrates silica crystalline material under polarized light (40 $\times$ ).

A 68-year-old man referred to pulmonary consult with a 6-month history of increase shortness of breath and dry cough. He has worked in a copper mine north of Chile for almost 40 years. On physical examination, breath sounds were reduced bilaterally along with mild crackles. Laboratory studies revealed erythrocytosis with hematocrit 54% and hemoglobin 18.5 g per deciliter (reference range, 13.5–17.5). Chest-CT scan showed mass-like lesions and bronchial narrowing in both upper lobes. Flexible bronchoscopy demonstrated mucosa dark pigmentation from both main stem bronchi and bronchus intermedius together with segmental bronchi obliteration of both upper lobes (Fig. 1A and Video). Bronchial mucosa biopsy revealed coal dust and acicular crystalline material observed under polarized light (40 $\times$ ) (Fig. 1B). Anthracofibrosis results from carbon particles deposition but other organic and inorganic substances,<sup>1,2</sup> like silica in this case,

can also cause this pigmentation.<sup>2</sup> Commonly reported radiological features includes central peribronchial soft tissue thickening, intraparenchymal peribronchial cuffing or bronchial narrowing, such our case.<sup>1</sup> Definitive diagnosis included a bronchoscopic examination that revealed a dark pigmentation in airway and biopsy samples revealed infiltration of non-specific mononuclear inflammatory cells, mostly polymorphonuclears with a normal epithelium.<sup>2</sup> Unfortunately, there is no treatment for this condition rather than avoid exposure.

#### Appendix A. Supplementary data

Supplementary data associated with this article can be found, in the online version, at [doi:10.1016/j.arbres.2018.06.015](https://doi.org/10.1016/j.arbres.2018.06.015)

#### References

1. Kakhkoue S, Pourghorban R, Bitarafan M, Najafzadeh K, Makki SS. Imaging findings of isolated bronchial anthracofibrosis: a computed tomography analysis of patients with bronchoscopic and histologic confirmation. Arch. Bronconeumol. 2015;51:322–7.
2. Jamaati H, Sharifi A, Mirenayat MS, et al. What do we know about anthracofibrosis? A literature review. Tanaffos. 2017;16:175–89.

\* Corresponding author.  
E-mail address: [sfernandezbussy@alemana.cl](mailto:sfernandezbussy@alemana.cl) (S. Fernandez-Bussy).