

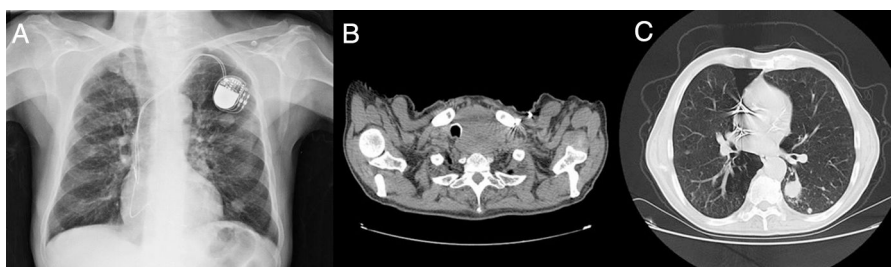
## Clinical image

# A Diagnosis Hard to Swallow

## Un diagnóstico difícil de aceptar

Dionísio Maia\*, Nídia Caires, Sara Silva

Serviço de Pneumologia – Hospital de Santa Marta, Centro Hospitalar de Lisboa Central, Portugal



**Fig. 1.** (A) Chest radiography showing right tracheal deviation. (B) Neck CT demonstrating right tracheal deviation due to thyroid enlargement. (C) Chest CT with multiple lung nodules.

We describe the case of a 72-year-old man, smoker (100 pack-year) with known history of arterial hypertension, chronic obstructive pulmonary disease and pacemaker implantation due to bradyarrhythmia. He went to the emergency room due to dysphagia, foreign body sensation in the oropharynx and progressive tiredness in the last months. On physical examination nodular enlargement of the left base of the neck was noted.

Chest radiography and computed tomography showed right tracheal deviation (Fig. 1 – panels A and B), enlarged upper mediastinum due to thyroid enlargement and several parenchymal nodules (panel C). Thyroid biopsy was compatible with metastasis of squamous cell carcinoma and transthoracic biopsy of the largest lung nodule revealed squamous cell carcinoma of the lung (immunohistochemistry positive for CK5/6 and p63; TTF-1, CK20 and thyroglobulin negative). Stage IV lung cancer was admitted and the patient was proposed palliative chemotherapy and discharged

to the Oncology Outpatient Clinic. Unfortunately the patient died shortly after the diagnosis, before starting any treatment.

The majority of patients who present with thyroid metastasis are diagnosed in the setting of known previous malignancy.<sup>1</sup> To our knowledge, this is one of the few cases reported with thyroid metastasis as an initial presentation of lung cancer.<sup>2</sup> The prognosis is poor.<sup>2</sup>

## References

1. Hegerova L, Griebeler ML, Reynolds JP, Henry MR, Gharib H. Metastasis to the thyroid gland: report of a large series from the Mayo Clinic. *Am J Clin Oncol.* 2015;38:338–42, <http://dx.doi.org/10.1097/COC.0b013e31829d1d09>
2. Namad T, Wang J, Shipley R, Karim N. Thyroid metastasis from nonsmall cell lung cancer. *Case Rep Oncol Med.* 2013, <http://dx.doi.org/10.1155/2013/208213>

\* Corresponding author.

E-mail address: [dionisio.maia@chlc.min-saude.pt](mailto:dionisio.maia@chlc.min-saude.pt) (D. Maia).