

Pedunculated Lesion at the Entrance of Left Main Bronchus Causing Dyspnea



Lesión pedunculada en la entrada del bronquio principal izquierdo causante de disnea

Dear Editor:

Hamartomas are benign tumor-like malformations which was originally described by Albrecht.¹ Hamartomas of the lung can be pulmonary or endobronchially. A 37-year-old female was admitted to our hospital with a 3-month history of progressive dyspnea. She had a 20 pack-year smoking history. Physical examination revealed decreased respiratory sounds in the left lung field. The chest X-ray showed atelectasis of the left lower lobe (Fig. 1a). Computed tomography revealed a 2 cm × 3 cm × 1.5 cm homogeneous mass, obstructing the left lower bronchus. Rigid bronchoscopy was done for diagnosis and treatment to maintain airway safety. A vegetating, pedunculated lesion covered with a normal bronchial epithelium

was observed obstructing the entrance of the left main bronchus (Fig. 1c). Distal bronchus was observed to be patent. The tumor was extracted with the snare prob and cryotherapy was applied to the base of the tumor (Fig. 1d). Postoperatively, the dyspnea subsided and the atelectasis in the left lower lobe disappeared (Fig. 1b). Pathological examination of the tumor provided a diagnosis of hamartoma (Fig. 1f). In the control bronchoscopy done 1 month later, a tumoral surface containing a cartilaginous component was observed 1 cm distally from the main carina at the posteromedial wall. Cryotherapy was applied to the base of the lesion but because of the cartilaginous component it was ineffective (Fig. 1e). The patient is on follow-up and asymptomatic. Hamartomas are the most common benign pulmonary neoplasms but of them only 10% are endobronchial.² Usually patients are at their 6th decade at the time of diagnosis and a male predominance (4 to 1) is observed.³ In case series no difference in the bronchial distribution was observed.⁴ Most endobronchial hamartomas were asymptomatic but they can also present with hemoptysis, cough or dyspnea, or with radiological findings of pneumonia, atelectasis, and

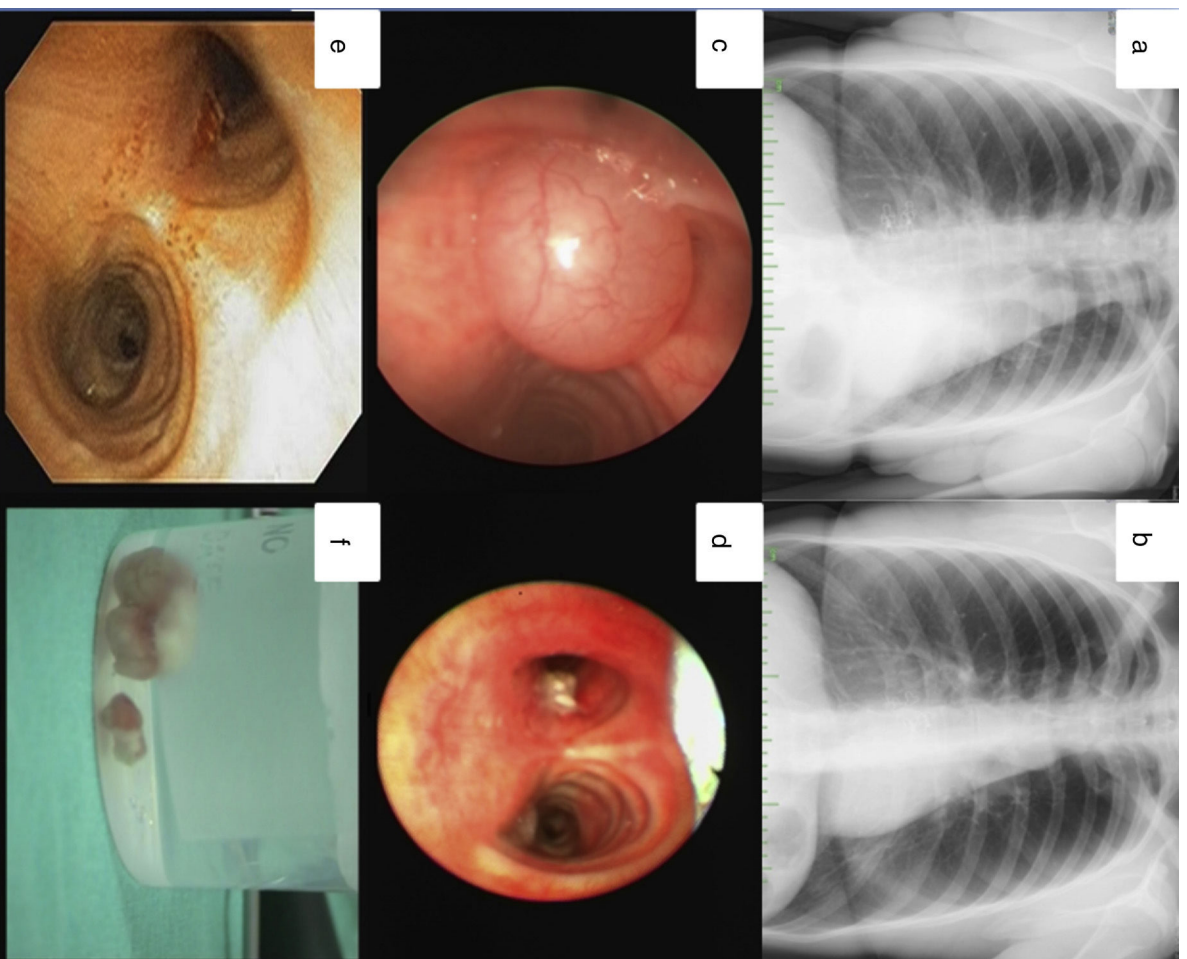


Fig. 1. Chest X-ray before (a) and after intervention (b), showing disappearance of left lower lobe atelectasis. On bronchoscopy (c), a vegetating, pedunculated lesion covered with a normal bronchial epithelium was obstructing the left main bronchus. Bronchoscopic view after resection (d) and after one month (e). Resected material (f).

intrabronchial tumor.⁴ Some endobronchial hamartomas presented with symptoms and findings of airway obstruction that resembled bronchogenic carcinoma. Like our case, most of them originated from a larger bronchi, growing into the lumen and obstructing the airway.⁴ The management of these tumors by endobronchial interventions can be diagnostic and therapeutic in a same session. Heat-based methods like laser or argon plasma coagulation are recommended for endobronchial hamartomas, especially in symptomatic patients.^{4,5} Early removal of these tumors is important before the occurrence of parenchymal findings. Therefore, bronchoscopic interventional approach for endobronchial hamartomas not only controls symptoms but also can avoid the need for thoracotomy. Surgical therapy should be reserved for cases where the hamartomas cannot be approached by endoscopy. In our case, our patient benefited from endobronchial treatment due to the location of the lesion and surgery was avoided.

Bibliografía

1. Albrecht E. Ueber hamartoma. *Verh Dtsch Ges Pathol.* 1904;7:153.
2. Suzuki N, Ohno S, Ishii Y, Kitamura S. Peripheral intrapulmonary hamartoma accompanied by a similar endotracheal lesion. *Chest.* 1994;106:1291–3.

3. Tajima H, Hayashi Y, Maehara T, Morohoshi T, Imada T, Amano T, et al. Endobronchial hamartoma treated by an Nd YAG laser. *Rep Case Jpn J Surg.* 1998;28:1078–80.
4. Cosio BG, Villena V, Echave-Sustaeta J, de Miquel E, Alfaro J, Hernandez L, et al. Endobronchial hamartoma. *Chest.* 2002;122:202–5.
5. Ucar N, Akpınar S, Aktas Z, Sipit T, Ozaydin E. Resection of endobronchial hamartoma causing recurrent hemoptysis by electrocautery and cryotherapy. *Hippokratia.* 2014;18:355–6.

Sinem Nedime Sökücü*, Cengiz Özdemir, Seda Tural Önür

Yedikule Chest Disease and Thoracic Surgery Training and Research Hospital, Istanbul, Turkey

* Corresponding author.

E-mail address: sinentimur@yahoo.com (S.N. Sökücü).

<https://doi.org/10.1016/j.arbres.2017.12.018>

0300-2896/

© 2018 SEPAR. Published by Elsevier España, S.L.U. All rights reserved.

NUT Midline Carcinoma in the Mediastinum in a Ten-Year-Old Boy



Carcinoma de la línea media NUT en el mediastino en un niño de 10 años

Dear Director:

Nuclear protein in testis (NUT) midline carcinoma (NMC) is an exceedingly rare malignant tumor with poorly epithelial differentiation which mostly affected children and young adults. It has several synonyms: t(15;19) carcinoma, aggressive t(15;19)-positive carcinoma, midline lethal carcinoma, midline carcinoma with NUT rearrangement, and BET-rearranged (bromodomain and extra-terminal) carcinoma.¹ The most common location is head and neck region, thorax, and mediastinum. The highly aggressive clinical course, unique pathological feature and exclusive genetic alteration with the rearrangement of NUT gene makes it different from other tumors. Herein, we report a case of NMC.

A ten-year-old boy presented to our hospital with the complaints of fever and coughing for more than one month. The child was diagnosed with pneumonia and administered antibiotic therapy for fifteen days in local hospital. The treatment protocol did not have any effect. CT scan revealed a giant mass measuring 10×10×8 cm with uneven density in the left superior mediastinum which was heterogeneously enhanced by iv contrast (Fig. 1A). The mass wrapped the aorta and the left pulmonary artery and vein. The left lung was compressed. Multiple bone metastases were demonstrated by the X-ray and bone scan. Radical resection was unachievable and tumor biopsy was done. Morphological examination showed nests of primitive small round cells with islands of squamous epithelium and keratinization in the center suggesting a poorly differentiated carcinoma (Fig. 1B). Obvious necrosis and the lung invasion could also be noticed in the tumor. Pan-cytokeratin, p63, and NUT diffuse positivity on immunohistochemistry (Fig. 1C–E) and the break-apart positivity of the NUT probe by FISH (Fig. 1F) confirmed the final diagnosis of NMC. The child passed away one month after biopsy for the rapid procedure and also the lack of valid treatment strategies. Written informed consent was got from the child's parent.

Midline carcinoma was first reported in 1991 with the nomenclature of carcinoma with a translocation t(15;19).² French discovered the genetic feature with the presence of NUT gene rearrangement in 2003 and designated it as NMC in 2008.^{3,4} NMC has a wide age range from infancy to 78 years according to the literatures.¹ More than one hundred cases have been reported including about 40 pediatric cases.^{4–9} Most of the pediatric cases were above ten years old and the majority of them developed metastasis at diagnosis or in a short time after diagnosis and the most common metastasis site was bone and lymph node. The main complaint was a mass in the midline area with accompanying symptoms such as dyspnea and chest pain. The nosogenesis of NMC was still unknown. BRD–NUT oncoprotein was suggested to block the epithelial differentiation and promote the growth of tumor cells and thus derived the carcinogenesis.¹⁰ NMC depends on the pathological diagnosis. Typical morphological features include nests and sheets of undifferentiated small round cells with or without focal or prominent squamous differentiation in the core of the nests and fibrous cords in the mesenchymal stroma. Pan-cytokeratin, p63 and NUT diffuse positivity is very helpful on immunohistochemistry. Fluorescence in situ hybridization (FISH) can detect the BRD–NUT fusion which confirms the diagnosis. The genetic alteration include BRD4–NUT (70%), BRD3–NUT (6%), NSD3–NUT (only 6 cases reported), NUT-variant (the rest).^{1,11} Two unusual cases of 3-way chromosome translocations had also been reported.^{5,12} Unique immunohistochemical markers and genetic translocation make the diagnosis of NMC easier. FISH and monoclonal antibody for NUT have a high sensitivity and specificity and are recommended for the diagnosis of NMC. They should be considered in every poorly differentiated carcinoma in the midline structures. The prognosis is depressing with a median survival of 6.7 months.¹³ No treatment guideline has been established and the impossible radical resection in most cases and the lack of effective anticancer drugs make the tumor refractory to the treatment. Chemotherapy does not have a good response although combination chemotherapies were observed to have objective response to NMC to some extent in few cases.⁷ Luckily, together with the progress of target therapy in tumors with specific genetic alterations, small molecular inhibitors such as BET inhibitors and histone deacetylase inhibitors have improved the outcome and