

Clinical Image

Primary Cavitory Sarcoidosis: A Diagnostic Challenge for the Clinician[☆]

Sarcoidosis cavitada primaria: una reto diagnóstico para el clínico

Muhammad Sajawal Ali^{a,*}, Farah Ciftci Olsen^b, Rose Franco^a

^a Department of Pulmonary, Critical Care and Sleep Medicine, Medical College of Wisconsin, Milwaukee, USA

^b Department of Medicine, MacNeal Hospital, Chicago, USA



A 30-year-old male presented with a 6-month history of productive cough, dyspnea, hemoptysis, night sweats and 100-pound weight loss. Physical exam and initial blood work-up were non-revealing. CT scan of the chest revealed bilateral cavities (Fig. 1, first row). Differential diagnoses included malignancy, infections and inflammatory disorders. However, bacterial and mycobacterial stains and cultures were negative. Histoplasma and Blastomyces antigens, ANA, c-ANCA, p-ANCA and HIV serologies were also negative. Bronchoscopy revealed cystic lesions communicating with the airways. Bronchoalveolar fluid cultures were negative for bacteria and fungi. Transbronchial biopsies revealed noncaseating granulomas. Diagnosis of primary cavitory sarcoidosis was established and the patient started on prednisone and methotrexate. Sustained clinical improvement was noted only after six months of treatment. Lung cavitory lesions were noted to have significantly improved at 12 months (Fig. 1, second row) and almost completely

resolved at 21 months (Fig. 1, third row). Primary cavitory sarcoidosis accounts for less than 0.6% of all sarcoidosis cases.¹ Lower lobe predominance of the lung cavities, absence of other radiographic abnormalities such as nodularity, lymphadenopathy and calcification, and the presence of severe constitutional symptoms, set our case apart from previously published reports of primary cavitory sarcoidosis.²

References

- Okada F, Ando Y, Sugisaki K, Takikawa S, Ono A, Matsumoto S, et al. Radiographic features of primary cavitory sarcoidosis with "lotus seed-like" manifestations. Clin Radiol. 2012;67:505-7, <http://dx.doi.org/10.1016/j.crad.2011.11.007>
- Hours S, Nunes H, Kambouchner M, Uzunhan Y, Brauner MW, Valeyre D, et al. Pulmonary cavitory sarcoidosis: clinico-radiologic characteristics and natural history of a rare form of sarcoidosis. Medicine (Baltimore). 2008;87:142-51, <http://dx.doi.org/10.1097/MD.0b013e3181775a73>

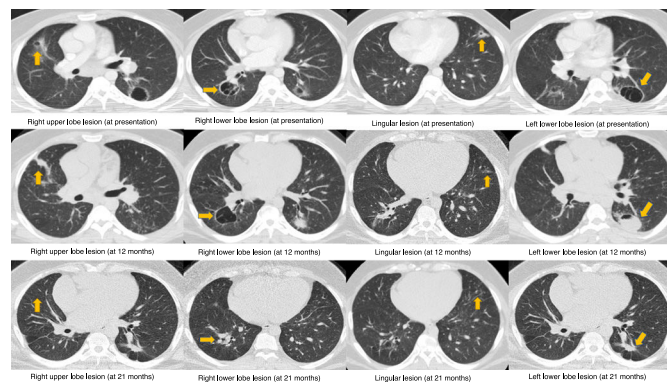


Fig. 1. CT scan images showing four representative sections at presentation (first row), 12 months (second row) and 21 months (third row). Arrows indicate the cavitory lesions in the right upper, right lower, lingula and left lower lobes (from left to right).

[☆] Previous Presentation: This case was previously presented by the authors at the annual CHEST conference, Los Angeles, 2016.

* Corresponding author.

E-mail address: muali@mcw.edu (M. Sajawal Ali).