



Clinical Image

Secondary Organizing Pneumonia Mimicking Pulmonary Metastasis of a Diffuse Large Cell Lymphoma

Neumonía organizada secundaria que imita metástasis pulmonares de un linfoma difuso de células grandes

Catarina Lacerda*, Joana Lages, Rui Rolo

Pneumology Department, Hospital de Braga, Portugal

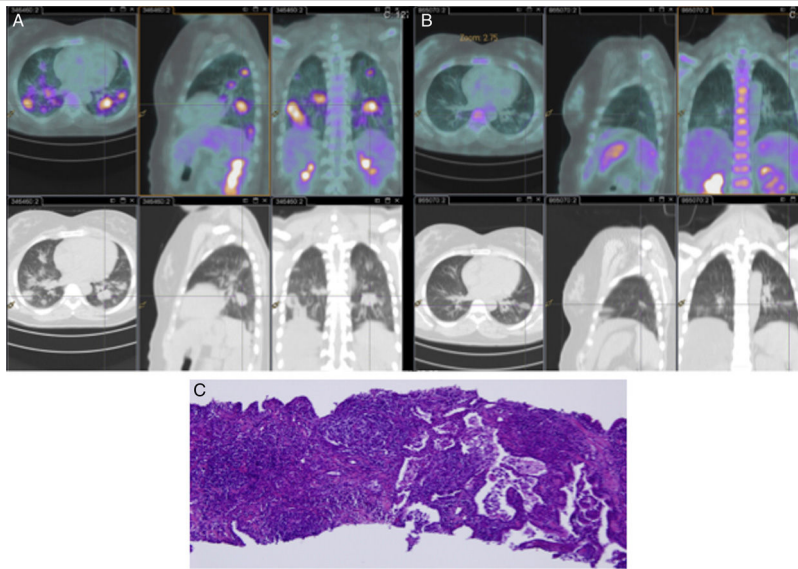


Fig. 1. (A) Diagnostic PET-CT; (B) reassessment PET-CT after treatment; (C) lung lesion histology revealing an organizing pneumonia (buds of granulation tissue in the distal air spaces and mid infiltrate of alveolar septa). H&E stain, 100× magnification.

Secondary Organizing Pneumonia (OP) due to malignancy is a condition extremely rare. We describe a case of a 36 years-old woman, who presented with right cervical lymphadenopathies and multiple nodular foci of consolidation and ground glass opacities in CT images. The cervical lymphadenopathy biopsy revealed a diffuse large B-cell lymphoma (DLBCL). PET-CT detected metabolically active lymphoid tissue in the nasopharynx, cervical right lymph nodes and lung lesions (Fig. 1A). She had no respiratory symptoms. In order to confirm the initial stage of the disease, a CT-guided transthoracic tru-cut biopsy of the pulmonary lesions was performed, which revealed an organizing pneumonia (Fig. 1C).

Patient started treatment with R-CHOP chemotherapy and, after 4 cycles, reassessment images (CT and PET-CT) showed resolution of pulmonary lesions and no lymphoproliferative disease with metabolic activity (Fig. 1B). The treatment of the underlying disease resolved the secondary OP. The patient completed treatment with involved-field radiation therapy. With this report, the authors empathize the importance of clarifying the etiology of pulmonary lesions that can mimic pulmonary metastasis and change the staging of oncologic diseases.^{1,2}

References

- Daniels CE, Myers JL, Utz JP, Markovic SN, Ryu JH. Organizing pneumonia in patients with hematologic malignancies: a steroid-responsive lesion. *Respir Med.* 2007;101:162–8.
- Drakopanagiotakis F, Paschalaki K, Abu-Hijleh M, Aswad B, Karagianidis N, Kastanakis E, et al. Cryptogenic and secondary organizing pneumonia: clinical presentation, radiographic findings, treatment response, and prognosis. *Chest.* 2011;139:893–900.

* Corresponding author.
E-mail address: catarinalacerda@hotmail.com (C. Lacerda).